

Letters to the Editor

Association of Wilson disease with neurofibromatosis

Key words: Wilson disease. Neurofibromatosis. Child.

Dear Editor,

Wilson disease is an autosomal recessive inherited disorder of hepatic copper metabolism resulting in the accumulation of copper in many organs and tissues. The defective gene is located on the long arm of chromosome 13 and codes for a transmembrane copper-transporting ATPase, ATP7B. The general incidence of the condition is 1:30,000 (1).

Type 1 neurofibromatosis (NF-1) is one of the most common genetic disorders, with dominant autosomal inheritance, with a frequency estimated at 1:3,000 liveborns (2). The defect has been mapped to chromosome 17q. Among the clinical characteristics, visceral involvement is uncommon and hepatobiliary involvement is even more unusual (3).

We present a rare case of the association of these two different genetic diseases.

Case report

A boy with no personal or familial history of disease had the diagnosis of NF-1 established since he was 2 years old. At six years of age he exhibited jaundice, choloria, fecal acholia, anorexia, fever and increased transaminase levels, reaching values of 1000 U/l; he improved in a few days. A similar episode recurred at 10 years of age. At 12 years of age he was referred to our Pedi-

atric Gastroenterology Service for investigation of liver disease. Physical examination revealed café-au-lait macules diffusely distributed on the abdomen, dorsum, axillas (about 7 lesions > 15 mm), and axillary freckling. Papules suggestive of neurofibromas on the trunk, right retroauricular region and scalp (Fig. 1D), bilateral lumbosacral tumor formations (plexiform neurofibroma) and left arm hemiparesis were observed. He did not have jaundice; liver and spleen were not palpable.

Clinical follow-up revealed fluctuating serum transaminase levels reaching a 6-fold increase and a 1.5-fold increase in gamma-GT levels. Laboratory findings: INR and albumin within normal values, viral hepatitis serology (-), SMA (-), ANA (-), AMA (-), anti-LKM1 (-), normal alpha-1-antitrypsin, serum ceruloplasmin 0.018 and 0.078 g/L (RV = 0.2-0.55), serum copper 23.6 µg%, (RV = 70-140) 24-h urinary copper 118.5 µg. Kayser-Fleischer rings were absent. Abdominal ultrasound and cholangioresonance were normal. Liver histology is shown in figure 1 A-C.

After a positive penicillamine test (24-h basal urinary Cu 229 µg; after 1072.6 µg), treatment with a copper chelating agent was started, with notable improvement of clinical condition and of serum transaminase levels. The patient is currently 20 years old, is clinically well and has no symptoms. He never manifested neurological symptoms, nor did he develop any neoplasia.

Discussion

Gastrointestinal involvement occurs in 10-25% of patients with NF-1, including intestinal infiltration by single or multiple neurofibromas, leiomyomas, and rarely plexiform neurofibromas. Regarding hepatic involvement, neurofibromas involving the liver, periportal plexiform neurofibromas and other tumors such as pheochromocytomas, hepatomas, neuroblastomas (3), and hepatoblastomas (4) have been described. The association of NF-1 with congenital hepatic fibrosis has also been reported (2). Thus, the hepatobiliary involvement occurring in patients with NF-1 in most cases is secondary to lesions that occupy space due to the pathology itself or to benign or malignant neoplasias.

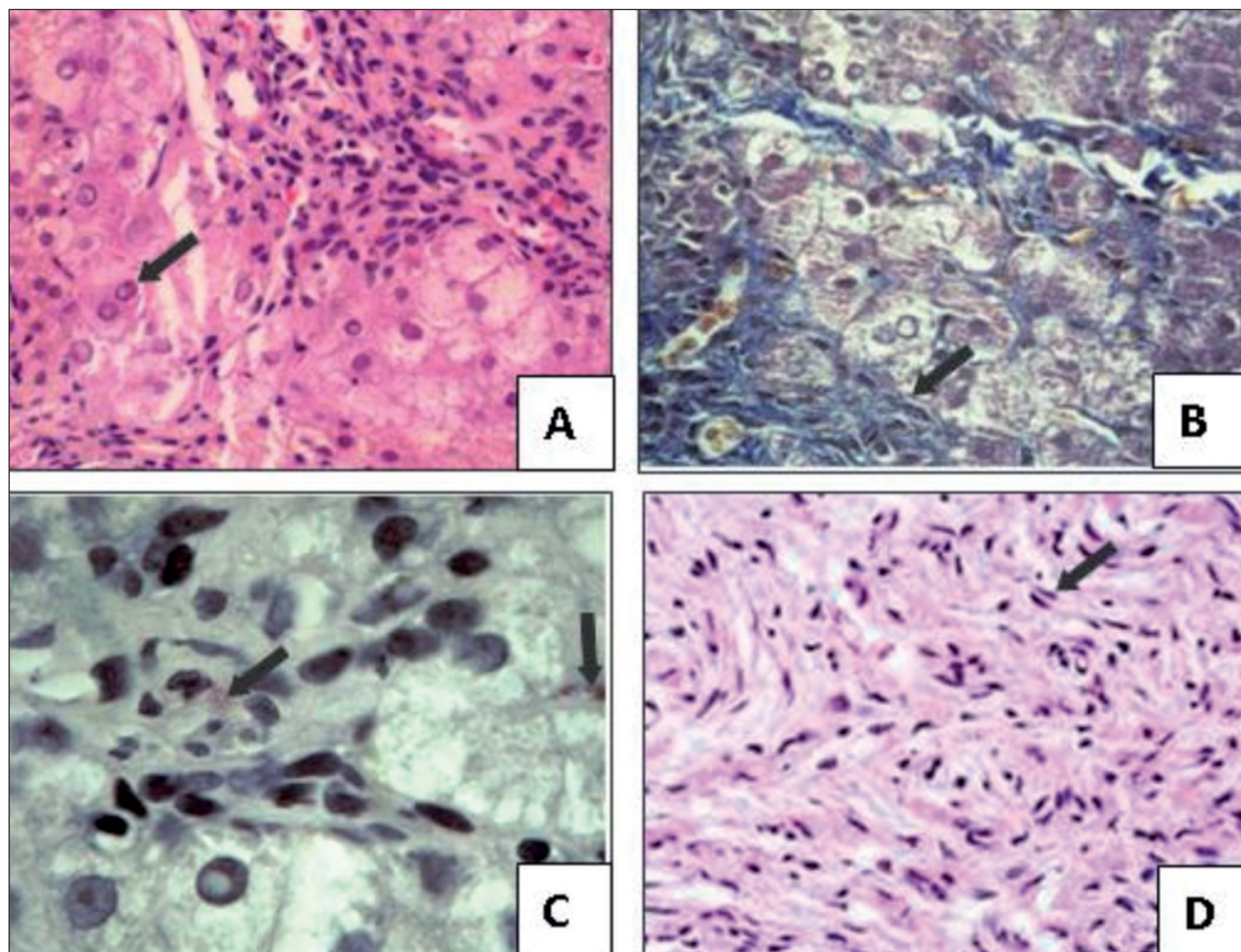


Fig. 1. A. Liver biopsy-ballooning degeneration and nuclear vacuolizations in hepatocytes (arrow) and a mononuclear infiltrate in the portal spaces (HE-400X). B. Fibrosis and interface hepatitis (arrow-Masson trichrome-200X). C. Rhodanine-positive granules in hepatocytes and Kupffer cells (arrow-rhodanine 400X). D. Neurofibroma of the scalp-proliferation of elongated, fusiform cells without atypias (arrow) arranged in bundles (HE-200X).

The occurrence of a fortuitous association of two genetic diseases can be observed in clinical practice. Since NF-1 is a very common disease, its association with other diseases or neoplasias is likely to occur coincidentally. To date, this is the second case of association between these two diseases described in the literature, the first case being a 14-year-old Iranian (5).

The two diseases share an important characteristic, i.e., they both predispose to the development of neoplasias. NF-1 leads to the development of both benign and malignant tumors. In this disease there is a mutation in the NF-1 gene that codes for neurofibrin, which acts as a tumor suppressor through the regulation of Ras-MAPK (2). In Wilson's disease, chronic inflammation and oxidative stress possibly are factors associated with increased cancer risk (6).

In conclusion, it is important for the physician to be alert to the characteristic signs and symptoms of NF-1 since several com-

plications affecting life expectancy may occur in these patients, such as association with neoplasias and coexistence with other genetic diseases. Patients with NF-1 are not expected to present changes in liver enzymes but if such changes are detected they should be appropriately investigated for an early diagnosis of liver disease. We suggest that screening for Wilson disease be also included in the investigation of liver disease in these patients.

Regina Sawamura¹, Mariângela Ottoboni-Brunaldi²,
Leandra N.Z. Ramalho², Sérgio Zucoloto²,
Marcelo Luiz-Balancin² and Maria Inez M. Fernandes¹

*Departments of ¹Pediatrics and ²Pathology.
Facultad de Medicina de Ribeirão Preto. Universidad
de São Paulo. Brazil*

References

1. Jiménez G, Cambroner V, Morales C, et al. Enfermedad de Wilson: experiencia pediátrica en Costa Rica. *Gastroenterol Hepatol* 2009; 32:274-8.
2. Jorge OA, Jorge AD. Congenital hepatic fibrosis associated with von Recklinghausen's disease. *Rev Esp Enferm Dig* 2006; 98:693-7.
3. Fenton LZ, Foreman N, Wyatt-Ashmead J. Diffuse, retroperitoneal mesenteric and intrahepatic periportal plexiform neurofibroma in a 5-year-old boy. *Pediatr Radiol* 2001;31:637-9.
4. Uçar C, Caliskan U, Toy H, Günel E. Hepatoblastoma in a child with Neurofibromatosis Type I. *Pediatr Blood Cancer* 2007;49:357-9.
5. Sahraian MA, Motamedi M, Paknejad SH, et al. Coexistence of Wilson's disease and neurofibromatosis type 1 in a 14-year-old boy. *Neurol India* 2007;55:89-90.
6. Sajankila SP, Manthena PV, Adhikari S, et al. Suppression of tumor suppressor Tsc2 and DNA repair glycosylase Nth1 during spontaneous liver tumorigenesis in Long-Evans Cinnamon rats. *Mol Cell Biochem* 2009 Dec 24.