1130-0108/2015/107/11/697-698
Revista Española de Enfermedades Digestivas

Rev Esp Enferm Dig (Madrid)
Vol. 107, N.º 11, pp. 697-698, 2015

PICTURES IN DIGESTIVE PATHOLOGY

Comb sign in intestinal obstruction secondary to desmoplastic reaction due to an ileal neuroendocrine tumor

Marcello Di-Martino, Íñigo García-Sanz, José Luis Muñoz-de-Nova, Cristina Marín-Campos and Elena Martín-Pérez

Hospital Universitario de La Princesa. Madrid, Spain

CASE REPORT

A 77-year-old man was seen in the emergency department with an intestinal obstruction in the absence of prior surgery or complicated hernias. *Abdominal computed tomography* (CT): Mesenteric nodule in distal ileum with hyperdense lineal images compatible with comb sign and proximal dilation of intestinal loops (Fig. 1 A and B). The patient underwent surgery based on the diagnosis of intestinal obstruction secondary to a mesenteric tumor, possibly related to lymphatic ducts infiltration of ileal tumor not displayed on the TC. *Surgical exploration:* Distal ileum mesenteric node congruent with the image of CT and mass in the adjacent ileum (Fig. 1C). Oncologic resection of ileal segment was performed. *Pathology report:* 3 cm size ileal neuroendocrine tumor (NET) with mesenteric infiltration. Two of seven positive lymph nodes. Well differentiated, G1 (Ki-67: 1%). *Immunohistochemical study:* Positive for chromogranin A (CgA) and synaptophysin. Post-operative uneventful. The ^{111}In-octreotide postoperative scan showed no pathological deposits. The patient has had no new episodes of intestinal obstruction or evidence of recurrence at two years after surgery.

DISCUSSION

NETs of the gastrointestinal tract are rare tumors arising from enterochromaffin cells. They are usually small asymptomatic tumors, diagnosed incidentally on imaging studies, due to metastatic spread, or to clinical symptoms of hormonal

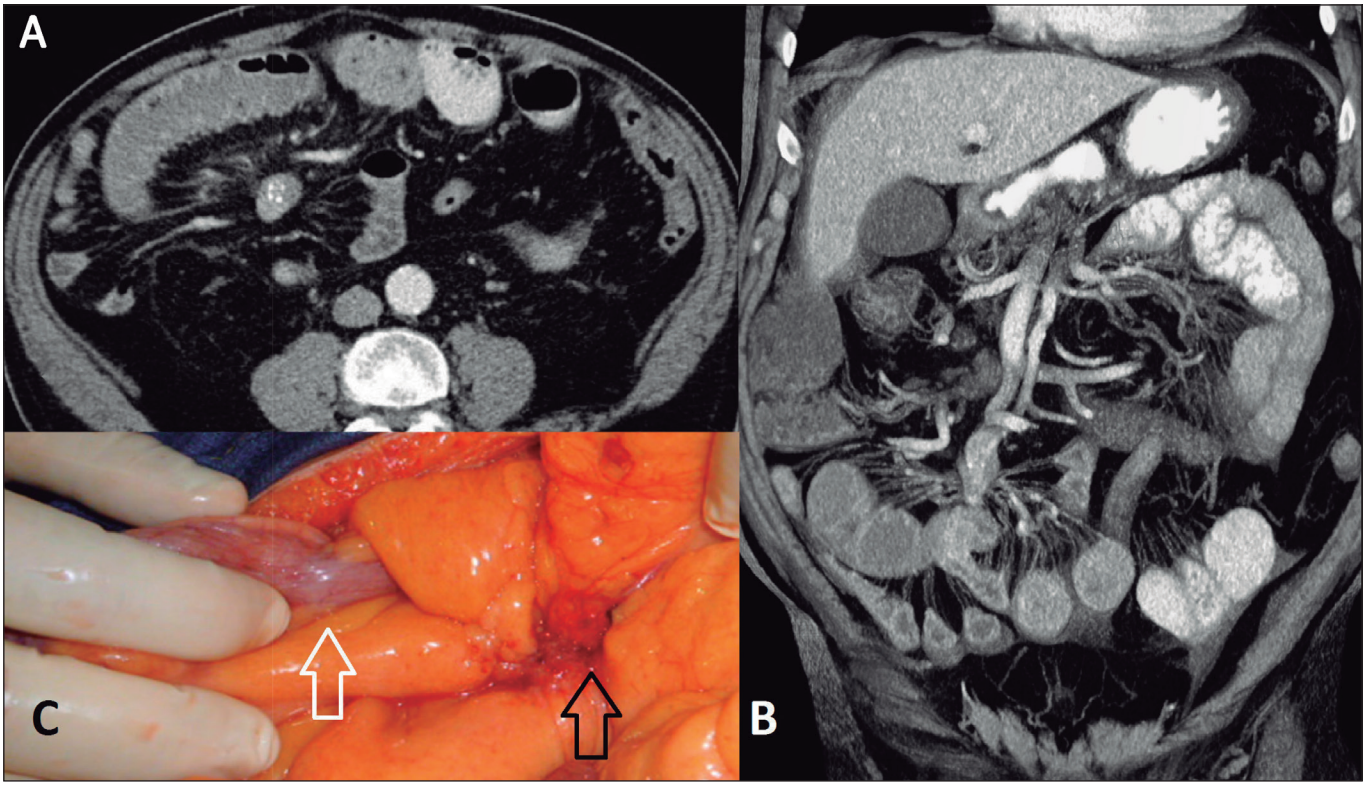

Fig. 1. A and B. Mesenteric calcified nodule 20x27 mm, with hyperdense lineal images and retraction of the affected mesentery compatible with comb sign. Dilation of proximal intestinal loops. No lesions in intestinal wall can be seen. C. Calcified metastatic mesenteric lymph node of distal ileum (black arrow) and tumor in the intestinal wall (white arrow).

hypersecretion, or to bowel obstruction (1). Carcinoid syndrome occurs in 30% of patients with distant metastases. It is secondary to the systemic release of serotonin produced in the liver, as serotonin coming from the digestive tract is degraded by the liver and does not reach systemic circulation (2,3). Intestinal obstruction is infrequent among NET, taking place only in 6-20% of cases (4-6). The pathogenesis of obstruction can be related to tumor stenosis or overproduction of serotonin by the tumor. This serotonin induces a desmoplastic reaction in the surrounding mesentery, therefore promoting intestinal obstruction. Additionally, the local fibrosis causes a decrease in local vascularization with segmental dysmotility and local ischemia, as well as shortening and angulation of affected mesentery (7). Diagnosis is established by abdominal CT scan that shows the typical comb sign, representative of the desmoplastic reaction of the mesentery. It is usual to identify metastatic lymph nodes in the absence of lesions of the bowel wall, due to the small size of the primary tumor (8-10). The definitive diagnosis is established by biopsy.

This article was presented as poster communication in the XXX Congreso Nacional de Cirugía, november 2014.

REFERENCES

1. Pape UF, Perren A, Niederle B, et al. ENETS Consensus Guidelines for the management of patients with neuroendocrine neoplasms from the jejuno-ileum and the appendix including goblet cell carcinomas. Neuroendocrinology 2012;95:135-56.
2. Oberg K, Knigge U, Kwekkeboom D, et al. Neuroendocrine gastro-entero-pancreatic tumors: ESMO Clinical Practice Guidelines for diagnosis, treatment and follow-up. Ann Oncol 2012;23(Supl. 7):vii124-30.
3. Kulke MH, Benson AB, 3rd, Bergsland E, et al. Neuroendocrine tumors. J Natl Compr Canc Netw 2012;10:724-64.
4. Rodrigues G, Prabhu R, Ravi B. Small bowel carcinoid: A rare cause of bowel obstruction. BMJ Case Rep 2013;2013. pii: bcr2013200875
5. Shatnawi NJ, Bani-Hani KE. Unusual causes of mechanical small bowel obstruction. Saudi Med J 2005;26:1546-50.
6. Allen PB, De Cruz P, Efthymiou M, et al. An interesting case of recurrent small bowel obstruction. Case Rep Gastroenterol 2009;3:408-13.
7. Marzocca G, Caputo E, Varrone F, et al. Intestinal occlusion by ileal carcinoid. Ann Ital Chir 2008;79:457-61.
8. Sheth S, Horton KM, Garland MR, et al. Mesenteric neoplasms: CT appearances of primary and secondary tumors and differential diagnosis. Radiographics 2003;23:457-73.
9. Anzidei M, Napoli A, Zini C, et al. Malignant tumours of the small intestine: A review of histopathology, multidetector CT and MRI aspects. Br J Radiol 2011;84:677-90.
10. Klimstra DS, Modlin IR, Coppola D, et al. The pathologic classification of neuroendocrine tumors: A review of nomenclature, grading, and staging systems. Pancreas 2010;39:707-12.