1130-0108/2015/107/6/390-391
Revista Española de Enfermedades Digestivas
Copyright © 2015 Arán Ediciones, S. L.
Rev Esp Enferm Dig (Madrid
Vol. 107, N.º 6, pp. 390-391, 2015

Letters to the Editor

Advances and pitfalls in the management of small bowel polyps in Peutz-Jeghers syndrome

Key words: Peutz-Jeghers syndrome. Hamartoma. Capsule endoscopy. Double-balloon enteroscopy.

Dear Editor,

The authors present a 42-year-old man with Peutz-Jeghers syndrome (PJS) diagnosed in 1993, who presented with melena and hematemesis. After endoscopic investigation, the patient was referred for surgery and intra-operative enteroscopy (IOE) to surgically remove a 6 cm gastric polyp, a 4 cm jejunal polyp and two cecal polyps of 3 cm and 7 cm. Histopathology revealed hamartomatous polyps. Genetic analysis confirmed a deletion in the STK11 gene.

The patient has been followed up with regular cancer screening and small bowel screening with capsule endoscopy (CE) every 2-3 years, since the advent of CE in our department. In our last appointment the patient presented with a 4 month history of abdominal pain, for which he had already undergone a computed tomography enterography (CTE), which was unremarkable. An additional investigation with CE revealed a large jejunal polyp only partially observed (Fig. 1). Single balloon enteroscopy revealed a 6 cm sessile polyp (Fig. 2A) in the proximal jejunum for which a piecemeal endoscopic mucosal resection was performed using a standard lift and cut technique (Fig. 2B-D).

PJS is a rare inherited autosomal dominant disorder caused by a mutation in STK11 gene, characterized by mucocutaneous pigmentation, gastrointestinal hamartomatous polyposis mainly in the small bowel and considerable predisposition to malignancy (1-4).

Resection of intestinal polyps > 10 mm is recommended to prevent small bowel obstruction, intussusception and bleeding. In the past, PJS patients were often referred for elective or emergent surgical intestinal resection. IOE was the procedure of choice until the advent of double-balloon enteroscopy (DBE) in clinical practice in 2003, substituting it in nearly all indications. DBE assisted polypectomy is successful in over 80% of hamartomatous polyposis syndromes patients without any major adverse event (2,5).

Currently, small bowel surveillance in PJS should be performed with CE every 3 years starting from age 8 years if polyps are found at the initial investigation (6). CE is a safe technique that provides an improved and detailed assessment of small bowel mucosa and has a significant role for surveillance in polyposis syndromes, such as PJS (5,7-9). Nevertheless, CE may miss up

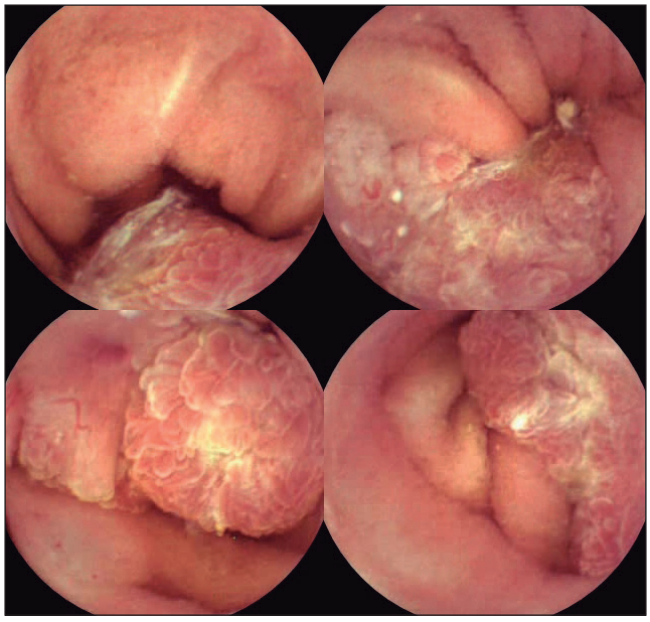

Fig. 1. Capsule endoscopy (MiroCam-IntroMedic Ltd.) frames depicting different angles of a large polyp located in the proximal jejunum.

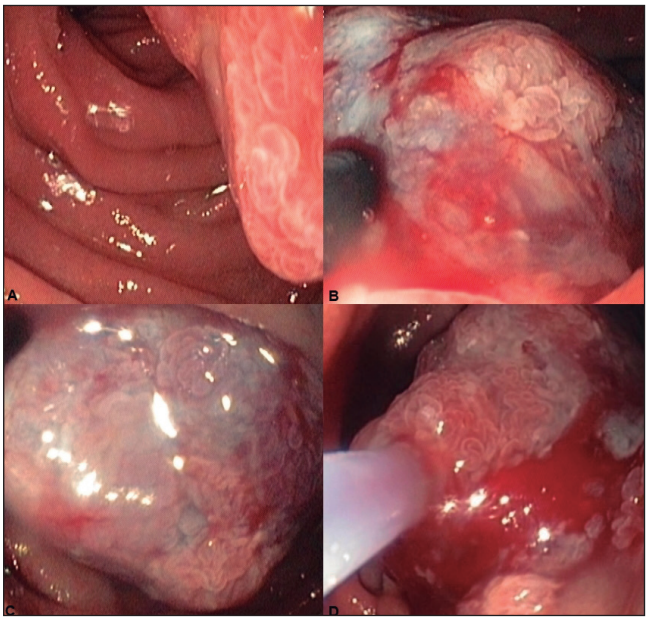

Fig. 2. Single balloon enteroscopy (Olympus SIF-Q180) images showing a sessile polyp measuring approximately 6 cm (A) in the proximal jejunum. An endoscopic mucosal resection was planned: After submucosal injection with saline and indigo carmine (B, C), a piecemeal resection of the polyp using a standard lift and cut technique was performed (D).

to 20% of polyps > 11 mm in PJS individuals and has lack of accuracy in determining the exact size and location of polyps, uncontrolled movements, unidirectional field of view and relatively slow frame rate (3,8,9).

CE has a higher diagnostic yield for polyps < 10 mm when compared to CTE and magnetic resonance image (MRI) enterography (1). For polyps > 15 mm, MRI enteroclysis is a sensitive method showing similar rates of detection when compared to CE, being more reliable in determining the exact size and location of larger polyps (1,10). CTE is not recommended as a surveillance technique due to radiation exposure (3).

There has been a remarkable improvement in screening and treatment of PJS mostly due to the development of CE and DBE (6), which is highlighted in this report. In patients with persistent symptoms, additional investigation should be pursued after negative findings in surveillance, for which the best approach is a combination of complementary endoscopic and radiological imaging techniques (1,3,8).

Ana Isabel Louro-da-Ponte, Rolando Taveira-Pinho, Maria Adélia Rodrigues, Maria Teresa Pinto-Pais, Carlos Daniel Pinho-Fernandes, Iolanda Cristina Ribeiro, Joana Isabel Silva and João Rodrigues-Carvalho

Department of Gastroenterology. Centro Hospitalar Vila Nova de Gaia/Espinho. Portugal

References

1. Kopacova M, Tacheci I, Rejchrt S, et al. Peutz-Jeghers syndrome: Diagnostic and therapeutic approach. World J Gastroenterol 2009; 15:5397-408.
2. Serrano M, Mão-de-Ferro S, Pinho R, et al. Double-balloon enteroscopy in the management of patients with Peutz-Jeghers syndrome: A retrospective cohort multicenter study. Rev Esp Enferm Dig 2013; 105:594-9.
3. Korsse SE, Dewint P, Kuipers EJ, et al. Small bowel endoscopy and Peutz-Jeghers syndrome. Best Pract Res Clin Gastroenterol 2012; 26:263-78.
4. Jasperson KW, Tuohy TM, Neklason DW, et al. Hereditary and familial colon cancer. Gastroenterology 2010; 138:2044-58.
5. Gorospe EC, Alexander JA, Bruining DH, et al. Performance of double-balloon enteroscopy for the management of small bowel polyps in hamartomatous polyposis syndromes. J Gastroenterol Hepatol 2013;28:268-73.
6. Beggs AD, Latchford AR, Vasen HF, et al. Peutz-Jeghers syndrome: A systematic review and recommendations for management. Gut 2010;59:975-86.
7. Calva D, Howe JR. Hamartomatoys polyposis syndromes. Surg Clin North Am 2008;88:779-817.
8. Postgate A, Despott E, Burling D, et al. Significant small-bowel lesions detected by alternative diagnostic modalities after negative capsule endoscopy. Gastrointest Endosc 2008;68:1209-14.
9. Hakim FA, Alexander JA, Huprich JE, et al. CT-enterography may identify small bowel tumors not detected by capsule endoscopy: Eight years experience at Mayo Clinic Rochester. Dig Dis Sci 2011; 56:2914-9.
10. Zagorowicz ES, Pietrzak AM, Wronska E, et al. Small bowel tumors detected and missed during capsule endoscopy: Single center experience. World J Gastroenterol 2013;19:9043-8.