

## CASE REPORT

# Fanconi syndrome and chronic renal failure in a chronic hepatitis B monoinfected patient treated with tenofovir

Pedro Magalhães-Costa, Leopoldo Matos, Pedro Barreiro and Cristina Chagas

*Gastroenterology Department. Hospital Egas Moniz, Centro Hospitalar Lisboa Ocidental. Lisboa, Portugal*

### ABSTRACT

Tenofovir disoproxil fumarate (TDF) is one of the first-line treatment options in chronic hepatitis B (CHB). Despite its efficacy in suppressing viral load and a high resistance barrier, long life maintenance therapy is required. Registration studies demonstrated TDF to be a safe drug. However, post-marketing experience reported cases of serious nephrotoxicity associated with hypophosphatemia, osteomalacia and, even more recently, Fanconi syndrome associated with TDF therapy in CHB monoinfected patients.

Here the authors report a case of a 40 year-old male, with a CHB mono-infection, that, three years after TDF therapy, developed a progressive chronic kidney disease with a serious hypophosphatemia and a secondary osteomalacia that was manifested by bone pain and multiple bone fractures. Further investigational analyses unveiled a proximal renal tubular dysfunction, which fulfilled most of the diagnostic criteria for a Fanconi syndrome. After TDF withdrawal and oral supplementation with phosphate and calcitriol, his renal function stabilized (despite not returning to normal), proximal renal tubular dysfunction abnormalities resolved as well as osteomalacia. In conclusion, physicians should be aware that, in CHB monoinfected patients under TDF therapy, serious renal damage is possible and preventable by timely monitoring serum creatinine and phosphate.

**Key words:** Tenofovir. Chronic hepatitis B. Chronic renal disease. Nephrotoxicity. Proximal tubular dysfunction. Fanconi syndrome.

### INTRODUCTION

It is estimated that 400 million people worldwide are chronically infected with the hepatitis B virus (HBV). Oral treatment options, until the year 2000, were limited to a single agent, lamivudine. Since then, four newer oral agents have become available, adefovir, telbivudine, entecavir and tenofovir disoproxil fumarate (TDF). Although complete eradication of the virus is not yet possible, these newer agents have higher antiviral potency and higher genetic barriers to resistance, particularly the latter two drugs, making

them the first choice for oral treatment. Additionally, regression of fibrosis and even cirrhosis has been demonstrated with long-term treatment (1). Given these findings, patients with advanced liver fibrosis and cirrhosis will require life-long treatment duration. Therefore, hepatologists should be familiarized with the safety profile of these drugs. The most common side effects of nucleos(t)ide analogues (NA) reported in chronic hepatitis B (CHB) treatment include potential effects on neuromuscular function, renal function and bone mineralization. Registration studies of TDF in the treatment of human immunodeficiency virus (HIV), demonstrated a good renal safety profile (2,3). Although uncommon, Fanconi syndrome has been reported almost exclusively in HIV infected patients treated with TDF in combination with other antivirals (4). Very recently, three cases of Fanconi syndrome were reported in CHB monoinfected patients under TDF (5,6).

### CASE REPORT

We present a 40-year-old Caucasian male that was diagnosed with HBV mono-infection (HBeAg positive) since 2008 and medicated with TDF thereafter, achieving a total virological response (undetectable HBV DNA after six months of therapy). In August 2009, he had a serum creatinine (sCr) of 1.4 mg/dL (normal range: 0.7-1.3 mg/dL), eGFR (estimated glomerular filtration rate) using CKD-EPI (chronic kidney disease epidemiology collaboration) of 64.6 mL/min/1.73 m<sup>2</sup> and an alkaline phosphatase (ALP) of 224 IU/L (normal range: 38-126 IU/L) (Fig. 1A). Three years later (August 2012), his routine blood analysis showed a sCr of 1.5 mg/dL (eGFR = 58.6 mL/min/1.73 m<sup>2</sup>), a severe hypophosphatemia (Fig. 1B) –serum inorganic phosphate (SPhos) of 1.3 mg/dL (normal range: 2.5-4.5 mg/dL) and an ALP of 217 IU/L. He referred

Received: 14-11-2014  
Accepted: 09-02-2015

**Correspondence:** Pedro Magalhães-Costa. Gastroenterology Department. Hospital Egas Moniz, Centro Hospitalar Lisboa Ocidental. Lisboa, Portugal  
e-mail: pmagalhaescosta@gmail.com

Magalhães-Costa P, Matos L, Barreiro P, Chagas C. Fanconi syndrome and chronic renal failure in a chronic hepatitis B monoinfected patient treated with tenofovir. *Rev Esp Enferm Dig* 2015;107:512-514.

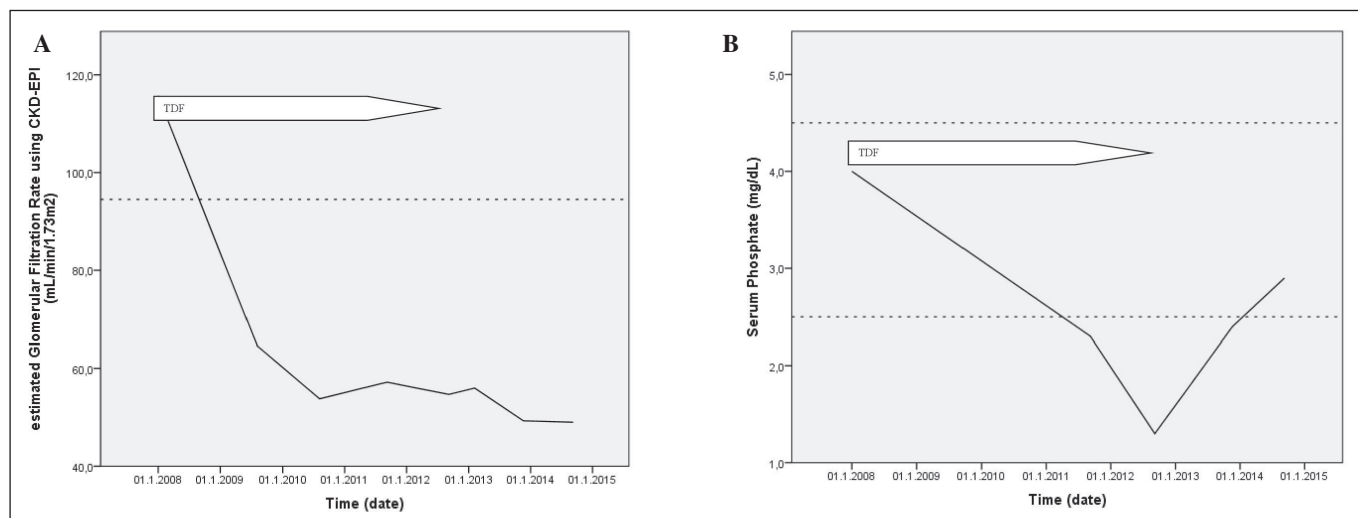


Fig. 1. A. Renal function evolution since TDF initiation and withdrawal (eGFR using CKD-EPI: Estimated glomerular filtration rate using chronic kidney disease epidemiology collaboration; TDF: Tenofovir disoproxil fumarate). B. Serum inorganic phosphate levels since TDF initiation and withdrawal (dashed lines: Up and lower limits of normal; normal range: 2.5-4.5 mg/dL) (TDF: Tenofovir disoproxil fumarate).

also a constant right hip pain without recognizing previous trauma. Hip joint magnetic resonance imaging (MRI) (Fig. 2A) demonstrated, in the femoral neck, the presence of an elongated area of hyposignal in T1 and hypersignal in T2 in the trabecular bone extending into the cortical bone, compatible with a recent fracture. Also, another fracture was evident extending into the greater trochanter of the femur. Serum desoxipiridinoline (a marker of bone turnover) levels were mildly increased (5.9 nmol; normal range: 2.3-5.4 nmol). Skeletal scintigraphy (Fig. 2B-D) revealed a diffuse osteoblastic hyperactivity located mainly in the lower limbs (right femur, right little trochanter and bilaterally in the costal arches). Further investigation revealed a mild vitamin D (25-OH-calciferol) deficiency (66 nmol/L; normal range: 75-250 nmol/L), hypercalciuria (449 mg/24 h; normal range: 100-300 mg/24 h), glycosuria (200 mg/24 h; normal range: 110-125 mg/dL) with normal serum glucose, increased uricosuria (1500 mg/24 h; normal range: 250-750 mg/24 h) and decreased serum urate (1.9 mg/dL; normal range: 3-5-8.5 mg/dL), non-nephrotic proteinuria (urinary protein/creatinine ratio: 294; normal range: < 200 mg/day) and an increased fractional excretion of phosphate (41%; normal range: 5%-18%). His serum potassium and parathyroid hormone concentrations were normal and the patient denied taking any other drug. Kidney ultrasonography revealed the presence of two small kidneys with regular shape and an increased cortical echogenicity without signs of obstruction.

Given the suspected toxicity (Fanconi syndrome with chronic kidney disease and a secondary osteomalacia) induced by TDF, the drug was switched to entecavir. The patient was also medicated with oral supplementation with phosphate (40 mmol *per* day) and colecalciferol. Two years later, the patient had no osteoarticular pain, SPhos

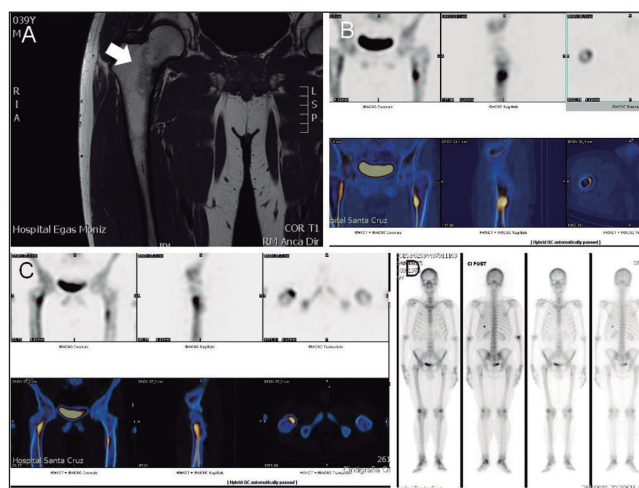


Fig. 2. A. Right hip joint MRI. In the femoral neck, an elongated area of hyposignal in T1 (white arrow) in the trabecular bone extending into the cortical bone, compatible with a recent fracture. B-D. Skeletal scintigraphy. An increased uptake of the radiodrug in the right and left little trochanter. At a lesser extent, a focal increased uptake in the ribs, sternoclavicular joint, elbows, wrists, hands, knees, tibio-tarsic joints, tarsal bones, little joints of both hands and feet.

(Fig. 1B) and 25-OH-calciferol serum levels returned to normal, however, the renal damage was irreversible as his sCr remained elevated but stable (1.7 mg/dL) with a eGFR = 49.3 mL/min/1.73 m<sup>2</sup> (Fig. 1A).

**DISCUSSION**

Tenofovir disoproxil fumarate, the oral prodrug of tenofovir, exhibits antiviral activities against HBV and

HIV. It is eliminated by glomerular filtration and tubular secretion in the kidney. The drug is actively uptaken from the bloodstream into the proximal tubule cells by the human renal organic anion transporters 1 and 3. The efflux from these cells into the tubular lumen is mediated by the multidrug resistance protein 4 (7). Excessively high intracellular tenofovir concentrations locally interfere with the replication of mitochondrial DNA (8). The cause of renal tubular dysfunction in patients treated with TDF may be secondary to specific mitochondrial DNA toxicity within the proximal renal tubules (9,10). Although the efficacy of TDF seems to be similar between HBV monoinfected patients and HBV-HIV coinfecting patients, it is to be expected that drug-related adverse events are different because the latter are probably exposed to numerous nephrotoxic drugs, such as different antivirals, antibiotics and nonsteroidal anti-inflammatory drugs (10). Also, HIV infection and opportunistic infections are associated with glomerular and/or tubulointerstitial damage. Fanconi syndrome with tubular phosphate loss and osteomalacia after supra-therapeutic doses of TDF are well demonstrated in animal models (11). In humans, increases in serum creatinine (> 0.5 mg/dL above baseline) and grade 2 (2.0-2.4 mg/dL) hypophosphatemia have been described in less than 1% of the patients treated with TDF after 96 weeks of follow-up (12). Isolated cases of osteomalacia secondary to a Fanconi syndrome have been reported in HIV patients (13-15). Until recently, not a single case of renal tubular dysfunction has been reported in the literature in the HBV monoinfected population.

Here, we report a case of a 40 year-old Caucasian male, HBV monoinfected, medicated with TDF since 2008. After three years on therapy, the patient exhibited an important decrease in his eGFR and a full-blown Fanconi syndrome (hypophosphatemia with increased fractional excretion of phosphate, hypercalciuria, glycosuria with normal glycaemia, hyperuricosuria with hypouricemia and vitamin D deficiency) consummated with a serious osteomalacia and multiple bone fractures (increased ALP, desoxypyridinoline levels, skeletal scintigraphy and MRI findings). Withdrawing the offending drug and giving oral supplementation of phosphate and vitamin D were crucial measures, resolving the bone disorder and stabilizing renal function, however, the latter could not be restored to normal.

In order to avoid toxicity in HBV infected patients under TDF treatment, physicians need to be aware of coexisting risk factors for kidney toxicity (older age, diabetes mellitus, atherosclerotic disease and other co-medications).

Regular monitoring of serum creatinine and phosphate is recommended by the manufacturer. Also, dose adjustments according to creatinine clearance are suggested. In conclusion, despite being a rare and unpredictable adverse event, serious renal damage and Fanconi syndrome secondary to TDF can occur and should be preventable with timely measurements of serum creatinine and phosphate.

## REFERENCES

1. Marcellin P, Gane E, Buti M, et al. Regression of cirrhosis during treatment with tenofovir disoproxil fumarate for chronic hepatitis B: A 5-year open-label follow-up study. *Lancet* 2013;381:468-75.
2. Squires K, Pozniak AL, Pierone Jr. G, et al. Tenofovir disoproxil fumarate in nucleoside-resistant HIV-1 infection: A randomized trial. *Ann Intern Med* 2003;139:313-20.
3. Schooley RT, Ruane P, Myers RA, et al. Tenofovir DF in antiretroviral-experienced patients: Results from a 48-week, randomized, double-blind study. *AIDS* 2002;16:1257-63.
4. Karras A, Lafaurie M, Furco A, et al. Tenofovir-related nephrotoxicity in human immunodeficiency virus-infected patients: Three cases of renal failure, Fanconi syndrome, and nephrogenic diabetes insipidus. *Clin Infect Dis* 2003;36:1070-3.
5. Gracey D, Snelling P, McKenzie P, et al. Tenofovir-associated Fanconi syndrome in patients with chronic hepatitis B mono-infection. *Antivir Ther* 2013;18:945-8.
6. Samarkos M, Theofanis V, Eliadi I, et al. Tenofovir-associated Fanconi syndrome in a patient with chronic hepatitis B. *J Gastrointest Liver Dis* 2014;23:339-45.
7. Cihlar T, Ray AS, Laflamme G, et al. Molecular assessment of the potential for renal drug interactions between tenofovir and HIV protease inhibitors. *Antivir Ther* 2007;12:267-72.
8. Lebrecht D, Venhoff AC, Kirschner J, et al. Mitochondrial tubulopathy in tenofovir disoproxil fumarate-treated rats. *J Acquir Immune Defic Syndr* 2009;51:258-63.
9. Gitman MD, Hirschwerk D, Baskin CH, et al. Tenofovir-induced kidney injury. *Expert Opin Drug Saf* 2007;6:155-64.
10. Duarte-Rojo A, Heathcote EJ. Efficacy and safety of tenofovir disoproxil fumarate in patients with chronic hepatitis B. *Therap Adv Gastroenterol* 2010;3:107-19.
11. Van Rompay KK, Brignolo LL, Meyer DJ, et al. Biological effects of short-term or prolonged administration of 9-[2-(phosphonomethoxy)propyl]adenine (tenofovir) to newborn and infant rhesus macaques. *Antimicrob Agents Chemother* 2004;48:1469-87.
12. Heathcote J, Gane EJ, DeMan RA, et al. Two year tenofovir disoproxil fumarate (TDF) treatment and adefovir dipivoxil (ADV) switch data in HBeAg-positive patients with chronic hepatitis B (Study 103), preliminary analysis. *Hepatology* 2008;48:376A.
13. Perrot S, Aslangul E, Szebel T, et al. Bone pain due to fractures revealing osteomalacia related to tenofovir-induced proximal renal tubular dysfunction in a human immunodeficiency virus-infected patient. *J Clin Rheumatol* 2009;15:72-4.
14. Parsonage MJ, Wilkins EGL, Snowden N, et al. The development of hypophosphataemic osteomalacia with myopathy in two patients with HIV infection receiving tenofovir therapy. *HIV Med* 2005;6:341-6.
15. Earle KE, Seneviratne T, Shaker J, et al. Fanconi's syndrome in HIV+ adults: Report of three cases and literature review. *J Bone Miner Res* 2004;19:714-21.