1130-0108/2016/108/1/40-41
Revista Española de Enfermedades Digestivas

Rev Esp Enferm Dig (Madrid)
Vol. 108, N.º 1, pp. 40-41, 2016

PICTURES IN DIGESTIVE PATHOLOGY

Splenosis: Non-invasive diagnosis of a great mimicker

Inés Sánchez-Paniagua, Sandra Baleato-González and Roberto García-Figueiras

Department of Radiodiagnosis. Complejo Hospitalario Clínico Universitario de Santiago. Santiago de Compostela, A Coruña. Spain

CASE REPORTS

Case report 1. A 55-year-old man with a history of previous splenectomy presented with complaints for persistent unexplained fever and weight loss. Abdominal ultrasound showed a nodular lesion of 27 mm in the right lobe. A contrast-enhanced computed tomography (CT) exam identified multiple peritoneal nodules with marked enhancement (Fig. 1). Based on Imaging features and the history of splenectomy, the diagnosis of splenosis was suggested. However, exploratory laparotomy was performed. Splenosis was confirmed. Clinical manifestations subsequently disappeared.

Case report 2. A 37-year-old man presented with episodes of periumbilical abdominal pain associated with weight loss for about one month. His past medical history included splenectomy. Contrast-enhanced abdominal CT study showed multiple possibly liver and peritoneal lesions, which showed a hypervascular behaviour compared with liver parenchyma in the arterial phase and same density as the parenchyma in the venous phase. A magnetic resonance exam confirmed the location of lesions and a dynamic behavior different to the hepatic parenchyma (Fig. 2). A technetium (Tc) 99m-labeled heat-denatured erythrocytes scintigraphy confirmed the diagnosis (Fig. 2).

DISCUSSION

Splenosis is defined as the heterotopic location of splenic tissue in the abdominal cavity or other atypical location (1-5). Up to 67% of patients with splenic rupture develop splenosis implants (1-3). Compared with normal spleen, these implants have a discreetly different architecture with

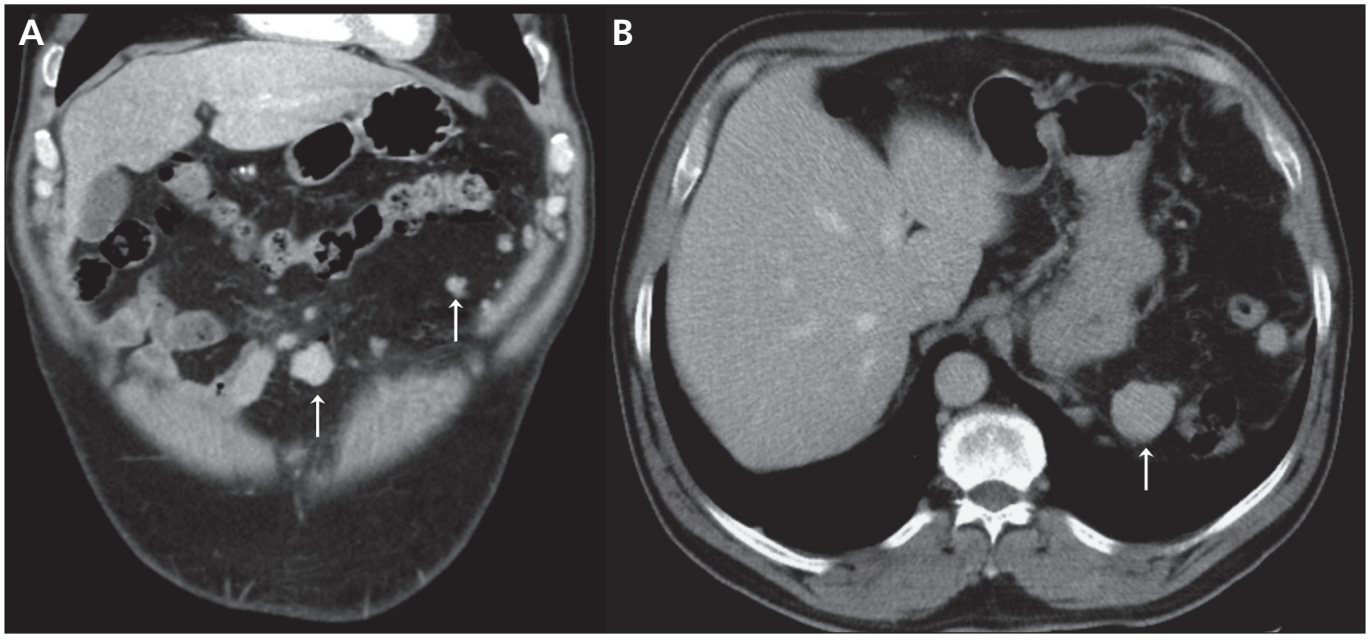

Fig. 1. Coronal multiplanar reformation image from a contrast-enhanced CT exam in the arterial phase (A) shows multiple peritoneal implants corresponding to implants of splenosis. Axial contrast-enhanced CT image in the portal phase (B) shows an homogeneous enhancement in the foci of splenosis.

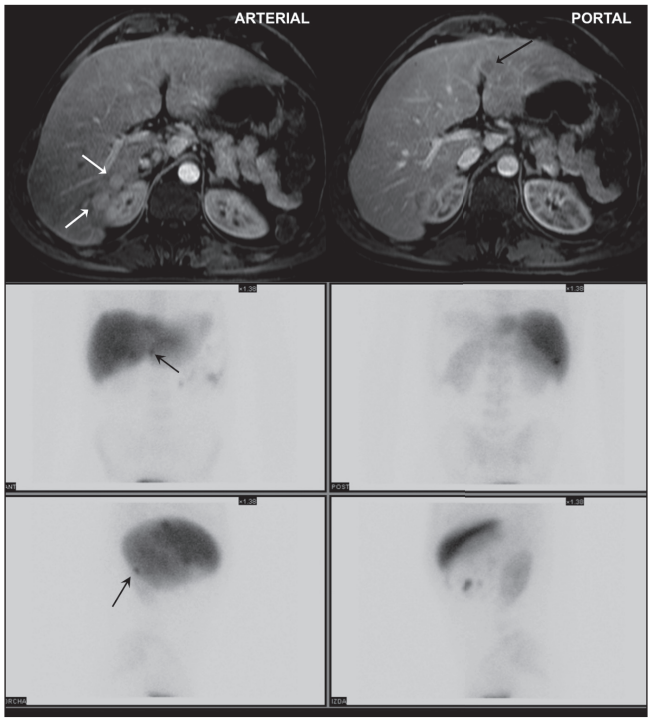

Fig. 2. Axial contrast-enhanced T1-weighted gradient echo images in the arterial (upper row-left) and the portal phase (upper row-right) show multiple liver lesions with a dynamic behaviour similar to normal spleen. Tc 99m-tagged heat-damaged red blood cell scintigraphy images (bottom) evidence mutiple foci with tracer uptake.

plenty of red pulp and little white pulp (1-5). However, its functionalism is similar, eliminating the aged blood cells and maintaining normal immunological function (2-5). Splenosis implants show a non-specific clinical, being in most cases as an incidental finding on imaging tests (1-4). They can be confused with other entities including peritoneal carcinomatosis, endometriosis, and metastatic disease (1-5). The history of splenectomy together with the anatomical distribution and the dynamic behavior of these lesions on contrast-enhanced imaging studies may suggest this entity. Tc 99m-tagged heat-damaged red blood cell scintigraphy is the best imaging technique in order to stablish the final diagnosis, avoiding unnecessary biopsies or surgerys (1-5).

REFERENCES

1. Tsitouridis I, Michaelides M, Sotiriadis C, et al. CT and MRI of intraperitoneal splenosis. Diagn Interv Radiol 2010;16:145-9.
2. Vercher-Conejero JL, Bello-Arqués P, Pelegrí-Martínez L, et al. Esplenosis intraabdominal: una entidad frecuentemente infradiagnosticada. Rev Esp Med Nuc 2011;30:97-100. DOI: 10.1016/j.remn.2010.04.009
3. Ksiadzyna D, Peña AS. Abdominal splenosis. Rev Esp Enferm Dig 2011;103:421-6.
4. Levy AD, Shaw JC, Sobin LH. Secondary tumors and tumorlike lesions of the peritoneal cavity: Imaging features with pathologic correlation. Radiographics 2009;29:347-73. DOI: 10.1148/rg.292085189
5. Yildiz AE, Ariyurek MO, Karcaaltincaba M. Splenic anomalies of shape, size, and location: Pictorial essay. Scientific World Journal 2013;2013:321810. DOI: 10.1155/2013/321810