1130-0108/2016/108/2/98-99
Revista Española de Enfermedades Digestivas

Rev Esp Enferm Dig (Madrid)
Vol. 108, N.º 2, pp. 98-99, 2016

PICTURES IN DIGESTIVE PATHOLOGY

Rectosigmoid carcinoma presenting with a large small bowel fistula

María Dolores Pérez-Valderas, Óscar Nogales-Rincón, Javier García-Lledó, Leticia Pérez-Carazo, Beatriz Merino-Rodríguez, Ignacio Marín-Jiménez, Cecilia González-Asanza and Pedro Menchén-Fernández-Pacheco

Department of Digestive Diseases. Hospital General Universitario Gregorio Marañón. Madrid, Spain

INTRODUCTION

Colorectal cancer (CRC) is the third most common malignant neoplasm worldwide and the second leading cause of cancer deaths.

CASE REPORT

A 44-year-old woman, native from Colombia, presented to the emergency room with abdominal pain, fever, watery diarrhea (around 10 bowel movements per day) and occasional rectal bleeding. She complained of an 8 Kg weight loss the last 12 months. She had been studied at another hospital over the preceding 12 months with a suspected diagnosis of inflammatory bowel disease. In December 2012, an abdominal TAC examination was performed at that institution and was informed as a mural engrossment of multiple terminal ileum loops suggestive of inflammatory bowel disease (no radiological images were available). On physical examination, there were no peritoneal reaction signs or palpable masses, and bowel movements were preserved. A laboratory test showed microcytic anemia (Hb 6.1 g/dl, MCV 49.9 fL), without leukocytosis. Because of her recent history, a preferential colonoscopy was indicated. Colonoscopy showed an ulcerated neoplasm 20 cm above anal margin, which affected colon wall circumferentially and caused a stenosis rendering colonoscope passage impossible. A gastroscope was progressed through the stenosis. It showed a big size necrotic cavity which directly connected the colon with two small bowel loops by neoplastic entero-colonic fistulas (Fig. 1). The histopathological report revealed a poorly differentiated adenocarcinoma. Computed tomography (CT) scans of the chest, abdomen and pelvis confirmed the rectosigmoid carcinoma with a large small bowel fistula (Fig. 2) without any other pathological finding.

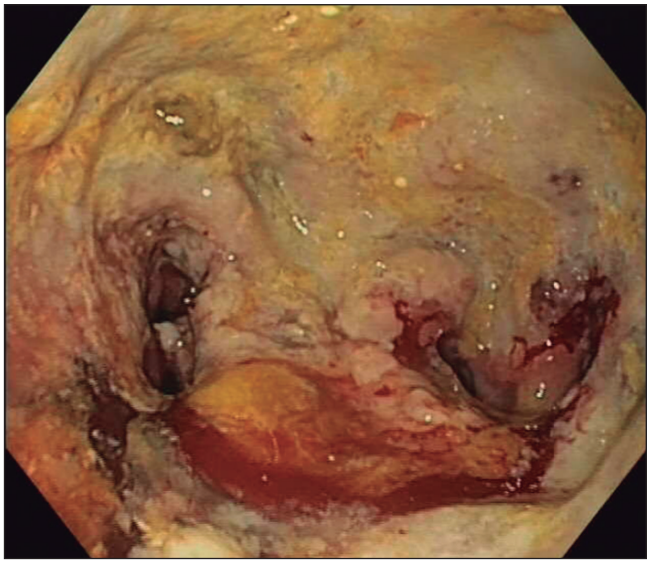

Fig. 1. Big size necrotic cavity which directly connected the colon with two small bowel loops.

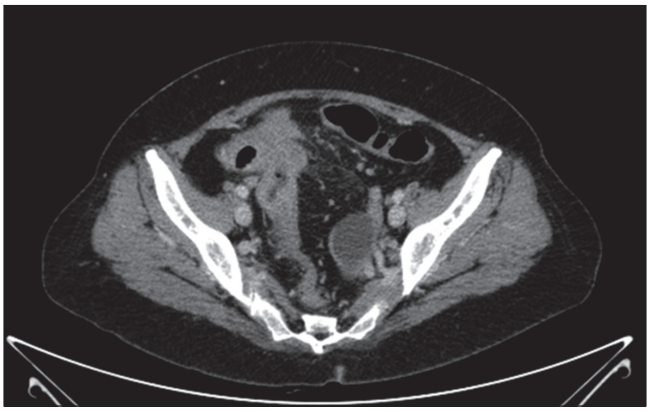

Fig. 2. Rectosigmoid carcinoma presenting a large small bowel fistula.

DISCUSSION

Fistula between the colon and adjacent structures is a rare complication of colon cancer. It is the result of the primary tumor ulceration with either a peritoneal reaction or an organization of exudates that leads to an adherence of the adjacent structures and then the eventual perforation

into the lumen of other organ (3,5). Radiological studies are the most sensitive techniques in the detection and characterization of a fistulous tract (1), whilst colonoscopy (2,4) allows direct endoscopic visualization and can obtain biopsies for histological study.

REFERENCES

1. Domínguez-Ayala M, Díez-Vallejo J, Comas-Fuentes Á. Missed opportunities in early diagnosis of symptomatic colorectal cancer. Rev Esp Enferm Dig 2012;104:343-9. DOI: 10.4321/S1130-01082012000700002
2. Carballo F, Muñoz-Navas M. Prevention or cure in times of crisis: The case of screening for colorectal cancer. Rev Esp Enferm Dig 2012;104:537-45. DOI: 10.4321/S1130-01082012001000006
3. Aluja F, Rivera AL, Carrillo-Bayona JA. Fístula gastrocólica por adenocarcinoma de colon transverso: presentación de un caso. Rev Colomb Radiol 2012;23:3587-91.
4. Gollub MJ, Schwartz LH, Akhurst T. Update on colorectal cancer imaging. Radiol Clin North Am 2007;45:85-118. DOI: 10.1016/j.rcl.2006.10.003
5. Forshaw MJ, Dastur JK, Murali K, et al. Long-term survival from gastrocolic fistula secondary to adenocarcinoma of the transverse colon. World J Surg Oncol 2005;3:9. DOI: 10.1186/1477-7819-3-9