1130-0108/2016/108/6/364-365
Revista Española de Enfermedades Digestivas
Copyright © 2016 Arán Ediciones, S. L.
Rev Esp Enferm Dig (Madrid)
Vol. 108, N.º 6, pp. 364-365, 2016

PICTURES IN DIGESTIVE PATHOLOGY

Granular cell tumor of cecum

M.ª Fernanda Berzal-Cantalejo, Ana Rosa González-Medina and Beatriz Torío-Sánchez

Department of Pathology. Hospital Universitario Río Carrión. Palencia, Spain

CASE REPORT

We present the case of a 47-year-old man with family history of colorectal carcinoma (father and paternal uncle). He went to medical consultation because of nonspecific digestive complaints. Three polyps measuring less than 1 cm were removed during colonoscopy in cecum, right colon and sigmoid colon. Histological examination of the polyp in cecum revealed a submucosal tumor composed of polygonal cells with round nuclei, granular eosinophilic cytoplasm (Fig. 1) and positive PAS staining (inset figure 1). Immunohistochemical analysis showed that the tumor cells expressed S-100 protein (Fig. 2) and neuron-specific enolase (Fig. 3), but were negative for c-kit, CD68, desmin and smooth muscle actin. Based on these findings a diagnosis of granular cell tumor was made. The resected polyps in right and sigmoid colon revealed two tubular adenomas with low-grade dysplasia.

DISCUSSION

Granular cell tumors are very rare in the gastrointestinal tract. The esophagus is the most common site followed by the duodenum, anus and stomach (1). These tumors usually present as asymptomatic little polyps and endoscopic resection is accepted. The diagnosis depends on histopathological analysis, revealing a proliferation

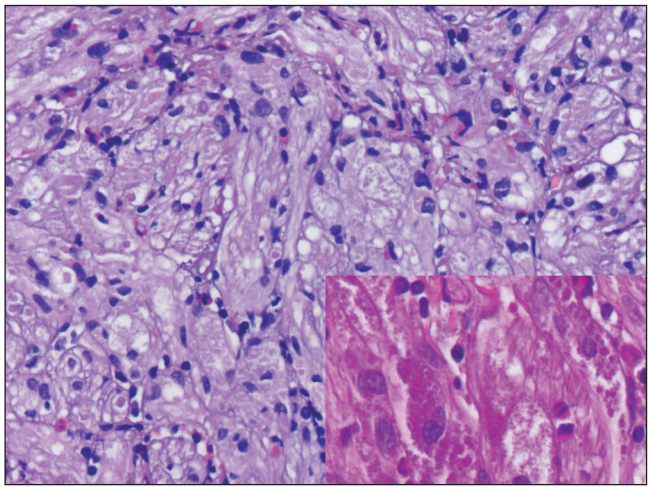

Fig. 1. The tumor is composed of polygonal cells with finely granular eosinophilic cytoplasm and uniform round nuclei (hematoxylin and eosin staining, x200). Inset: PAS staining (x400).

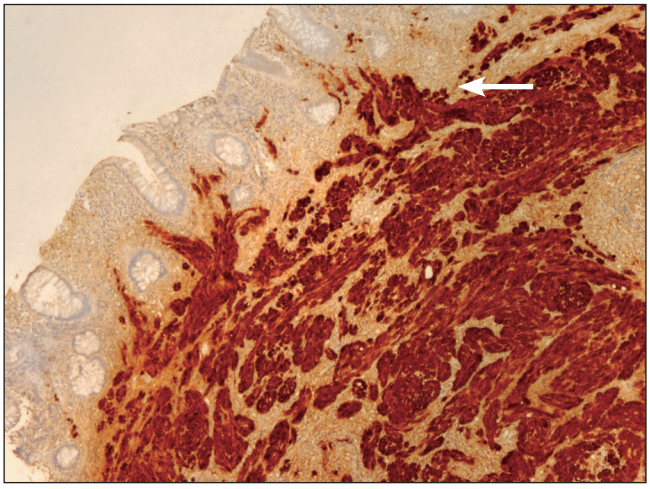

Fig. 2. Nuclear and cytoplasmic positive immunoreaction for S-100 protein (x100).

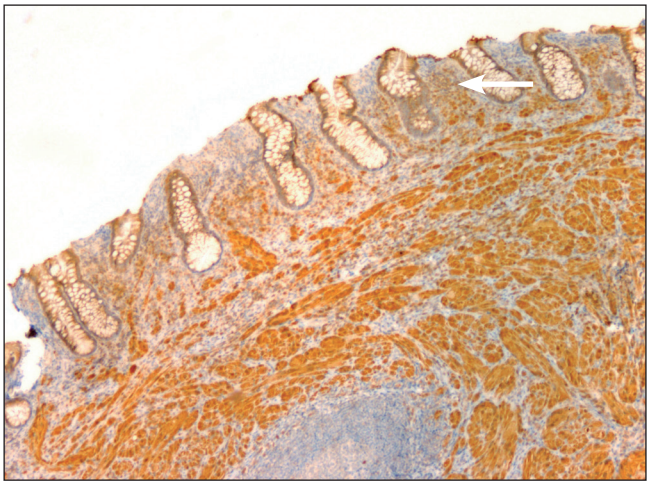

Fig. 3. Cytoplasmic positive immunoreaction for neuronal-specific enolase (x100).

of polygonal cells with abundant granular cytoplasm, positive for PAS staining (2). Malignant granular cell tumors are extremely uncommon with few cases reported in the literature. Some features associated with malignancy include a rapid growth, size greater than 4 cm and invasion of adjacent tissues. Microscopic criteria to predict the malignant potential include necrosis, cellular atypia and more than 2 mitoses per 10 high power fields (3). Although endoscopic resection is curative, local recurrence has been reported and follow-up colonoscopic examination is necessary (4). Because multifocal disease has been described, gastroscopy is recommended to exclude the presence of granular cell tumors in the esophagus and/or stomach (5).

REFERENCES

1. Lack EE, Worsham GF, Callihan MD, et al. Granular cell tumor: A clinicopathological study of 110 patients. J Surg Oncol 1980;13:301-16. DOI: 10.1002/jso.2930130405
2. Rossi GB, de Bellis M, Marone P, et al. Granular cell tumors of the colon: Report of a case and review of the literature. J Clin Gastroenterol 2000;30:197-9. DOI: 10.1097/00004836-200003000-00014
3. Fanburg-Smith JC, Meis-Kindblom JM, Fante R, et al. Malignant granular cell tumor of soft tissues. Diagnostic criteria and clinicopathologic correlation. Am J of Surg Pathol 1998;22:779-94. DOI: 10.1097/00000478-199807000-00001
4. Endo S, Hirasaki S, Doi T, et al. Granular cell tumor occurring in the sigmoid colon treated by endoscopic mucosal resection using a transparent cap (EMR-C). J Gastroenterol 2003;38:385-9. DOI: 10.1007/s005350300068
5. Cha JM, Lee JI, Joo KR, et al. Granular cell tumor of the descending colon treated by endoscopic mucosal resection: A case report and review of the literature. J Korean Med Sci 2009;24:337-41. DOI: 10.3346/jkms.2009.24.2.337