1130-0108/2017/109/1/63-64
Revista Española de Enfermedades Digestivas
© Copyright 2017. SEPD y © ARÁN EDICIONES, S.L.
Rev Esp Enferm Dig
2017, Vol. 109, N.º 1, pp. 63-64

PICTURES IN DIGESTIVE PATHOLOGY

Endoscopic retrieval of toothbrushes in a schizophrenic patient

José Luis Beristain-Hernández, Mario Eduardo Torres-Olalde and Martín Rojano-Rodríguez

Department of Gastrointestinal Endoscopy. Hospital General "Dr. Manuel Gea González". Ciudad de México, México

INTRODUCTION

Foreign bodies are a common finding in the endoscopic practice. Nevertheless, long objects as toothbrushes pose a special problem when trying to remove them from the stomach.

CASE REPORT

We present the case of a 33-year-old male, with schizophrenia, and deliberate oral intake of multiple objects: two toothbrushes, a pen, a lighter and a metallic clip. He had already undergone previous surgeries for extraction of foreign bodies (Fig. 1).

He underwent an upper gastrointestinal endoscopy in the operating room, to assess the feasibility of endoscopic retrieval. He was under general anesthesia, endotracheal intubation and an overtube.

Two toothbrushes were found stuck in the pylorus, they were retrieved by means of a polypectomy snare and pulled back into the stomach (Fig. 2). Then, they were realigned in the esophagus axis, with the snare and an alligator-toothed retrieval forceps (Fig. 3).

Objects were grasped with the snare close to the endoscope and pulled out of the hiatus; then in the esophagus

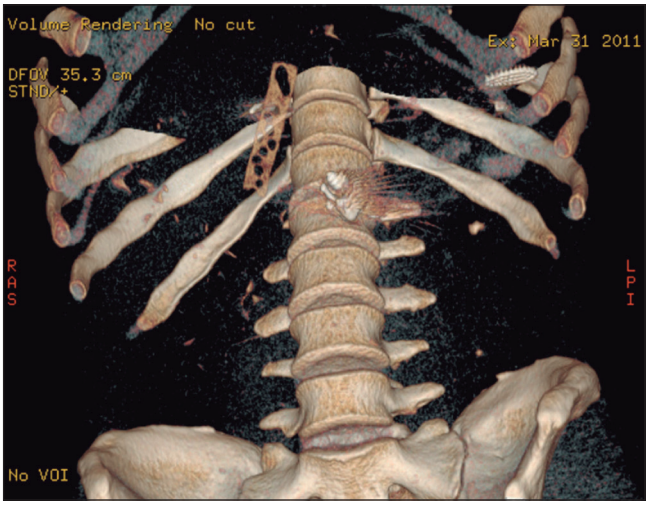

Fig. 1. CT scan 3D-reconstruction showing multiple objects in intragastric localization.

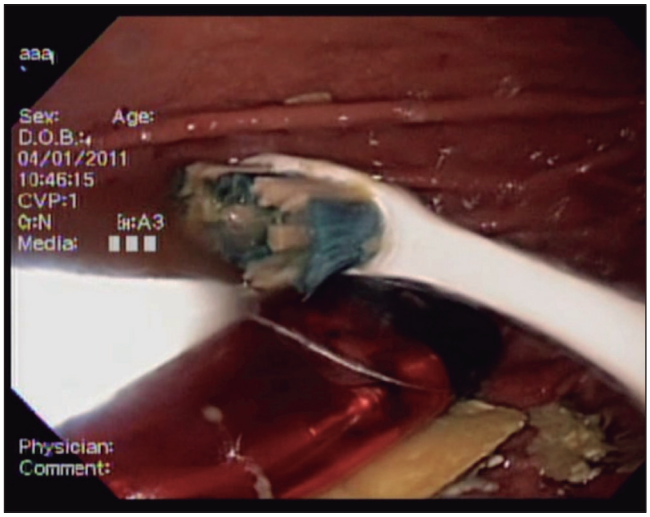

Fig. 2. Upper GI endoscopy image showing a polypectomy snare catching a lighter and a toothbrush.

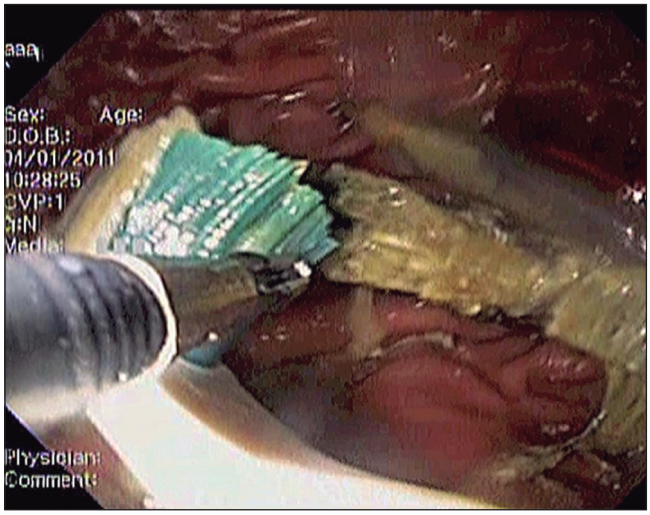

Fig. 3. Upper GI endoscopy image showing a biopsy forceps realigning the toothbrush head to the esophagus axis.

they were taken out with the protection of an overtube. Patient was discharged at 48 hours without complications.

DISCUSSION

Flexible endoscope remains an effective and safe device for extraction of foreign bodies from the upper gastrointestinal tract, especially when using polypectomy snare and rat-toothed forceps as in our case (1).

Deliberate ingestion of foreign bodies is usual in psychiatric population with a high percentage of them still requiring surgical extraction. Toothbrushes represent a critical clinical challenge due to its peculiar shape with less than a hundred cases reported in literature (2,3).

REFERENCES

1. Disney BR, Shetty S. Endoscopic retrieval of a toothbrush in the esophagus. Endoscopy 2014;46(Suppl. 1)UCTN:E449-50. DOI: 10.1055/s-0034-1377496
2. Tonkic A, Bogdanovic Z, Grandić L. Successful endoscopic removal of a swallowed toothbrush: Case report. Case Reports in Gastroenterology 2011;5:122-4. DOI: 10.1159/000326962
3. Faust J, Schreiner O. A swallowed toothbrush. Lancet 2001;357:1012.