1130-0108/2017/109/2/165
Revista Española de Enfermedades Digestivas

Rev Esp Enferm Dig
2017, Vol. 109, N.º 2, pp. 165

Letters to the Editor

Clip and endoloop lifting technique to assist cannulation of a hardly reachable papilla because of anatomical changes due to surgery

Key words: Biliary cannulation. ERCP. Papilla.

DOI: 10.17235/reed.2016.4365/2016

Dear Editor,

We present a case of a 75-year-old man who had been previously diagnosed with an ileal carcinoid tumor with liver metastases. The tumor was treated by ileal resection, right colectomy and chemotherapy. Liver lesions were treated with radioembolization.

An endoscopic retrograde cholangiopancreatography (ERCP) was performed by an expert endoscopist because an ampulloma was suspected. We reached the second portion of the duodenum, but could not introduce the distal tip of the duodenoscope into the lower part of the second portion of the duodenum in spite of several attempts (Fig. 1a). The same complication occurred during an ecoendoscopy performed the previous day, probably due to anatomical changes after surgery. An endoclip (Resolution Clip, Boston Scientific Corporation, Natick, Massachusetts, USA) was placed proximally to the papilla in order to lift it (Fig. 1b). Later, we introduced an endoloop (HX-400U-30, Olympus, Japan) through the working channel of the duodenoscope to take hold of the clip (Fig. 1c) and over it we introduced a guide wire with a hydrophilic tip (Fig. 1d and e) which was pulled on from the outside through the mouth (Fig. 1f). With this technique, we partially lifted the papilla in order to achieve a successful cannulation. An infiltrative periampullar stenosis was found, so we placed a metal biliary stent that allowed a successful biliary drainage.

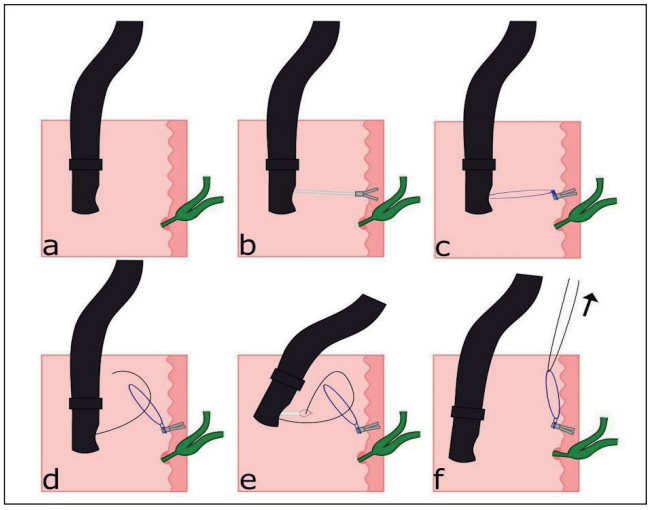

Fig. 1. Schematic showing the stages of the clip and endoloop cannulation process.

Discussion

ERCP can be particularly difficult due to special anatomical features, inflammatory processes, adenomas of the papilla or periampullar diverticulum (1). With a correct cannulation technique, the complications associated with the procedure can be reduced (2). Different techniques have been used to improve the success rate of biliary cannulation: double guide wire technique, wire-guide cannulation over a pancreatic stent, transpancreatic sphinterotomy, needle-knife precut and endoscopic ultrasound-guided rendezvous (3,4). Recently, clip and snare lifting techniques have been described to assist cannulation of a papilla hidden behind a mucosal fold (5).

Maite Alonso-Sierra, Santiago González-Vázquez
and Miguel Muñoz-Navas

Endoscopy Department. Clínica Universidad de Navarra.
Pamplona, Spain

References

1. Yang MJ, Hwang JC, Yoo BM, et al. Wire-guided cannulation over a pancreatic stent versus double guidewire technique in patients with difficult biliary cannulation. BMC Gastroenterol 2015;15:150. DOI: 10.1186/s12876-015-0381-4
2. Udd M, Kylänpää L, Halttunen J. Management of difficult bile duct cannulation in ERCP. World J Gastrointest Endosc 2010;2(3):97-103. DOI: 10.4253/wjge.v2.i3.97
3. Yasuda I, Isayama H, Bhatia V. Current situation of endoscopic biliary cannulation and salvage techniques for difficult cases - Current strategies in Japan. Dig Endosc 2015;19. DOI: 10.1111/den.12591
4. Khan MA, Akbar A, Baron TH, et al. Endoscopic ultrasound-guided biliary drainage: A systematic review and meta-analysis. Dig Dis Sci 2016;61(3):684-703. DOI: 10.1007/s10620-015-3933-0
5. Valente R, Baldaque-Silva F, Siiki A, et al. Clip and snare lifting technique to assist cannulation of a papilla hidden behind a mucosal fold. Endoscopy 2015;47:517-8. DOI: 10.1055/s-0034-1392923