1130-0108/2017/109/4/286-287
Revista Española de Enfermedades Digestivas

Rev Esp Enferm Dig
2017, Vol. 109, N.º 4, pp. 286-287

PICTURES IN DIGESTIVE PATHOLOGY

Enteral stent for the treatment of a urinary fistula associated with a biological mesh following a Bricker-type procedure

Raquel Díaz-Ruiz, Marta Castillo-Pradillo, Óscar Nogales-Rincón and Cecilia González-Asanza

Department of Digestive Surgery. Hospital General Universitario Gregorio Marañón. Madrid, Spain

INTRODUCTION

Postoperative fistula results in increased morbidity and a longer hospital stay. While surgery is the most common treatment, the endoscopic approach (1) is an increasingly used alternative (2).

CASE REPORT

A 57-year-old woman underwent surgery for colonic adenocarcinoma, which relapsed as peritoneal carcinomatosis and was managed with chemotherapy and surgery; a biological Permacol™ mesh was used for abdominal wall closure. In 2015 she relapsed again at the recto-vesical pouch with infiltration of the rectum, bladder, and vaginal dome. She underwent pelvic exenteration with vaginoplasty and Bricker-type urinary diversion across the mesh. During the postoperative period an ileal loop urinary fistula was seen, secondary to mesh decubitus. An endoscopy of the Bricker loop was performed, which revealed a fistulous orifice with a whitish background at 7 cm from the mesh-related ileostomy, which took up 50% of the perimeter (Fig. 1). Endoscopic placement of a 100 mm x 20 mm covered metal stent (Hanarostent® Colon/Rectum) was decided upon (Fig. 2), which was uneventfully removed after 12 weeks, whereupon fistula healing was accomplished (Fig. 3).

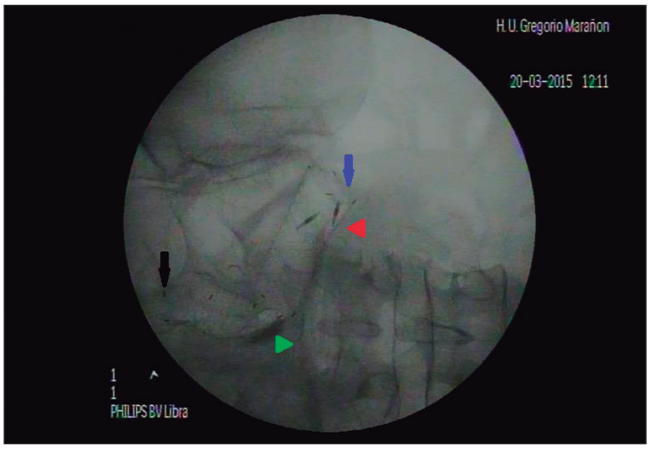

Fig. 2. Stent after placement. Black arrow: stent end close to ileal-ureteral anastomosis. Blue arrow: distal end close to ileostomy. Red triangle: endoscopic clips. Green arrowhead: radiological contrast to mark fistula.

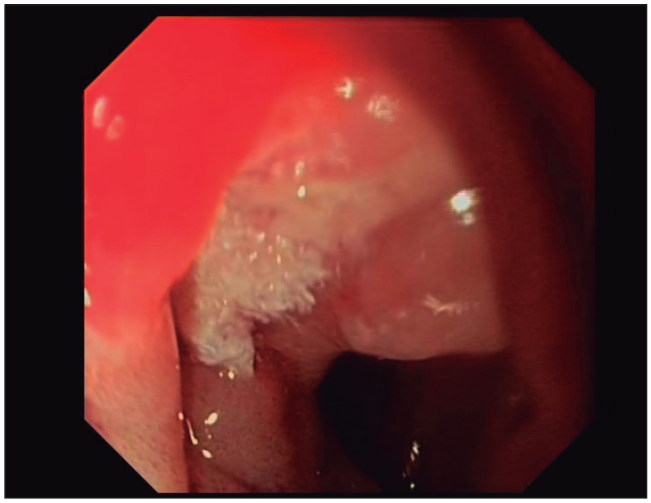

Fig. 1. Endoscopy through the ileal loop. Biological mesh across the fistulous orifice at 7 cm from ileostomy.

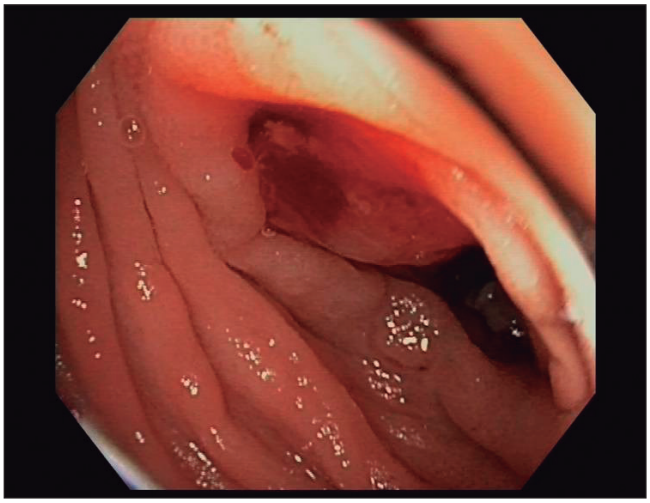

Fig. 3. Endoscopy follow-up after 12 weeks showing fistula healing.

The stent was fitted for a longer period than recommended, due to our experience and the fistula size. Despite a potential relapse risk from mesh persistence, the patient remains free of recurrence, likely due to perifistular fibrosis formation.

DISCUSSION

Complex fistulas at atypical locations may be managed with endoscopically placed metal stents, thus preventing repeated surgery (3).

REFERENCES

1. Mangiavillano B, Pagano N, Arena M, et al. Role of stenting in gastrointestinal benign and malignant diseases. World J Gastrointest Endosc 2015;7:460-80.
2. Lamazza A, Sterpetti AV, De Cesare A, et al. Endoscopic placement of self-expanding stents in patients with symptomatic anastomotic leakage after colorectal resection for cancer: Long-term results. Endoscopy 2015;47:270-2. DOI: 10.1055/s-0034-1391403
3. Montes López C, Romeo Martínez JM, Tejero Cebrián E, et al. Tratamiento de la estenosis neoplásica de colon izquierdo mediante la colocación de prótesis autoexpandibles. Rev Esp Enferm Dig 2001;93:226-31.