1130-0108/2017/109/8/605-606
Revista Española de Enfermedades Digestivas
© Copyright 2017. SEPD y © ARÁN EDICIONES, S.L.
Rev Esp Enferm Dig
2017, Vol. 109, N.º 8, pp. 605-606

Letters to the Editor

Gangliocytic paraganglioma: an unusual cause of upper gastrointestinal bleeding

Key words: Gangliocytic paraganglioma. Upper gastrointestinal bleeding.

DOI: 10.17235/reed.2017.4808/2016

Dear Editor,

Gangliocytic paraganglioma (GP) is a rare benign tumor of an unknown origin usually located in the second duodenal portion (90%), with a predilection to the region of the ampulla of Vater (1).

We report the case of a 68-year-old woman hospitalized for an upper gastrointestinal bleeding (HDA). The patient underwent an oral endoscopy that identified a juxtapapillary submucosal injury (2 cm) laterally displacing the orifice with superficial triangular erosion of the mucosa. Multiple biopsies were performed via gastroscopy, duodenoscopy and echoendoscopy, and showed negative results (irrelevant inflammatory changes). The last biopsy performed by duodenoscopy diagnosed a GP. The injury was resected by laparoscopy with endoscopic support after a negative study of extension (computed tomography [CT], magnetic resonance imaging [MRI], echoendoscopy), without complications. Subsequently, the patient presented with jaundice and dilation of biliary tract identified by colangioRM. An endoscopic retrograde cholangiopancreatography (ERCP) was performed and a stenosis of the papillary orifice was observed that was caused by the surgical suture. The condition was resolved by biliary access with a pre-cut technique and subsequent broad sphincterotomy.

Discussion

GP consists of a mixture of endocrine, ganglionic and spindle-type nerve cells. It presents as a polypoid mass covered by normal duodenal mucosa and has a tendency to ulcerate (2). Treatment options are endoscopic or surgical resection (3).

GP is sometimes confused with a gastrointestinal stromal tumor or ampuloma and the histopathological diagnosis is difficult (negative biopsies) (4). As the treatment and the natural history of these pathologies differ significantly, as well as the fact that aggressive surgery in this region may present severe complications, a high suspicion is required that depends on the clinical presentation and the location of the lesion (5).

The complication presented in this case is infrequent and occurred as a consequence of the difficult location of the lesion, in spite of the endoscopic support.

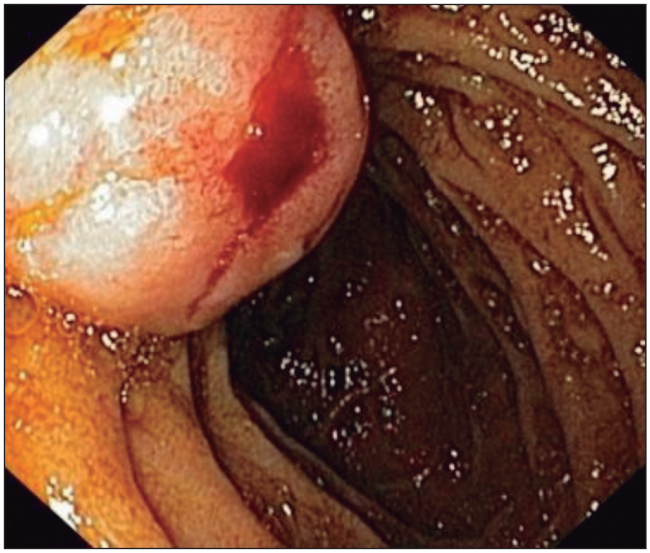

Fig. 1. Gangliocytic paraganglioma.

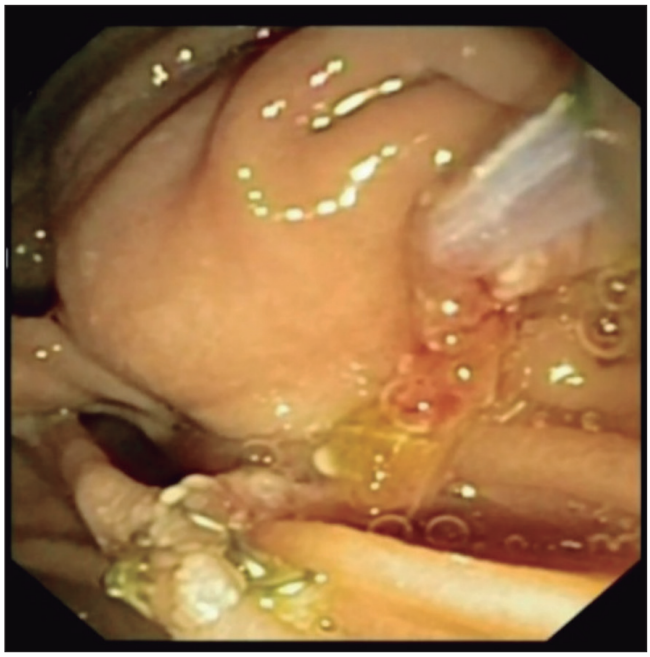

Fig. 2. Surgical suture including view of the papilla during sphincterotomy.

Yolanda María Sánchez-Torrijos, Rafael León-Montañés and María Ángeles Mejías-Manzano

Clinical Management Unit of Digestive Diseases. Hospital Universitario Virgen del Rocío. Sevilla, Spain

References

1. Okubo Y, Wakayama M, Nemoto T. Literature survey on epidemiology and pathology of gangliocytic paraganglioma. BMC Cancer 2011;11:187. DOI: 10.1186/1471-2407-11-187
2. Boeriu A, Dobru D, Georgescu R, et al. Gangliocytic paraganglioma: A rare cause of gastrointestinal bleeding. J Gastrointestin Liver Dis 2015;24:109-12. DOI: http://dx.doi.org/10.15403/jgld.2014.1121.abo
3. Loftusa TJ, Kresak JL, Gonzalob DH, et al. Duodenal gangliocytic paraganglioma: A case report and literature review. Int J Surg Case Rep 2015;8C:5-8.
4. Kwon J, Lee SE, Kang MJ, et al. A case of gangliocytic paraganglioma in the ampulla of Vater. World J Surg Oncol 2010;8:42.
5. Ortega Ramírez JR, Velasco Albendea FJ, Fornés Santamaría S, et al. Paraganglioma gangliocítico en la ampolla de Vater. Una entidad a tener en cuenta en la patología ampular. Rev Esp Patol 2016;49:243-7. DOI: 10.1016/j.patol.2015.09.007