Adult-onset Morgagni's hernia

Key words: Morgagni's hernia.

Dear Editor,

We report the case of a 65-year-old male patient with Down's syndrome and a deep venous thrombosis on anticoagulation with acenocoumarol. The case presented due to nonspecific, predominantly postprandial epigastric discomfort, meteorism and aerophagia. A thoracoabdominal computed tomography (CT) scan revealed a Morgagni hernia with a cephalad migration of part of the stomach, ascending colon and transverse colon (Fig. 1). After laparotomy, the defect was repaired using a titanium mesh and the patient had a favorable outcome.

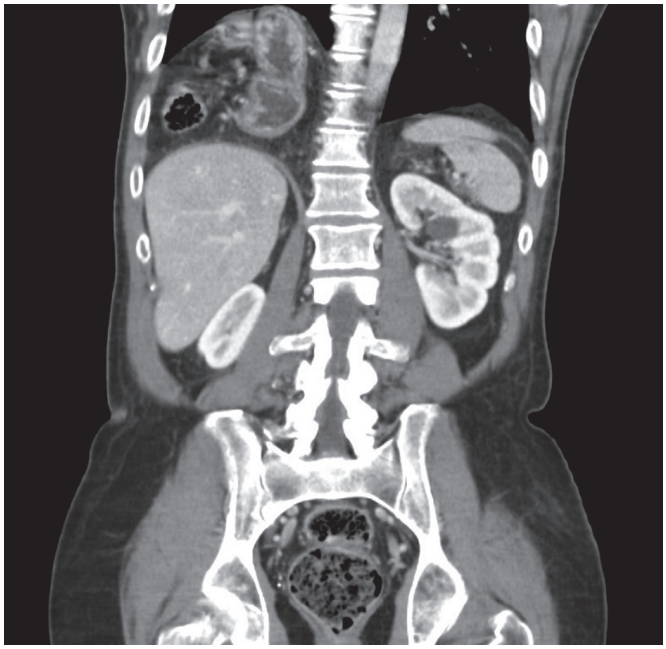

Fig. 1. *Cephalad migration of part of the stomach, ascending colon and transverse colon through a Morgagni hernia. Coronal section.*

Discussion

Morgagni's hernia is the least common of all congenital diaphragmatic hernias, with an incidence of 3% (1). As in this case, it may be associated with Down's syndrome, Turner's syndrome, dextrocardia, Prader-Willi syndrome and tetralogy of Fallot, among others. It is usually an incidental finding in adults and when clinical manifestations are present, these are often nonspecific, although cases with gastric outlet obstruction, respiratory distress or intestinal ischemia have been reported. The imaging technique of choice for the diagnosis of Morgagni's hernia is thoracoabdominal CT (2). Treatment usually consists of surgery with laparotomy but a mixed thoracic and abdominal approach may also be used (3). Furthermore, a case repaired using minimally invasive robotic surgery was recently reported (4).

Eduardo Valdivielso-Cortázar[1], David Carral-Martínez[1], Manuel Gómez-Gutiérrez[2] and Alberto Bouzón-Alejandro[2]
Departments of [1]Digestive Diseases and [2]General Surgery. Complejo Hospitalario Universitario de A Coruña. IMQ San Rafael. A Coruña, Spain

DOI: 10.17235/reed.2018.5425/2017

References

1. Horton JD, Hofmann LJ, Hetz SP. Presentation and management of Morgagni hernias in adults: a review of 298 cases. Surg Endosc 2008;22:1413-20. DOI: 10.1007/s00464-008-9754-x
2. Eren S, Ciris F. Diaphragmatic hernia: diagnostic approaches with review of the literature. Eur J Radiol 2005;54:448-59. DOI: 10.1016/j.ejrad.2004.09.008
3. Díaz-Tobarra M, Garcés-Albir M, Marti-Obiol R, et al. Morgagni's hernia containing apendicular mucocele. Rev Esp Enferm Dig 2013;105:227-8. DOI: 10.4321/S1130-01082013000400008
4. Arevalo G, Harris K, Sadiq A, et al. Repair of Morgagni hernia in adults with primary closure and mesh placement: first robotic experience. J Laparoendosc Adv Surg Tech 2017;27:529-32. DOI: 10.1089/lap.2016.0360

© Copyright 2018. SEPD y © ARÁN EDICIONES, S.L.