Paratesticular Mass

Domínguez Cañete, JJ.[1], Sáez García, MA.[2], Alpuente Román, JC.[3], Sevillano Sánchez, M.[4], Rueda Correa, F.[1] y Yuste García, V.[1]

Sanid. mil. 2019; 75 (4): 226-227, ISSN: 1887-8571

KEY WORDS: Solitary fibrous tumor; inguinal mass; paratesticular; spermatic cord.

CASE REPORT:

We present the case of a seventy-two-year-old male patient, smoker, who developed a poorly differentiated carcinoma in the oral cavity that was treated with radiotherapy and followed by psychiatry due to depression and suicidal ideation, three years before the current diagnosis.

Currently, the patient shows an inguinal mass with two months of evolution, with rapid growth and indolent course. The therapeutic decision is to perform radical orchiectomy, including excision of spermatic cord. We can see in the image an ovoid mass of 12x7x6 cm and 440 g (Figure 1) and histological section with 200x magnification power and hematoxylin and eosin stain (Figure 2).

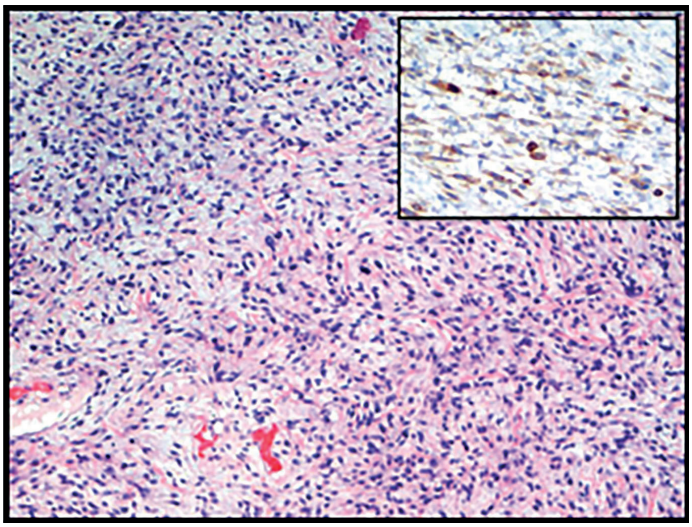

[1].Servicio de Anatomía Patológica.
[2]. Teniente Coronel Médico Jefe Servicio de Anatomía Patológica.
[3]. Servicio de Urología.
[4]. Capitán Médico. Servicio de Urología.
1,2,3 y 4. Hospital Central de la Defensa. Madrid

Correspondencia:
Juan José Domínguez Cañete
Glorieta del Ejercito 1, Servicio de Anatomía Patológica, 28047 (Madrid)
Email: jdomca5@mde.es / jjdcanete@gmail.com
Móvil: 658378152

Recibido: 25 de junio de 2019
Aceptado: 2 de diciembre de 2019

Doi: 10.4321/S1887-85712019000400009

Diagnosis: Solitary fibrous tumor

The anatomopathological diagnosis was Solitary fibrous tumor (SFT) grade 1 of FNCLCC (Fédération Nationale des centres de Lutte Contre le cáncer). American Joint Committee on Cancer (AJCC) 8 th Edition TNM stage: pT2.

SFT is a mesenchymal neoplasm and it was first reported in 1931 as a tumor of the pleura[1]. SFTs are uncommon that can appear in all sites of body. It represents 5% of soft tissue tumors and only 2% is extrathoracic. The incidence of paratesticular is low[2] with 22 cases are reported in the literature[3]. Most neoplasm has occurred in male with ranges 42 to 67 years old, without predisposing factors, although some papers have associated it with trauma and IgG4 diseases. Typically, it containing a specific NAB2-STAT6 gene fusion and overexpressing STAT6[4].

Macroscopically, the lesion shows a fibroelastic consistency and a shiny surface. The cutting surface has whorled pattern and yellowish pearly (Figure 1).

Microscopically, the tumor is composed by heterogeneous areas settled by a population of spindled cells arranged in fascicles or patternless, with an underlying collagen-dense stroma, showing focal hemangiopericytoma-like changes (Figure 2).

Immunohistochemically the tumor shows CD34, CD99 and Bcl-2 immunoreactivity (Figure 2, Bcl-2 upper right), in a diffuse and strong pattern. The lesion is negative for epithelial marker (CKAE1/AE3), lymphoid (CD45) and melanic (HMB-45). The cells do not reactivity for SMA, C-Kit, Inhibin, S-100, PLAP, D2-40, CD31, WT-1 and Calretinin. Proliferation index, labelled by ki67 stain, shows a 5-20% rate.

Regarding the behavior of this neoplasm, it has been reported that 10 to 15% of extrathoracic SFT will recurs or metastasizes, so that strict surveillance is obliged[5].

The differential diagnosis will include entities such as leiomyosarcoma, a relatively common mesenchymal tumor in this area, whose origin is smooth muscle. This neoplasm shows a similar histological pattern, but the immunohistochemical profile includes reactivity for smooth muscle actin and negativity for CD99 and Bcl-2[6]. Others differential diagnoses will be neural tumors such as neurofibromas (S-100 positive) and vascular lesions (CD31 or D2-40 positive).

BIBLIOGRAPHY

1. Klemperer P, Rabin CB. Primary neoplasms of the pleura: a report of five cases. Arch Pathol 1931; 11: 385-412.
2. Yihong Zhou, Guanghui Gong, Yuxin Tang, Jin Tang1, Yu Gan, Yingbo Dai. Paratesticular solitary fibrous tumor: a case report and review of literature. Int J Clin Exp Pathol 2015;8(3):3358-3361.
3. Christopher P. Marquez, Haiyan Zhang, Jason Goodrum, J. Nicholas Sreshta and Marjan Afrouzian. Florid Proliferation of Hyalinized Vessels in a Spermatic Cord STAT6 Positive Solitary Fibrous Tumor and Its Potential Clinical Implications. Case Reports in Pathology Volume 2018, Article ID 7462032, 6 pages.
4. Chmielecki J, Crago AM, Rosenberg M, et al. Whole-exome sequencing identifies a recurrent NAB2-STAT6 fusion in solitary fibrous tumors. *Nat Genet*. 2013;45(2):131–132.
5. Gold JS, Antonescu CR, Hajdu C, Ferrone CR, Hussain M, Lewis JJ, Brennan MF, Coit DG. Clinicopathologic correlates of solitary fibrous tumors. Cancer 2002; 94: 1057-1068.
6. Mohamad Moussa and Mohamed Abou Chakra Leiomyosarcoma of the spermatic cord: A case report and literature review. Int J Surg Case Rep 2019; 57: 175–178.