ISSN (electrónico): 1695-2987 - ISSN (papel): 0003-3170

Angiología

Nota Técnica

Iliac conduit for endovascular treatment without distal anastomosis: a simplified approach for endovascular access

Realización de un conducto ilíaco sin anastomosis distal para procedimientos endovasculares: una manera corta de hacer un conducto ilíaco para procedimientos endovasculares

René Romero Sarmiento, Rubén Castilla, Manuel Santiago, Víctor Martínez, Ignacio Michel, José A. González-Fajardo

Angiology Vascular Surgery and Endovascular Department. Hospital Universitario 12 de Octubre. Madrid, Spain

Abstract

The iliac conduit technique without distal anastomosis has emerged as an effective solution for managing challenging vascular access during complex endovascular procedures, particularly in patients with small, calcified, or diseased femoral arteries. This article discusses the clinical indications, advantages, and key surgical steps for a simplified approach to perform iliac conduit procedures easy, quick and safe.

Keywords:
Iliac. Conduit. Endovascular. Distal. Anastomosis.

Resumen

La técnica del conducto ilíaco sin anastomosis distal ha surgido como una solución eficaz para el manejo de accesos vasculares difíciles durante procedimientos endovasculares complejos, en particular en pacientes con arterias femorales pequeñas, calcificadas o enfermas. En este artículo se analizan las indicaciones clínicas, las ventajas y los pasos quirúrgicos claves para realizar un procedimiento que nos permita tener un buen acceso ilíaco de manera fácil, rápida y segura.

Palabras clave:
Ilíaco. Conducto. Endovascular. Distal. Anastomosis.

Received: 01/13/2025 • Accepted: 01/13/2025

Conflicts of interest: The authors declared no conflicts of interest.

Artificial intelligence: The authors declare that they have not used artificial intelligence (AI) or any AI-based tool for writing this article.

Romero Sarmiento R, Castilla R, Santiago M, Martínez V, Michel I, González-Fajardo JA. Iliac conduit for endovascular treatment without distal anastomosis: a simplified approach for endovascular access. Angiología 2025;77(2):123-126

DOI: http://dx.doi.org/10.20960/angiologia.00728

Correspondence:

René Romero Sarmiento. Angiology, Vascular Surgery and Endovascular Department. Hospital Universitario 12 de Octubre. Avda. de Córdoba, s/n. 28041 Madrid, Spain
e-mail: reneromero1991@hotmail.com

©Copyright 2025 SEACV y ©Arán Ediciones S.L. Este es un artículo Open Access bajo la licencia CC BY-NC-SA (http://creativecommons.org/licenses/by-nc-sa/4.0/).

INTRODUCTION

Endovascular techniques, such as endovascular aneurysm repair (EVAR) and thoracic endovascular aortic repair (TEVAR), often require large-bore vascular access. In patients with small, calcified, or diseased femoral arteries, traditional femoral access becomes infeasible. In these cases, the iliac conduit offers a viable alternative. The modification of omitting the distal anastomosis in the first stage simplifies the procedure further and ensures a safer, faster approach with improved outcomes. We describe this technique to optimize the approach for challenging vascular access.

INDICATIONS

The iliac conduit technique is indicated when the native iliac artery cannot accommodate the endovascular device due to size, calcification, or stenosis. Common clinical scenarios include:

1. Large-bore prosthesis requirements in EVAR or TEVAR procedures.
2. Aortoiliac occlusive disease with infeasible traditional accesses.
3. Hostile groin anatomy, such as prior surgical procedures, radiation damage, or extensive scar tissue.

Avoiding the femoral artery, this approach mitigates complications in patients at higher surgical risk.

ADVANTAGES OF THE ILIAC CONDUIT WITHOUT DISTAL ANASTOMOSIS

The iliac conduit without distal anastomosis, performed as a first step, offers several significant advantages over traditional femoral access or standard iliac conduit procedures:

1. *Reduced Operative Time:* omitting distal anastomosis eliminates the need for extensive suturing, streamlining the surgical process.
2. *Avoidance of Groin Incision and Dissection:* by not accessing the femoral artery, the groin remains untouched, thus reducing the risk of surgical site infections, particularly in high-risk patients.
3. *Simplified Access for Future Interventions:* if any re-interventions were required, the iliac conduit can be ligated distally and advanced to the inguinal ligament, which facilitates further endovascular access through a simple groin incision.
4. *Lower Risk of Complications:* by reducing the operative exposure and bypassing the femoral artery, the likelihood of hematoma, infection, and groin wound complications is minimized.

SURGICAL TECHNIQUE

A/ First stage

1. *Preoperative Planning:* Preoperative imaging modalities (CCTA) are essential to assess the iliac anatomy, vessel caliber and disease. The appropriate conduit material needs to be properly selected as well. (Dacron 10 mm).
2. *Exposure of the Common Iliac Artery:* We perform a standard retroperitoneal approach to expose the common iliac artery with careful dissection to further minimize injury to surrounding structures.
3. *Proximal Anastomosis:* After systemic heparinization and clamping, an end-to-side anastomosis of the conduit to the common iliac artery should be performed. This is the only anastomosis required (Fig. 1).

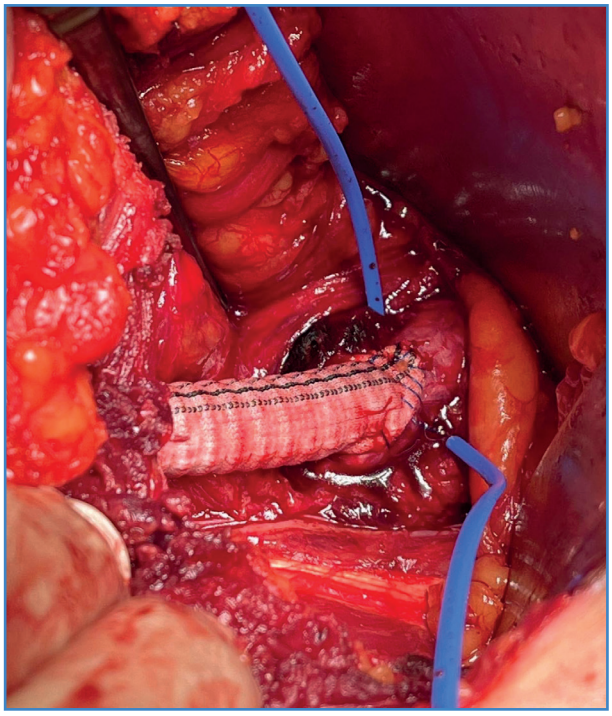

Figure 1. *Proximal common iliac anastomosis by retroperitoneal approach.*

4. *Place the conduit subcutaneously at inguinal level:* The conduit is placed subcutaneously and at inguinal level to ensure hemostasia and patency. Finally, the end is ligated and sutured (prolene 5/0) to prevent bleeding (Fig. 2).

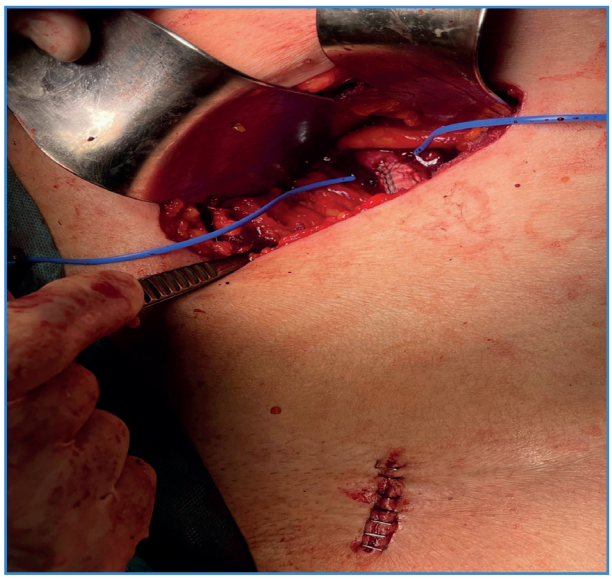

Figure 2. *The Conduit is placed subcutaneously at the inguinal level by a small access.*

B/ Second stage

1. *Conduit Management:* Several days later, we look for the prothesis subcutaneously at inguinal level. It is easy because it has not been yet integrated. Logically, the conduit is thrombosed, but via manual thrombectomy with a Fogarty catheter the prothesis is reopened, and can be used as an access point to introduce endovascular devices (Fig. 3).

After finishing the procedure, the conduit is again distally ligated, sutured and placed subcutaneously. Finally, the wound is closed.

DISCUSSION

The iliac conduit without distal anastomosis provides a safe and effective alternative for patients requiring large-bore vascular accessess while presenting complex anatomies or significant comorbidities. This change reduces procedural time, avoids unnecessary groin complications, and streamlines management of future interventions.

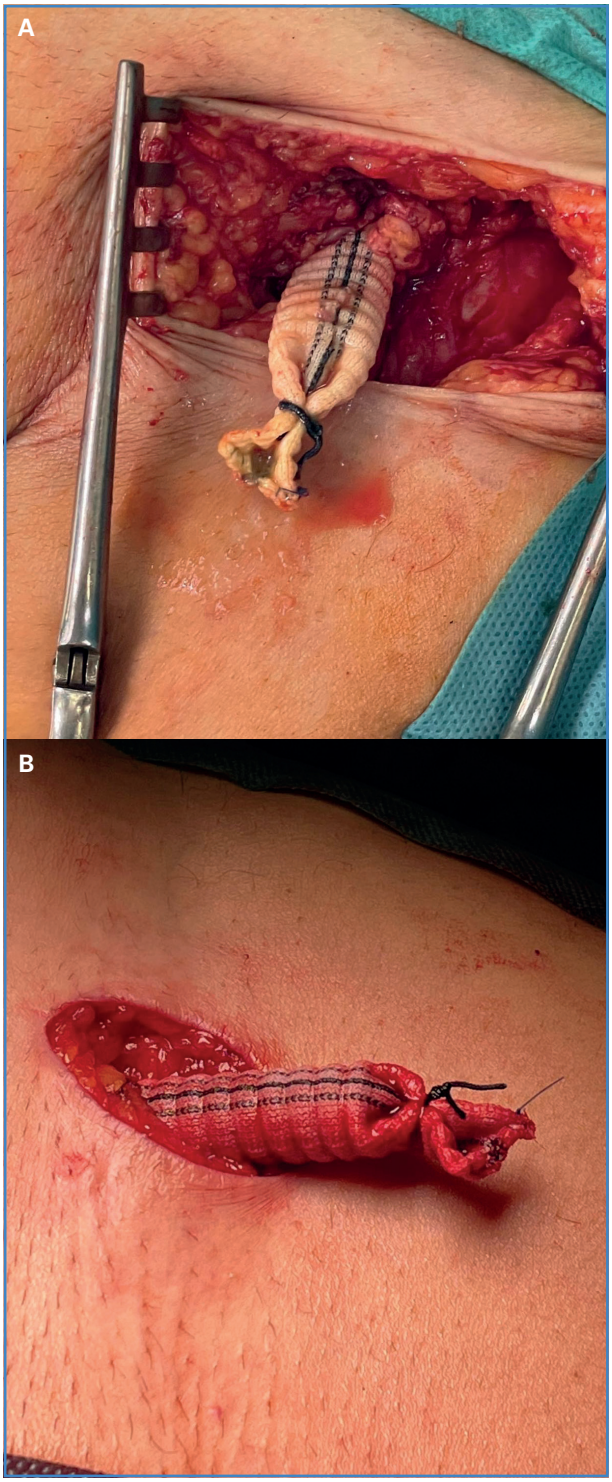

Figure 3. *A. Several days afterwards, the conduit is localized in the inguinal area previously treated. B. By manual thrombectomy with a Fogarty catheter the prothesis is re-opened.*

Our experience has demonstrated favorable outcomes with this approach, particularly in high-risk patients undergoing EVAR and TEVAR.

CONCLUSIONS

The iliac conduit without distal anastomosis as the index step is a significant advancement in endovascular treatment, particularly for patients with limited vascular access options. By simplifying the conduit creation process and eliminating the need for extensive distal suturing, this technique improves procedural efficacy, reduces procedural risk, and enhances patient outcomes.

Further studies and long-term follow-up data will continue to validate its role in contemporary vascular surgery.

REFERENCES

1. Chaudhuri A, Ark R. Innovations in Vascular Access: Iliac Conduit Techniques. Seminars Vasc Surg 2019;32(2):91-7.
2. Kouvelos GN, Koutsoumpelis A, Matsagkas M. Outcomes of Iliac Conduit Placement in EVAR. Ann Vasc Surg 2020;67:10-8.
3. Oderich GS, Ribeiro M, Hofer J. Techniques for Iliac Conduits in Endovascular Repair. J Vasc Surg 2017;66(3):835-44.
4. Veith FJ, et al. Optimizing Access for Complex EVAR Procedures: Iliac Conduits. Eur J Vasc Endovasc Surg 2018;55(4):537-45.