

OPTIC NERVE GLIOMA IN A CASE OF NEUROFIBROMATOSIS-1 IN A CHILD

GLIOMA DE NERVIÓ ÓPTICO EN UN CASO DE NEUROFIBROMATOSIS-1 INFANTIL

AGUIRRE-BALSALOBRE FE¹, COLOMA-GONZÁLEZ IT¹, MENGUAL-VERDÚ EN²

ABSTRACT

Clinical case: The case of a three-year-old patient with neurofibromatosis type I is presented. Ophthalmologic evaluation revealed, by means of magnetic resonance imaging, the presence of a silent glioma in the optic nerve of the left eye.

Discussion: Neurofibromatosis-1 can present in multiple ways to the ophthalmologist, with a glioma of the optic nerve being one of the most frequent central nervous system presentations in this illness. Generally the glioma affects the optic chiasm and its course is indolent, with conservative management and close monitoring usually being advised until progression is defined (*Arch Soc Esp Ophthalmol* 2006; 81: 33-36).

Key words: Optic nerve glioma, neurofibromatosis, magnetic resonance.

RESUMEN

Caso clínico: Se presenta el caso de una paciente de tres años de edad con neurofibromatosis tipo 1. La exploración oftalmológica reveló, mediante resonancia nuclear magnética, la presencia de un glioma de curso silente en el nervio óptico del ojo izquierdo.

Discusión: La neurofibromatosis-1 produce múltiples manifestaciones en el campo oftalmológico, siendo los gliomas de la vía óptica los tumores del sistema nervioso central más frecuentes en la enfermedad. Por lo general suelen afectar al quiasma y su curso suele ser indolente, aceptándose un tratamiento conservador con seguimiento estrecho hasta que se detecte progresión.

Palabras clave: Glioma de nervio óptico, neurofibromatosis, resonancia magnética.

Received: 25/4/05. Accepted: 12/1/06.

Hospital Universitario San Juan de Alicante. Alicante. Spain

¹ Graduate in Medicine.

² PhD. in Medicine.

Communication presented at the LXXX Congress of the S.E.O. (Córdoba 2004).

Correspondence:

F.E. Aguirre-Balsalobre

Servicio de Oftalmología

Hospital Universitario San Juan de Alicante

Ctra. Nnal. 332 Alicante-Valencia, s/n

Apartado de correos 41

03550 San Juan de Alicante (Alicante)

Spain

E-mail: faguirr88@hotmail.com

INTRODUCTION

Neurofibromatosis-1 is a hereditary dominant autosomal disease in 50-70% of cases. It produces an alteration of the growth of tissue derived from the neuroectoderm due to the mutation of a tumour-suppressing gene.

There are eight types of neurofibromatosis, the most common being type 1, or Von Recklinghausen disease and neurofibromatosis type 2.

Neurofibromatosis 1 is the most frequent type with a prevalence of 3,000-4,000. It is caused by an alteration in chromosome 17 and is usually diagnosed in childhood. The diagnostic criteria regards as a patient an individual presenting two or more of the following: a first degree relative with the disease, over four light brown spots, more than one neurofibroma (or one if plexiform), freckles in the armpit or groin, Lisch nodules, glioma of the optic nerve and scoliosis and/or deformation of bones (figs. 1 and 2).

Neurofibromatosis can cause the following eye conditions: optic nerve glioma (20%) and other neural tumours, Lisch nodules (fig. 3), nevus corioides, uvea ectropion, prominence of corneal nerves, sphenoorbital encephalocele, retinal astrocytomas, skin tumors in eyelids, hemiatrophy of the face and congenital glaucoma, which is unilateral and rare; the angle can be occluded by deve-

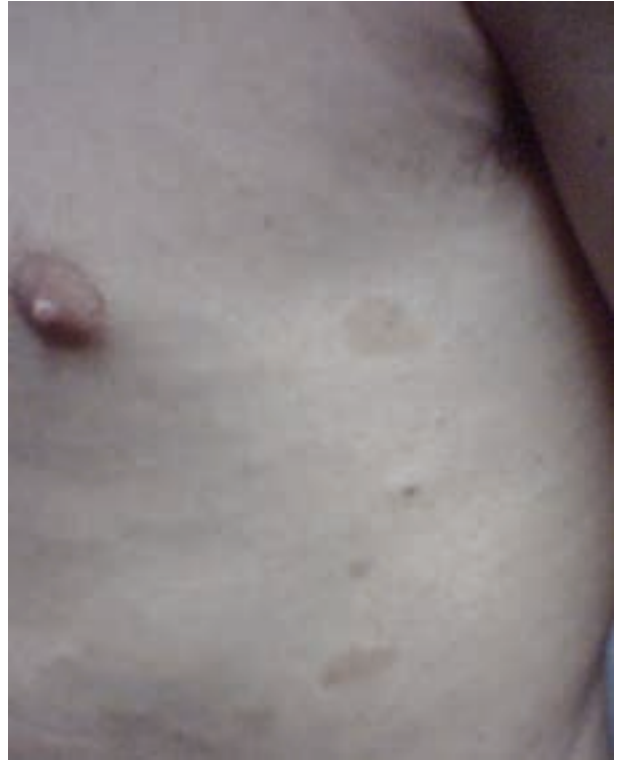

Fig. 2: Skin findings in a brother of the neurofibromatosis patient.

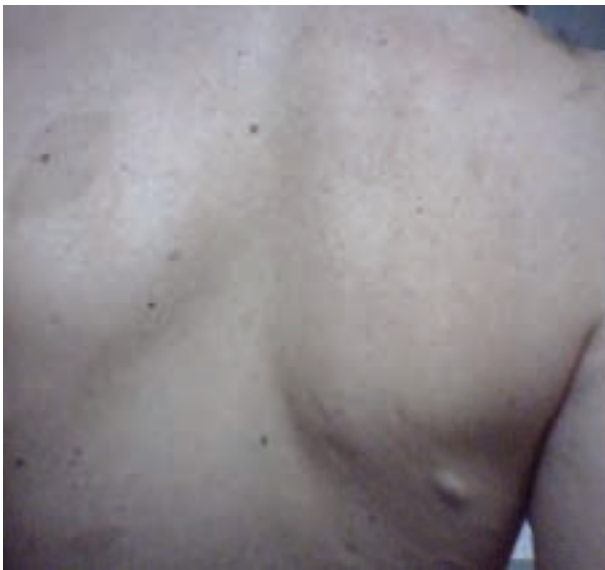

Fig. 1: Skin findings in a brother of the neurofibromatosis patient.



Fig. 3: Lisch nodules in a brother of the neurofibromatosis patient.

lopmental alterations and by anomalous tissue growth (1).

CASE REPORT

A three-year-old girl diagnosed a year earlier with neurofibromatosis type 1 by the Pediatric service. The patient was referred to ophthalmology for assessment in the context of screening other pathologies. For this reason, a cranium nuclear magnetic resonance (NMR) scan was also requested. At this time, the patient did not present any symptoms and the exploration was as follows: uncorrected visual acuity in the right eye of 0.9 and 1 in the left. Normal biomicroscopic exploration of the anterior segment and normal funduscopy in both eyes. Normal intraocular pressure in both eyes. Pressure in both eyes. External eye movements did not reveal pathological findings. No proptosis or exophthalmos. Isochoric and normo-reactive pupils.

The NMR study detected the presence of optic nerve glioma in the left eye (fig. 4).

It was decided not to treat but to follow up the patient with regular three-month checkups. In this follow-up we observed the progressive appearance of a slight proptosis and the vision of the patient went down to 0.9 in the left eye.

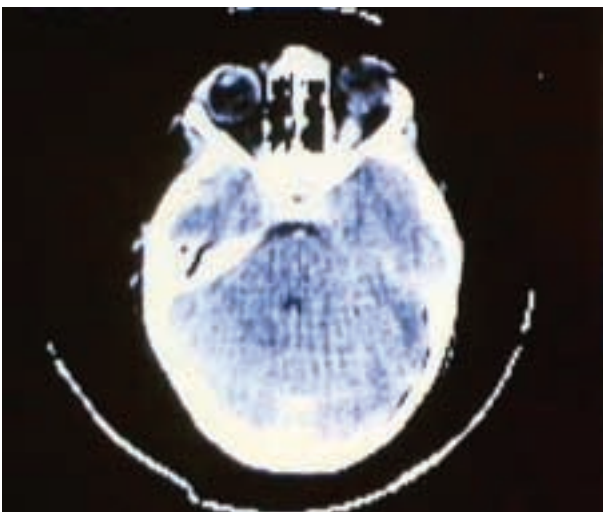


Fig. 4: NMR: the patient's optic nerve glioma.

DISCUSSION

The optic nerve gliomas in neurofibromatosis-1 are usually diagnosed before the fifth birthday (75%). It appears in 15 percent of patients with phacomatosis, but only one-third are symptomatic, most frequently being chiasmatic and low degree, usually pyloid (2); in fact, some remain stable for such a long time that many authors believe them to be hamartomae. They can produce reactive meningeal proliferations (3).

Said tumours can be expressed in the following ways: abnormal pupil function, reduction of visual acuity and vision of colors, optical atrophy without papiledema, deconjugated external eye movements, nystagmus, poor abduction or proptosis (3). They can also cause symptoms due to the involvement of non-visual structures, most frequently the hypothalamus. 25% of these tumors will cause aqueduct stenosis if allowed to progress.

In the typical MR image, the disease appears as an elongated mass in the optic nerve and/or chiasma, which becomes iso-intense in T^1 with hyperintense areas in T^2 . In addition, it presents enhancement to contrast. Frequently, the radio imaging techniques undervalue the true extension of the tumor (3). If the tumor presents intra-cranial or chiasmatic prolongation, the patient must be referred for puncture-aspiration with thin needle.

As regards the approach of the tumor, it can be said that in general (if there is no involvement) observation can be considered with half-yearly checkups and an annual neuroimage (3). This is because some regress spontaneously (4). If symptoms appear or the neuroimage shows progression (5), (normally an invasion of the chiasm), other therapeutic inter-disciplinary options should be considered. In general, surgery is preferred (trans-cranial orbitotomy) (3), because neither chemo- or radio-therapy have proved superior efficiency. In any case, there is no consensus for treatment.

To end, we emphasize the high frequency of optic pathway gliomas in children with neurofibromatosis type 1, being tumors with good prognosis, better than in adults or subjects without the disease (5). Likewise, the role of the ophthalmologist also seems important because it is crucial in the initial assessment and follow-up. Treatment must be evaluated individually for each case.

REFERENCES

1. Kanski JJ. *Oftalmología clínica*. Madrid: Ediciones Harcourt, S.A.; 200: 563-566.
2. Kornreich L, Blaser S, Schwarz M, Shuper A, Vishne TH, Cohen I et al. Optic pathway glioma: correlation of imaging findings with the presence of neurofibromatosis. *AJNR Am J Neuroradiol* 2001; 22: 1963-1969.
3. Arruga J, Martínez J. Tumores compresiones e infiltraciones del nervio óptico: Tumores primarios del nervio óptico. In: Arruga Ginebreda J, Sánchez Dalmau B. *Neuropatías ópticas: diagnóstico y tratamiento*. Madrid: Sociedad Española de Oftalmología 2002; 239-262.
4. Parazzini C, Triulzi F, Bianchini E, Agnetti V, Conti M, Zanolini C et al. Spontaneous involution of optic pathway lesions in neurofibromatosis type 1: serial contrast MR evaluation. *AJNR Am J Neuroradiol* 1995; 16: 1711-1718.
5. Chateil J, Sousotte C, Pedespan J, Brun M, Manh C, Diard F. MRI and clinical differences between optic pathway tumours in children with and without neurofibromatosis. *Br J Radiol* 2001; 74: 24-31.