

OPTIC NEURITIS AFTER MENINGOCOCCAL VACCINATION

NEURITIS ÓPTICA TRAS VACUNACIÓN DE MENINGITIS

LARIA C¹, ALIÓ J¹, RODRÍGUEZ JL³, SÁNCHEZ J², GALAL A¹

ABSTRACT

Case report: We report the case of a 13 year-old male with bilateral optic neuritis after meningococcal C vaccination. He was treated with intravenous corticosteroids, but only showed visual recovery in one eye. A significant limitation of his sharp vision remained in his other eye.

Discussion: There have been no previously reported cases of optic neuritis after meningococcal C vaccination and for this reason we have reported this case. It is not possible, however, to exclude some other factor in the etiology of the optic neuritis, but the temporal relationship between the neuritis and the vaccination suggests this was the cause (*Arch Soc Esp Ophthalmol 2006; 81: 479-482*).

Key words: Optic neuritis after vaccination, meningitis, meningococcal C vaccination.

RESUMEN

Caso clínico: Se presenta el caso de un varón de 13 años que tras vacunación de meningitis, presenta una neuritis óptica bilateral, siendo tratado con terapia intravenosa de corticoides, pero presentando sólo recuperación de visión en uno de los ojos, quedando una importante limitación de su agudeza visual en el ojo derecho.

Discusión: No existen referencias de neuritis óptica postvacunales en el caso de la vacuna para el meningococo, de ahí la importancia de tener conocimiento de ello, si bien no se puede descartar la posible existencia de una relación únicamente temporal entre la neuritis y el proceso vacunal.

Palabras clave: Neuritis óptica postvacunal, meningitis meningococo C, neuritis, vacunación meningitis.

INTRODUCTION

Two types of vaccine for meningitis are distributed in Spain: A) Bivalent vaccines which include non-conjugated purified capsular bacterial polysaccharides of serogroups A and C of *Neisseria meningitidis*, and B) Conjugated vaccines vis-à-vis *Neisseria meningitidis*, C serotype, by conjugation of the oligosaccharide of the *Neisseria meningitidis*

capsule through covalent link with a carrier protein (diphtheria or tetanus toxoid) for increasing the immunogenic capacity of the vaccine.

Optic neuritis (ON) can leave important visual sequels because many of these processes can be bilateral. Within etiological diagnosis there is a group of ON called post-vaccine (1) which occur in the presence of diverse viral and bacterial agents (2,3).

Received: 2/1/06. Accepted: 25/7/06.

VISSUM. Ophthalmological Institute of Alicante, Alicante. Spain.

¹ Ph.D. in Medicine. Ophthalmologist. Ophthalmological Institute of Alicante. VISSUM, Alicante. Spain.

² Ph.D. in Medicine. Pediatrician. Porriño Health Centre. Pontevedra. Spain.

³ Graduate in Medicine.

Correspondence:

C. Laria Ochaíta VISSUM.
Instituto Oftalmológico de Alicante
Avda. de Denia, s/n.
03015 Alicante
Spain
E-mail: Laria@arsystel.com

CASE REPORT

A 13-year old male patient with pain in the right eye during ocular movements, 24 hours evolution, accompanied by loss of vision in both eyes. He did not refer relevant personal or allergic history and said he had received 18 days ago the meningitis conjugated vaccine (Neisvac-C®), made up by oligosaccharid of the Neisseria meningitidis C capsule (10 mg) conjugated with covalent link to a carrier protein (Tetanus toxoid 10-20 mg).

The exploration revealed a finger-counting VA in the right eye and 0,05 in the left one, as well as bilateral midriasis with relative afferent pupil defect. Anterior segment biomicroscopy and tonometry gave normal results, whereas the eye fundus study revealed bilateral blurriness of papillary margins.

Supplementary explorations were made as follows:

- Analyses: Biochemistry, hemogramme, sedimentation speed, coagulation, thyroid stimulating hormone, anti-ENAs, C reactive protein, C3 and C4 fractions: normal or negative. Quantification of

immunoglobulines: low immunoglobulin A. Negative serology for lues, brucella and borrelia.

- Lumbar Punction: basic cerebrospinal liquid normal, without oligoclonal bands, with negative serology for lues, brucella and Epstein Barr.
- Cranial CAT scan: Normal.
- Cerebrum NMR: Suggestive of right optic neuritis, rest normal.

Diagnosed with optic neuritis, the patient was treated with methylprednisolone 1 g/day IV for 5 days, and subsequently changing the dosage to oral 40mg prednisolone/day, reducing to 5 mg each day up to termination (4).

After 2 months there was no evidence of improvement in the patient's VA which remained at 1/10 in the right eye and 9/10 in the LE. Campimetry (fig. 1) revealed bilateral involvement, more severe in the right eye (DM -17,62 dB. P<0,5%) than in the left one (DM -7,52 db. P<0,5%).

After 5 months the patient exhibited a VA of 4/10 and 9/10 in RE/LE, with normal pupil reflexes in both eyes. A pupilometry was performed which did not reveal significant alterations (6,7/6,8 mm RE/LE scotopic; 6,0/6,3 mm RE/LE high mesopic and 4,9/5,1 mm RE/LE low mesopic). The visual field showed improvements in both eyes (fig. 2) (RE DM -5,81 dB. P<0,5% and LE DM -3,70 db. P<0,5%). Contrast sensitivity (fig. 3) evidenced greater involvement of the RE. Persistent slight overall papillary paleness, greater at the temporal level (figs. 4 and 5).

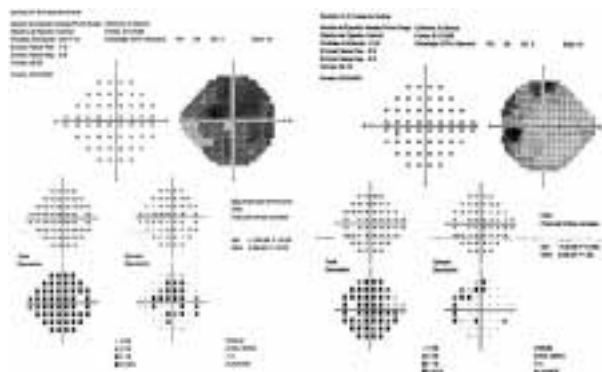


Fig. 1: visual fields (2 months after vaccination).




Fig. 2: Visual field (5 months post-vaccination).

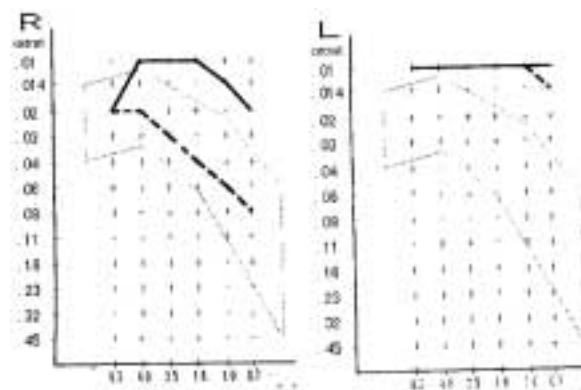


Fig. 3: Contrast sensitivity (5 months post-vaccination).

DISCUSSION

There are multiple references concerning the administration of vaccines against a number of viral

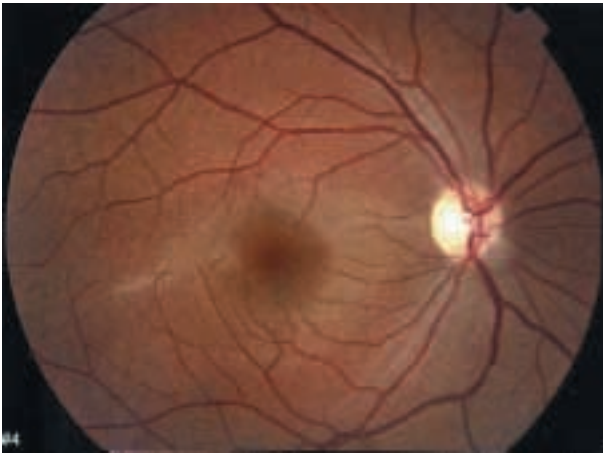


Fig. 4: Eye fundus (RE; 5 months post-vaccination).

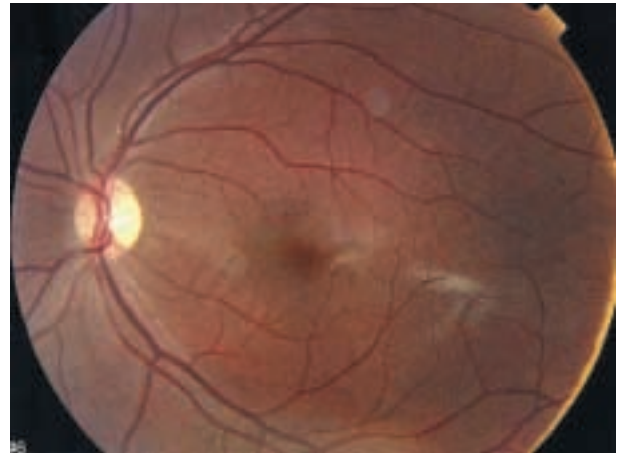


Fig. 5: Eye fundus (LE; 5 months post-vaccination).

and bacterial agents (2,3) and their possible relationship with optic neuritis. However, we haven't found any reference to the meningitis meningococcus vaccine, which enhances the importance of the issue. This case concerns a vaccine conjugated with tetanus toxoid, which could be key in the genesis of neuritis in case there is a relationship with the vaccine because the meningococcus C components or the tetanus toxoid could be responsible for the optical involvement. In fact, there are references by other authors relating vaccination against tetanus with the emergence of neuritis, although these involve combined vaccines for tetanus/diphtheria/polio-mielitis and smallpox/diphtheria/tetanus. The fact that to date we haven't found descriptions of optic neuritis associated to other meningitis vaccines (5) supports the possible involvement of the tetanus toxoid in its emergence.

It cannot be stated conclusively that neuritis is due to the effects of the vaccine or that, on the contrary, there only is a causal relationship in the course of time. There is a wide range of time elapsed between the administration of the various vaccines and the development of optic neuritis symptoms, between 5 days to 3 weeks.

In what concerns symptoms, we cannot state that the existence of pain, the degree of loss of eyesight, age or mono/binocularity of the process is the initial

associated symptom because the appearance of these symptoms varies vis-à-vis different vaccines.

Considering the above, we conclude that the appearance of optic neuritis in relation to different vaccines may not be frequent but is cause for concern due to the important visual impact of the process and the high frequency of administration of meningitis vaccines in vaccination calendars.

REFERENCES

1. Savino PJ, Carmona O, Arbizu T, Arruga J, Sánchez Dalmau B, Vidaller A, et al. Neuritis Óptica. In: Arruga Ginebreda J, Sánchez Dalmau B. *Neuropatías ópticas: Diagnóstico y tratamiento*. Madrid: Sociedad Española de Oftalmología; 2002; 175-206.
2. Esmaeli-Gutstein B, Winkelman JZ. Uveitis associated with varicella virus vaccine. *Am J Ophthalmol* 1999; 127: 733-734.
3. Kerrison JB, Lounsbury D, Thirkill CE, Lane G, Schatz MP, Engler RM. Optic neuritis after anthrax vaccination. *Ophthalmology* 2002; 109: 99-104.
4. Beck RW, Bhatti MT, Brodsky MC, Buckley EG, Chrousos GA, Carbett J, et al. Visual function: more than 10 years after optic neuritis: experience of the optic neuritis treatment trial. *Am J Ophthalmol* 2004; 137: 77-83.
5. Cuevas IE, Cruz G, Rosete LE, Casanueva V, Castañeda I, Pérez J. Eventos adversos temporalmente asociados a VA-MENGOC-BC®. *Municipio La Lisa, 1998-1999. Vac-Monitor* 2000; 9: 1-9.