

CLINICAL NOTE

## Solid pseudopapillary tumor of the pancreas (SPPT). Still an unsolved enigma

J. A.-Cienfuegos<sup>1</sup>, M. D. Lozano<sup>2</sup>, F. Rotellar<sup>1</sup>, P. Martí<sup>1</sup>, N. Pedano<sup>1</sup>, J. Arredondo<sup>1</sup>, M. Bellver<sup>1</sup>,  
J. J. Sola<sup>2</sup> and F. Pardo<sup>1</sup>

<sup>1</sup>Department of General Surgery. <sup>2</sup>Pathology Department. Clínica Universidad de Navarra. Pamplona, Spain

### ABSTRACT

Solid pseudo-papillary tumor (SPPT) is a rare cystic tumor of the pancreas (1-3% of exocrine tumors of the pancreas) which shows an "enigmatic" behavior on the clinical and molecular pattern. A retrospective analysis of the citological studies and resected specimens of pancreatic cystic tumors from May 1996 to February 2010 was carried out. Three cases of SPPT were found, which are the objective of this study. The diagnosis was established upon occasional finding in the abdominal CT, in spite of sizing between 3 and 6 cm of diameter. In the three cases the pre-operative diagnosis was confirmed by cytology and specific immunohistochemical staining. Cases 2 and 3 showed strong immunoreactivity for Beta-Catenina and E-Cadherina staining. Radical resection (R0) was carried out in the three cases. A young male -21 years of age (case 1)- who had duodenal infiltration and two lymph nodes metastases died of hepatic and peritoneal recurrence 20 months following surgery. The other two cases are free of disease. The current review of the literature reports roughly 800 cases since the first report in 1959, and shows the enigmatic character of this tumor regarding the cellular origin, molecular pathways, prognostic factors and clinical behavior.

**Key words:** Solid-pseudopapillary tumor. Pancreatic cystic neoplasm. Prognosis. Beta-catenina.

### RESUMEN

El tumor pseudopapilar (TSPP) es un tumor quístico del páncreas muy poco frecuente (1-3% de los tumores exocrinos del páncreas) y que tiene un comportamiento oncológico y molecular "enigmático". Se realizó un análisis retrospectivo de las citologías de las lesiones quísticas del páncreas, así como de los tumores quísticos resecaados entre mayo de 1996 y febrero de 2010, encontrándose tres tumores SSPP, motivo de este estudio. En los

tres casos el diagnóstico fue ocasional en el TC abdominal a pesar de presentar unos tamaños entre 3 y 6 cm de diámetro. En los tres casos se confirmó el diagnóstico preoperatorio mediante citología e inmunohistoquímica. En los casos 2 y 3 se confirmó la positividad para Beta-Catenina y E-Cadherina. En todos los casos se realizó cirugía radical (R0). Un varón de 21 años -caso 1- que presentaba infiltración duodenal y metástasis ganglionares falleció de progresión hepática y peritoneal a los veinte meses de la cirugía. Las otras dos pacientes -casos 2 y 3- se encuentran libres de recidiva. La revisión de la literatura desde su descripción en 1959 hasta la actualidad -aproximadamente 800 casos- confirma el carácter enigmático de este tumor en relación a su origen celular, molecular, factores pronósticos y comportamiento clínico.

**Palabras clave:** Tumor sólido-pseudopapilar, Tumores quísticos de páncreas. Pronóstico.

A.-Cienfuegos J, Lozano MD, Rotellar F, Martí P, Pedano N, Arredondo J, Bellver M, Sola JJ, Pardo F. Solid pseudopapillary tumor of the pancreas (SPPT). Still an unsolved enigma. *Rev Esp Enferm Dig* 2010; 102: 722-728.

### INTRODUCTION

The solid pseudopapillary tumor (SPPT) of the pancreas was first described by Franz in 1959 and characterized by Hamoudi in 1970, resulted in either "Franz" or "Hamoudi" tumors (1,2). It is an uncommon pancreatic cystic tumor (1-3% of exocrine pancreas neoplasms) which shows an enigmatic pattern from oncological and molecular perspectives. Long-term survival superior to 10-12 years have been reported in spite of vascular invasion and peritoneal or hepatic involvement (3-5). The SPPT usually has a benign evolution affecting young females (2<sup>nd</sup>-3<sup>rd</sup> decade), having related with sex hormones etiology although this hypothesis has not been confirmed. Some authors have reported a more aggressive evolution in young males (6-8).

Received: 02-03-10.  
Accepted: 15-04-10.

Correspondence: Javier A.-Cienfuegos. Departamento de Cirugía General. Clínica Universidad de Navarra. Av. Pío XII, nº 36. 31008 Pamplona, Spain. e-mail: fjacien@unav.es

Its biological and clinical pattern differs from the rest of the cystic neoplasms of the pancreas, which have aroused a great interest in the last decade (9-11). Since 1933, 718 cases have been described until 2005 and currently around 800 cases have been reported (10-17).

We present three cases of SPPT with different clinical features and outcomes, which confirm the “enigmatic” characteristics of this tumor which has been occasion of an editorial in this journal in 2006 (9).

## PATIENTS AND METHODS

Between October 1996 and February 2010, 118 cytologic studies of cystic lesions of the pancreas were performed in our Institution. Most of them were obtained by fine-needle aspiration (FNA) during computerized tomography (CT) or upper endoscopic ultrasound (EUS) procedure. In October 2006 the brush cytology technique was introduced (Echobrus Cook Medical, Winston-Salem, North Carolina, USA). A retrospective analysis of the clinical, surgical and cytopathological parameters of the cystic tumors diagnosed according with the 1996 World Health Organization (WHO) guidelines and reviewed in 2000 was performed (18,19). Three cases of SPPT were diagnosed in that period.

Case 1. A 17 year-old male with previous history of duodenal ulcer, presented a great ulcer and deformation of duodenal wall in a routine endoscopy. An abdominal CT and magnetic resonance imaging (MRI) showed a great solid-cystic lesion in the head of the pancreas. The FNA cytology reported an “epithelial malignant tumor”. The patient was referred to our Center. On admission, the blood analysis showed: Hb. 9.3 g/dL; Hto. 27.5%; Iron: 11 µg/mL. Total Bilirubin: 4.54 mg/dL; Gastrin 101 pg/mL (normal values < 150 pg/mL) and CA-19.9: 11.3 U/mL.

In the abdominal CT a 6 cm diameter tumor in the head of the pancreas was assessed, with compression on the duodenal wall and impingement of the mesenteric vein and celiac axis as well. The FNA cytology was informed as “solid-pseudopapilar neoplasm” with pseudopapillary pattern.

The patient underwent a total pancreatectomy due to global involvement of the pancreatic gland by a solid-cystic tumor without infiltration of the mesenteric vessels. The patient was reoperated at the 11th postoperative day for a gastrojejunal dehiscence and was discharged on the 20<sup>th</sup> postoperative day. The gross description reported a solid mass of 6.5 cm diameter which involved whole gland with intraluminal invasion and multiple hemorrhagic cystic structures. The microscopic study described a neof ormation with papillary pattern alternating with microcystic areas. The tumor invaded the duodenal wall with negative surgical margins. Two of the lymph nodes were infiltrated. The patient was treated with adjuvant radiotherapy (51 Gy) and chemotherapy (Cisplatin, 5-FU)

and later on with Docetaxel and Gemcytabin (20). 14 months after operation a loco-regional recurrence and liver metastases were observed dying 20 months after surgical resection.

Case 2. An incidental 6 x 6.5 cm diameter cystic lesion located in the tail of the pancreas was discovered in asymptomatic 28 year-old female. The EUS confirmed the expansive pattern. The cytopathological study described several branch of papillary fronds, consisting of a central fibrovascular stalk covered with several layers of neoplastic cells compatible with SPPT. The patient underwent laparoscopic distal pancreatectomy without incidences and remains free of recurrence and symptoms 4 years after operation. The gross appearance revealed a well circumscribed solid-cystic lesion of 6.5 cm diameter, with multiple hemorrhagic and necrotic areas (Fig. 1-A). The microscopic study revealed an epithelioid neoplastic alternating solid pattern with cystic spaces and pseudopapillae formed by connective tissue stalks which delineated clusters of epithelioid cells. The surgical margins and lymph nodes were negative (Fig. 1-B).

The immunohistochemical study was positive for Vimentin,  $\alpha$ 1-antitrypsin (AAT), CD-10 and CD-56; and negative for cytokeratin-7, cytokeratin-19, synaptophysin and chromogranin A.

Case 3. A 24 year-old female who consults for a second opinion with the previous diagnosed of pancreatic cystoadenoma. She was diagnosed 8 years before with occasion of an incidental finding in an abdominal CT when the lesion measured 3 cm diameter size.

In posterior controls she remained asymptomatic although an increase of the lesion up to 4.5 cm diameter and portal vein compression was assessed when she decided to consult in our Department (Fig. 2).

The SPPT diagnosis was confirmed by EUS and FNA cytology. The immunohistochemical staining was positive for nuclear beta-catenin and cytoplasmatic CD-10 (Fig. 3). The patient underwent Whipple procedure and discharged on 5 postoperative day with regular diet. The gross study described a well circumscribed solid lesion of 3.5 x 3.5 x 4.5 cm size in the head of the pancreas which displaced the pancreatic parenchyma and obstructing the Wirsung duct (Fig. 4). In the microscopic study, an epithelioid neoplasia growing in cellular clusters delineated by connective tissue stalks with pseudopapillary structures.

The tumor was well circumscribed by a fibrous tissue band with surgical margins free of disease and negative nodes. The immunohistochemical study was positive for CD-10, nuclear and cytoplasmatic Beta-Catenin and for progesterone receptors (85%).

## DISCUSSION

The SPPT was first described by Franz in 1959 and posteriorly characterized by Hamoudi in 1970 (1, 2).

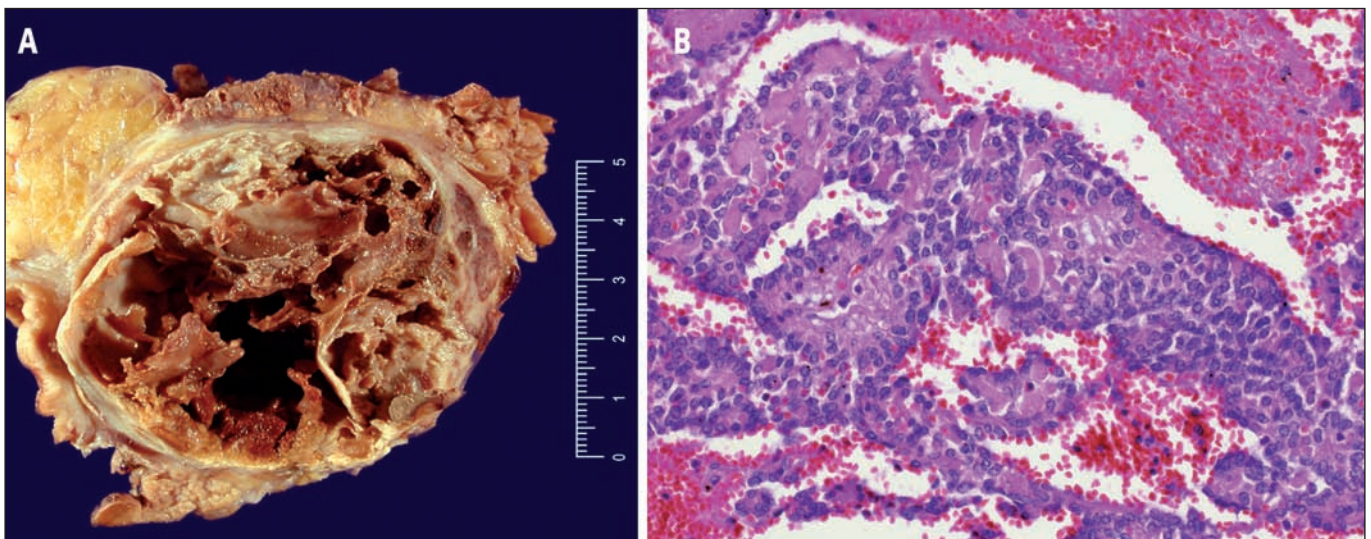


Fig. 1. A. Gross appearance of distal pancreatectomy specimen by SPPT (case 2) showing the solid and cystic component with hemorrhagic areas. B. Microscopic examination showing pseudopapillae (H & E x 400).

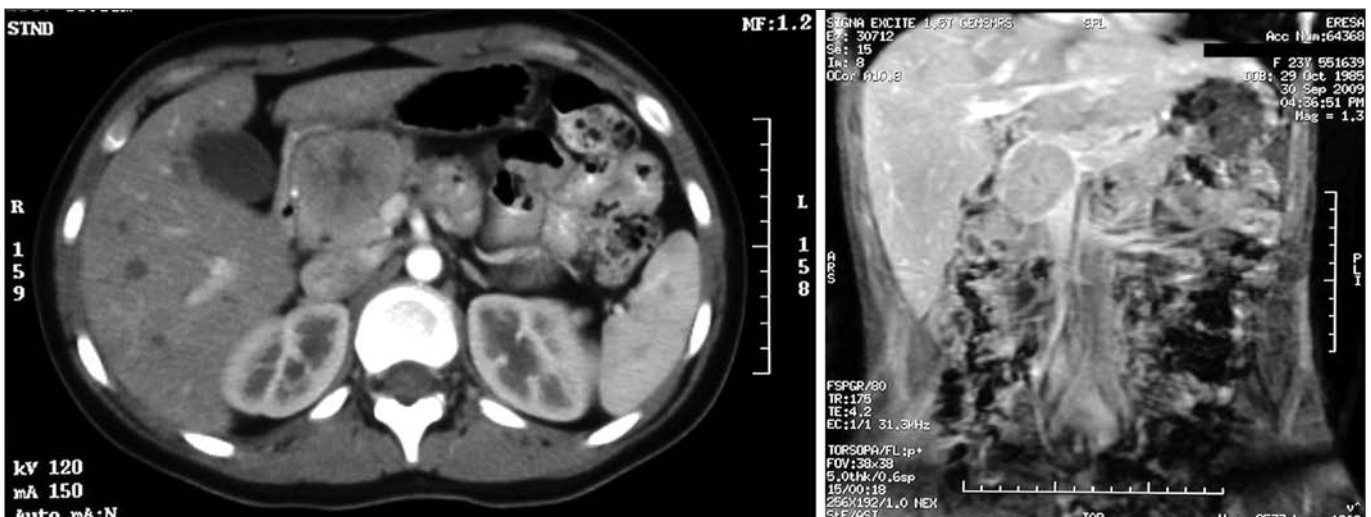


Fig. 2. Radiological imaging of case 3 on unenhanced CT and MR. A. A large well-encapsulated mass affecting the duodenum and portal vein. B. MR image reveals peripheral enhancement.

The tumor was denominated solid-pseudopapillary with occasion of the exocrine pancreas classification in 1996 (18). It is a rare tumor (1-3% of the exocrine neoplasms) which predominantly affects to young females between 20-30 years of age, and with an overall 5 years survival rate of 95-98% and 10 year of 93% respectively after surgery (12,22).

From the biological, molecular and oncological point of view, it represents an “enigmatic” tumor from which the origin, prognostic factors and natural history are unknown, having aroused a great interest and awareness in the last decades, when several clinical series and excellent reviews have been reported (4,8-11,13,15-17,22-26).

From the three presented cases, highlights the first one, the case of a 17 year-old boy whenever the prevalence in males is between 3.9% and 6.6% (12,22). Machado and cols. reported the tumor in 7 males in a case series of 34 patients. This author reported a more aggressive histological pattern in the males although not definitive prognostic factors were obtained due to the limited number of patients (8). Other authors have reported bigger and more solid tumors in males without differences in survival (6,7). Table I summarizes the anatomical and clinical features of the largest series.

In the previous mentioned patient, the clinical presentation and evolution after radical surgery (R0) was very

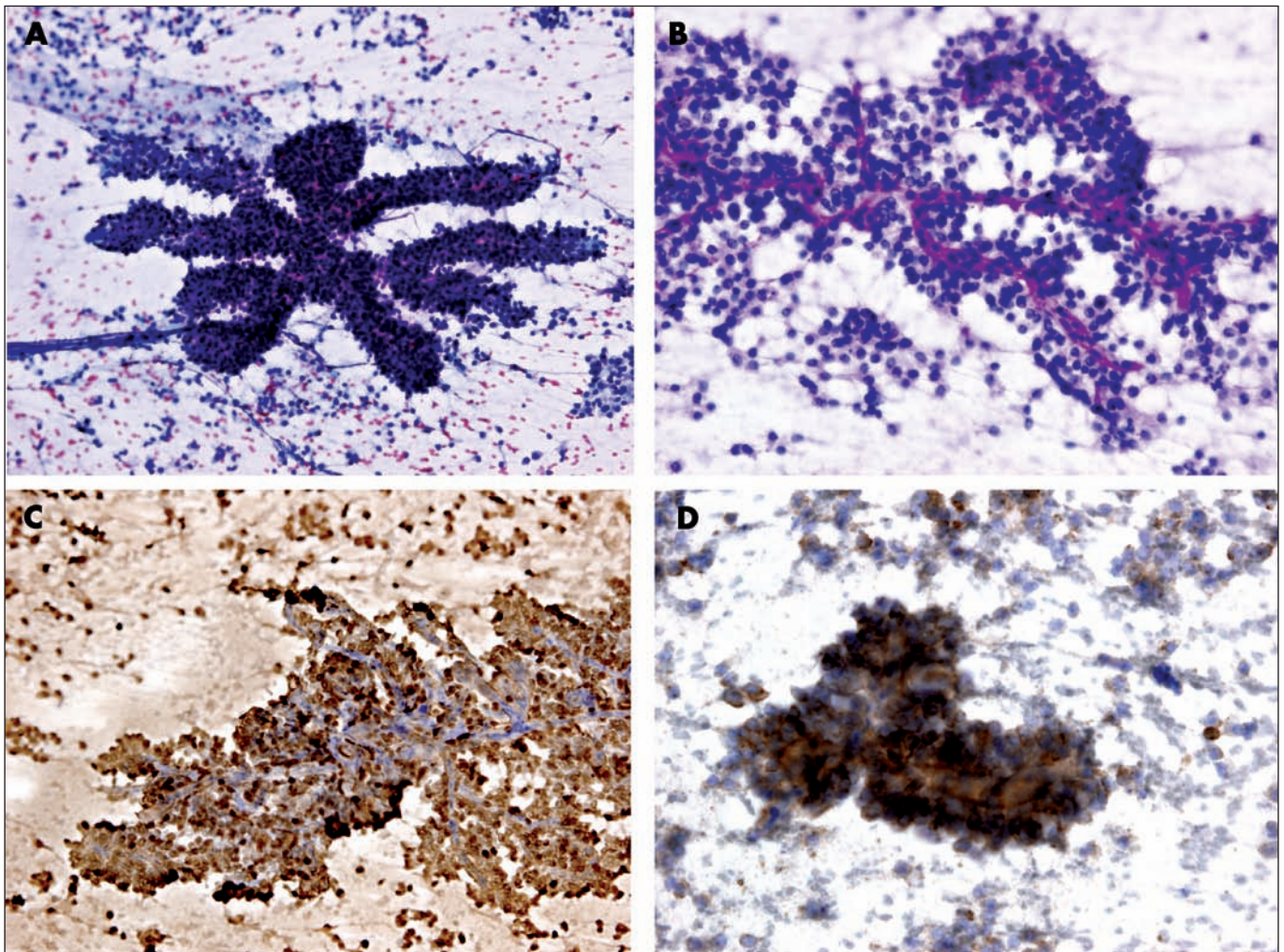


Fig. 3. Fine-needle aspirate from a patient with SPPT (case 3). A. Demonstrates fibrovascular stalks with cells lined at the surface an periphery of the core (Romanowsky stain x 200). B. Demonstrates ovoid cells lining the fibrovascular core with finely granular chromatin pattern (Romanowsky stain x 400). C. Detail showing the nuclear pattern with intense labeling for  $\beta$ -Catenin (x 400). D. Demonstrates positive staining with immunoperoxidase for CD-10 (x 400) from the same case.

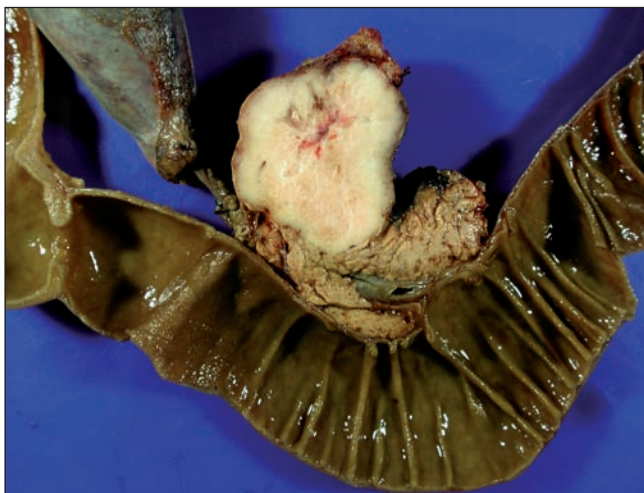


Fig. 4. Gross appearance of pancreatoduodenectomy specimen for SPPT (case 3) showing the well circumscribed solid lesion in the head of the pancreas, displacing the rest of the parenchyma.

unusual developing early loco-regional recurrence and distant development of metastases in spite of adjuvant treatment, dying on the 16 postoperative month. We have found ten cases of a total of 433 published patients (2,3%) in 17 clinical series with a similar evolution (4,6-8,11,14,16,23-32). Tang et al., from Memorial Sloan-Kettering, published two similar cases out of 36 patient series, who died at 6 and 16 months after surgical resection. They were two females of superior age to the mean (33 and 45 years) who had large tumors of 9 and 20 cm diameter size respectively. One case showed a synchronic liver metastases and the other one lymph node involvement. Tumor necrosis, diffuse invasion, a higher mitotic index and infiltration with invasion of the duodenal lumen, as well as in our case number 1, were the differential findings (11, 33) with the remaining 34 patients.

One of the paradigmatic fact of SPPT is that long-term survival –superior to 5 – 12 years- have been assessed in the setting of patients with liver metastases, multiple

**Table I. Clinical experience in SPPT\*. Most numerous series in adults**

Author (Ref.)	Year	Age	No. cases	Sex ratio (M/F)	Symptoms n (%)	Size (cm)	DPC	PD	Surgical procedure				Follow-up (m)	Results
									PC	PT	Enuc.	Other		
Sun (23)	2003	27 (11-59)	28	23/5	23 (82%)	6 (1,2-6)	10	16			2		67 (7-110)	28 alive 1 liver recurrence
Papavramidis* (12)	2005	22 (2-89)	710	626/84		6.08 (0.5-34)	142	221	7	5	26	150 *	—	95% alive at 5 y.
Tiptom (27)	2006	30 (15-57)	14	13/1	nc	7 (4-16)	3	10					87.6 (3-240)	12 alive 2 liver rec. at 7 & 1 y. 1 periton. Rec. at 14 m.
Salvia (14)	2007	31 (7-56)	31	27/4	14 (45%)	6 (2-15)	9	11	6		1	4	58.2 (7-229)	34 alive No recurrence
Lee (4)	2008	30 (18-63)	62	57/5	21 (33%)	6 (1.5-14)	19	38	2	1		2	47.5 (5-240)	62 alive 2 rec. at 16 m. & 7 y.
Machado (8)	2008	23 (10-72)	34	27/7	27 (79%)	7 (1.5-15)	11	15	5	-	3			
Reddy (16)	2009	32 (13-75)	37	33/4	27 (87%)	4.6 (0.3-12)	14	20		1	1	1	57.6 (0.8-328.8)	34 alive 1 rec. at 7.7 y.

\*Review. DPC: Pancreaticoduodenectomy. DP: Distal pancreatectomy. CP: Central pancreatectomy. TP: Total pancreatectomy. Enuc.: Enucleation

node metastases and incomplete resections as well (10,12,14,16).

In our cases, the diagnosis was established as incidental lesion on CT imaging in spite of being large tumors with an axial diameter between 4.5 and 8 cm. When presenting, the abdominal symptoms are vague and unspecific (epigastric discomfort, nausea, weight loss). Only 1% of the patients present jaundice, even with tumors located in the head of the pancreas, as occurred in cases 1 and 3 (10,12,16,17,22).

The radiological features on CT and MRI show well circumscribed lesions with solid cystic changes and the presence of hemorrhagic areas within the tumor with high signal intensity on T1-weighted images after gadolinium-enhanced pulse sequences- (34). The three cases were preoperatively diagnosed with the FNA cytology study. This method, which is the most accurate for the cystic neoplasms of the pancreas, has been unusually described by most of the authors. In a review of 718 patients, only 52 cases (7%) were diagnosed by the FNA (12). Salvia et al. performed this technique in only 10 patients out of 31 (32.2%) SPPT's patients with a sensitivity of 50% (14).

Jani reports a 75% efficacy (21/28 cases) with FNA guided in EUS exploration and points out the value of the immunohistochemical study in the cytology (35,36).

From the cytological view the different diagnosis with neuroendocrine tumors (NET) it could be difficult, whereas a positive staining for chromogranine A, CD10, PR and CD56 have been described in both tumors (11,37-39).

The nuclear and cytoplasmic expression of E-Cadherin and beta-catenin members of the Wnt pathway as specific markers have been reported in the 100% of TSP meanwhile on the NET the beta-catenin expression is located in the cellular membrane (24,40-42). These techniques should be incorporated in the diagnostic ar-

mamentarium when SPPT would be suspected (43). In our most recent case –number 3– the nuclear immunoreactivity for Beta-Catenin confirmed the diagnosis.

The origin of the SPPT is still an enigma. The original cell of the tumor has not been identified in spite of the recent immunohistochemical findings (44). Some authors have proposed the ovaric origin due to the relation of the pancreas with the genital ridge during the early embryogenesis (44). Geers has recently suggested the pancreatic acinar cells as its origin, although the debate regarding the SPPT ontogenesis is continuing (9,40,41,45,46).

The prognostic factor neither have been identified, having related the outcomes with the tumor size, mitotic index, necrosis grade, duodenal invasion and the presence of lymphatic metastases (8, 11, 16, 47). This enigmatic pattern contrasts with the recent knowledge of the cystic tumor of the pancreas as the intraductal papillary mucinous neoplasm (IPMN) (48, 49, 50).

Finally we mention the alteration on  $\beta$ -Catenin / E-Cadherin. The  $\beta$ -Catenin protein is involved in the development and organogenesis of multiple tissues regulated by the Wnt/ $\beta$ -Catenin signalization pathway. Recent studies have pointed out the role of this pathway in the pancreas organogenesis being inhibited in the adult pancreas tissue (51, 52).  $\beta$ -Catenin/APC mutations and Wnt signaling pathway alterations have been associated with the pancreatoblastoma, acinar carcinoma, pancreatic ductal adenocarcinoma and SPPT (40,41,53-55).

Heiser et al has recently developed an experimental model in mice, inducing the mutation in that pathway, suggestion that these alterations would be the origin of SPPT (46). In spite of these findings the SPPT is an "enigmatic" tumor with aspects remaining to be revealed.

## REFERENCES

- Frantz VK. Papillary tumors of the pancreas: benign or malignant? Tumors of the pancreas. Atlas of tumor Pathology, 1st ed. Washington DC, Armed Forces Institute of Pathology 1959; 32-3.
- Hamoudi AB, Misugi K, Grosfeld JL, Reiner CB. Papillary epithelial neoplasm of pancreas in a child: report of a case with electron microscopy. *Cancer* 1970; 26: 1126-33.
- Nagri S, Abdu A, Anand S, Krishnaiah M, Arya V. Liver Metastasis Four Years after Whipple's Resection for Solid-Pseudopapillary Tumor of the Pancreas. *J. Pancreas* 2007; 8: 223-7.
- Lee SE, Jang JY, Hwang DW, et al. Clinical Features and Outcome of Solid Pseudopapillary Neoplasm: Differences Between Adults and Children. *Arch Surg* 2008;143: 1218-21.
- Sperti C, Berselli M, Pasquali C, et al. Aggressive behaviour of solid-pseudopapillary tumor of the pancreas in adults: A case report and review of the literature. *World J. Gastroenterol* 2008; 14: 960-5.
- Tien YW, Ser KH, Hu RH, et al. Solid pseudopapillary neoplasms of the pancreas: is there a pathologic basis for the observed gender differences in incidence?. *Surgery* 2005; 137: 591-6.
- Takahashi Y, Hiraoka N, Onozato K, et al. Solid-pseudopapillary neoplasms of the pancreas in men and women: do they differ? *Virchows Arch* 2006; 448: 561-9.
- Machado MC, Machado MA, Bacchetta T, et al. Solid pseudopapillary neoplasm of the pancreas: distinct patterns of onset, diagnosis, and prognosis for male versus female patients. *Surgery* 2008; 143: 29-34.
- Hidalgo MH, Ferrero EH. Solid-cystic papillary epithelial neoplasm of the pancreas. A diagnostic and therapeutic challenge. *Rev Esp Enferm Dig* 2006; 98: 801-8.
- Mortenson MM, Katz MHG, Tamm EP, et al. Current diagnosis and management of unusual pancreatic tumors. *Am J Surg* 2008; 196: 100-13.
- Adams AL, Siegal GP, Jhala NC. Solid pseudopapillary tumor of the pancreas: a review of salient clinical and pathologic features. *Ad Anat Pathol* 2008; 15: 39-45.
- Papavramidis T, Papavramidis S. Solid pseudopapillary tumors of the pancreas: Review of 718 patients reported in English literature. *J Am Coll Surg* 2005; 200 (6): 965-72.
- Frago R, Fabregat J, Jorba R, García-Borobia F, Altet J, Serrano MT et al. Tumor sólido pseudopapilar de páncreas: diagnóstico y tratamiento curativo. *Rev Esp Enferm Dig* 2006; 98: 809-16.
- Salvia R, Bassi C, Festa L, et al. Clinical and biological behavior of pancreatic solid pseudopapillary tumors: report on 31 consecutive patients. *J Surg Oncol* 2007; 95: 304-10.
- Garcea G, Ong SL, Rajesh A, et al. Cystic lesions of the pancreas. A diagnostic and management dilemma. *Pancreatol* 2008; 8: 236-51.
- Reddy S, Cameron JL, Scudiere J. Surgical management of solid-pseudopapillary neoplasms of the pancreas (Franz or Hamoudi tumors): a large single-institutional series. *J Am Coll Surg* 2009; 208: 950-7.
- Chakhachiro ZI, Zaatari G. Solid-pseudopapillary neoplasm: a pancreatic enigma. *Arch Pathol Lab Med* 2009; 133: 1989-93.
- Klöppel G, Solcia E, Longnecker DS, et al. Histological typing of tumours of the exocrine pancreas. 2nd Ed. (WHO International Histological Classification of Tumours). Springer-Verlag. Berlín. Heidelberg. New York; 1996.
- Klöppel G, Lüttges J. WHO-Classification 2000: Exocrine pancreatic tumors. *Verh Dtsch Ges Path* 2001; 85: 219-28.
- Maffuz A., Bustamante F., Silva JJ, et al. Preoperative gemcitabine for unresectable solid pseudopapillary tumour of the pancreas. *Lancet Oncol* 2005; 6: 185-86.
- Campbell F, Azadeh B. Cystic neoplasms of the exocrine pancreas. *Histopathology* 2008; 52: 539-51.
- Lam KY, Lo CY, Fan ST. Pancreatic solid-cystic papillary tumor: clinicopathologic features in eight patients from Hong Kong and review of the literature. *World J Surg* 1999; 23: 1045-50.
- Sun CD, Lee WJ, Choi JS, et al. Solid-pseudopapillary tumours of the páncreas. *ANZ J. Surg.* 2003; 73: 410-5.
- Tanaka Y, Kato K, Notohara K, et al. Frequent beta catenin mutation and cytoplasmic/nuclear accumulation in pancreatic solid-pseudopapillary neoplasm. *Cancer Res.* 2001; 61: 8401-4.
- Choi JY, Kim MJ, Kim JH, et al. Solid pseudopapillary tumor of the pancreas: typical and atypical manifestations. *AJR* 2006; 187: W178-86.
- Goh BKP, MBBS, Tan YM, Cheow PC, et al. Solid pseudopapillary neoplasms of the pancreas: An updated experience. *J Surg Oncol* 2007; 95: 640-4.
- Tipton SG, Smyrk TC, San MG, et al. Malignant potential of solid pseudopapillary neoplasms of the pancreas. *Br J Surg* 2006; 93: 733-7.
- Cheng-Hong P, Dong-Feng C, Guang-wen Z, et al. The solid-pseudopapillary tumor of pancreas. The clinical characteristics and surgical treatment. *J Surg Res* 2006; 131: 276-82.
- De Castro SMM, Singhal D, Aronson DC, et al. Management of solid-pseudopapillary neoplasms of the pancreas: a comparison with standard pancreatic neoplasms. *World J Surg* 2007; 31: 1129-34.
- Nakagohri T, Kinoshita T, Konishi M, et al. Surgical outcome of solid pseudopapillary tumor of the pancreas. *J Hepatobiliary Pancreat Surg* 2008; 15: 318-21.
- Yang F, Jin C, Long J, et al. Solid pseudopapillary tumor of the pancreas: a case series of 26 consecutive patients. *Am J Surg* 2009; 198(2): 210-5.
- Matos JM, Grützmann R, Agaram NP, et al. Solid pseudopapillary neoplasms of the pancreas: a multi-institutional study of 21 patients. *J Surg Res* 2009; 157: 137-42.
- Tang LH, Aydin H, Brennan MF, Klimstra DS. Clinically aggressive solid pseudopapillary tumors of the pancreas: a report of two cases with components of indifferently differentiated carcinoma and a comparative clinicopathologic analysis of 34 conventional cases. *Am J Surg Pathol* 2005; 29(4): 512-9.
- Choi JY, Kim MJ, Kim JM, et al. Solid pseudopapillary tumor of the pancreas: typical and atypical manifestations. *Am J Roentgenol* 2006; 187: 178-86.
- Jani N, Dewitt J, Eloubeidi M, et al. Endoscopic ultrasound-guided fine-needle aspiration for diagnosis of solid pseudopapillary tumors of the pancreas: a multicenter experience. *Endoscopy* 2008; 40: 200-3.
- Bardales RH, Centeno B, Mallory JS, et al. Endoscopic ultrasound-guided fine-needle aspiration cytology diagnosis of solid-pseudopapillary tumor of the pancreas. *Anat Pathol* 2004; 121: 654-62.
- Notohara K, Hamazaki S, Tsukayama C, et al. Solid-pseudopapillary tumor of the pancreas: immunohistochemical localization of neuroendocrine markers and CD10. *Am J Surg Pathol* 2000; 24: 1361-71.
- Burford H, Baloch Z, Liu X, Jhala D, Siegal GP, Jhala N. E-cadherin/beta-catenin and CD10: a limited immunohistochemical panel to distinguish pancreatic endocrine neoplasm from solid pseudopapillary neoplasm of the pancreas on endoscopic ultrasound-guided fine-needle aspirates of the pancreas. *Am J Clin Pathol* 2009; 132: 831-9.
- Lévy P, Auber A, Ruszniewski P. Do not biopsy solid pseudopapillary tumors of the pancreas! *Endoscopy* 2008; 40: 960.
- Abraham SC, Wu TT, Hruban RH, et al. Genetic and immunohistochemical analysis of pancreatic acinar cell carcinoma: frequent allelic loss on chromosome 11p and alterations in the APC/beta-catenin pathway. *Am J Pathol* 2002; 160: 953-62.
- Abraham SC, Klimstra DS, Wilentz RE, et al. Solid-Pseudopapillary tumors of the pancreas are genetically distinct from pancreatic ductal adenocarcinomas and almost always harbor  $\beta$ -catenin mutations. *Am J Pathol* 2002; 160: 1361-9.
- Min Kim S, Sun CD, Park KC, Kim HG, Lee WJ, Choi SH. Accumulation of beta-catenin protein, mutations in exon-3 of the beta-catenin gene and a loss of heterozygosity of 5q22 in solid pseudopapillary tumor of the pancreas. *J Surg Oncol* 2006; 94: 418-25.
- Chetty R, Serra S. Nuclear E-cadherin immunoreactivity: from biology to potential applications in diagnostic pathology. *Adv Anat Pathol* 2008; 15: 234-40.
- Kosmahl M, Seada LS, Jänig U, Harms D, Klöppel G. Solid-pseudopapillary tumor of the pancreas: its origin revisited. *Virchows Arch* 2000; 436: 473-80.
- Geers C, Pierre M, Gigot JF, et al. Solid and pseudopapillary tumor of the pancreas-review and new insights into pathogenesis. *Am J Surg Pathol* 2006; 30: 1243-9.
- Heiser PW, Cano DA, Landsman L, et al. Stabilization of B-Catenin induces pancreas tumor formation. *Gastroenterology* 2008; 135:

- 1288-300.
47. Washington K. Solid-pseudopapillary tumor of the pancreas: challenges presented by an unusual pancreatic neoplasm. *Ann Surg Oncol* 2002; 9: 3-4.
  48. Maitra A, Fukushima N, Takaori K, et al. Precursors to invasive pancreatic cancer. *Adv Anat Pathol* 2005; 12: 81-91.
  49. Singh M, Maitra A. Precursor lesions of pancreatic cancer: molecular pathology and clinical implications. *Pancreatology* 2007; 7: 9-19.
  50. Hruban RM, Maitra A, Kern SE, et al. Precursor to pancreatic cancer. *Gastroenterol. Clin N Am* 2007; 36: 831-49.
  51. Murtaugh LC, Law AC, Dor Y, et al. Beta-catenin vs essential for pancreatic acinar but not islet development. *Development* 2005; 132: 4663-74.
  52. Wells JM, Esni F, Boivin GP, et al. Wnt/ $\beta$ -catenin is required for development of the exocrine pancreas. *BMC Dev Biol* 2007; 7: 4.
  53. Koesters R, Von Knebel Doeberitz M. The Wnt signaling pathway in solid childhood tumors. *Cancer Lett* 2003; 198: 123-38.
  54. Lowy AM, Fenoglio-Preiser C, Kim OJ, et al. Dysregulation of beta-catenin expression correlates with tumor differentiation in pancreatic duct adenocarcinoma. *Ann Surg Oncol* 2003; 10: 284-90.
  55. Zeng G, Germinaro M, Micsenyi A, et al. Aberrant Wnt/beta-catenin signaling in pancreatic adenocarcinoma. *Neoplasia* 2006; 8: 279-89.