1130-0108/2011/103/8/427-428
Revista Española de Enfermedades Digestivas
Copyright © 2011 Arán Ediciones, S. L.
Rev Esp Enferm Dig (Madrid)
Vol. 103. N.° 8, pp. 427-428, 2011

PICTURES IN DIGESTIVE PATHOLOGY

Cat scratch esophagus: a new entity to be described?

Benito Velayos, Luis Fernández, Lourdes del Olmo, Lourdes Ruiz, Rocío Aller, Ana Macho, Fernando de la Calle, Teresa Arranz and José Manuel González

Department of Gastroenterology. Hospital Clínico de Valladolid. Valladolid, Spain

CASE REPORT

We report the case of an 84 years old man without significant medical history. He consulted for rapidly progressive dysphagia for solids and liquids and loss of weight. The gastroscopy showed a dilated esophagus but no trace of food in it. The esophageal mucosa had superficial and linear tears that followed the long axis from the middle to the cardias (Fig. 1). The endoscopic view remembered that would cause a cat scratching on a tubular fabric. Among the mucosal flaps we could see an entire and erythematous submucosa with its microvasculature respected (Fig. 2). Endoscopic progression, which was not traumatic, diagnosed a cardiac tumor that was generating an incomplete stenosis at that level. Histology showed a squamous stratified epithelium.

DISCUSSION

Linear mucosal breaks (cat scratch) have been described in the colon (1); until now we have not found cases reported in the esophagus. Diagnosis is made morphologically, when the endoscopic view mimics the image of a cat scratch. They are longitudinal and superficial lesions that affect the mucosa without symptoms in most of the cases (2). When they occur in the colon, it is thought that they are due to the barotrauma secondary to distension; so, they are attributed to insufflation on a mucosa with some kind of microscopic diffuse damage (3). Other authors emphasize the importance of changes in elasticity or even taking some drugs (4).

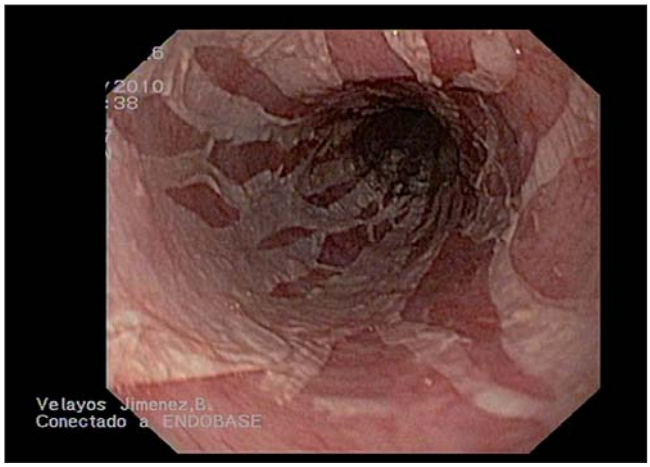

Fig. 1.

Fig. 2.

In our case we think the rapid and prolonged distension which the esophagus endured due to a cardiac tumor of explosive growth led to a detachment of the mucosa, manifested in the tears described in our endoscopy.

REFERENCES

1. McDonnell WM, Loura F, Pointon MJ, Greenson JK. Cat scratch colon. Endoscopy 2007;39(5):459-61.
2. Baudet JS, Arguiñarena X, Díaz-Bethencourt D, Soler M, Avilés J. Cat scratch colon. A little known condition. Rev Esp Enferm Dig 2008;100(12):790-1.
3. Baudet JS, Díaz-Bethencourt D, Arguiñarena X, Soler M, Morales S, Avilés J. Cat Scratch colon is caused by barotrauma secondary to insufflation during colonoscopy. Endoscopy 2008;40(10):878.
4. Payeras G, Briz R, Barranco R, Calvache A, Castro P. Cat scratch colon. A new ethiopathogenic possibility. Rev Esp Enferm Dig 2010;102(12):720-1.