

## Letters to the Editor

### Therapeutic options in pancreatic pseudoaneurysms

*Key words: Pseudoaneurysm. Pancreatitis. Management.*

Dear Editor,

The pseudoaneurysm is a rare entity that occurs in the context of pancreatitis as a complication in the development of the disease, affecting from 3.5 to 10% of patients with this pathology (1-3).

It is a condition of great clinical importance and not free from complications, mostly serious, mainly because of rupture, a fact which happens around 50%, with a very high mortality rate (4,5).

In the period between 1999 and 2010 we have had the opportunity to treat two patients with pseudoaneurysm in the context of chronic pancreatitis. They had different debuting shapes and were resolved so vastly different. This is why this serious disease is analyzed after presenting the cases and various treatment alternatives are offered.

#### Case reports

The first patient was a 43-year-old male diagnosed with alcoholic chronic pancreatitis, who was admitted due to a hypovolemic shock, whose CT scan and selective mesenteric arteriography showed a pancreatic pseudoaneurysm with ruptured splenic artery. He underwent emergency surgery to find a hemoperitoneum due to ruptured pseudoaneurysm of about 10 cm, within which the splenic artery was found profusely bleeding. Vascular hemostatic control was performed, pseudoaneurysm resection, splenectomy and cholecystectomy without incident.

The second patient was a 45-year-old male with a history of

liver disease and alcoholic pancreatitis and abdominal pain, whose CT SCAN showed the existence of a 4x3 cm pseudoaneurysm in the pancreatic head, confirmed by angio-TC scan (Fig. 1) and mesenteric arteriography. The patient underwent selective catheterization and embolization of the branch to which it belonged without incident.

#### Discussion

Most patients start with nonspecific epigastric pain, but some other cases include debut as upper gastrointestinal bleeding due to rupture into the duct of Wirsung (also known as hemosuccum) or

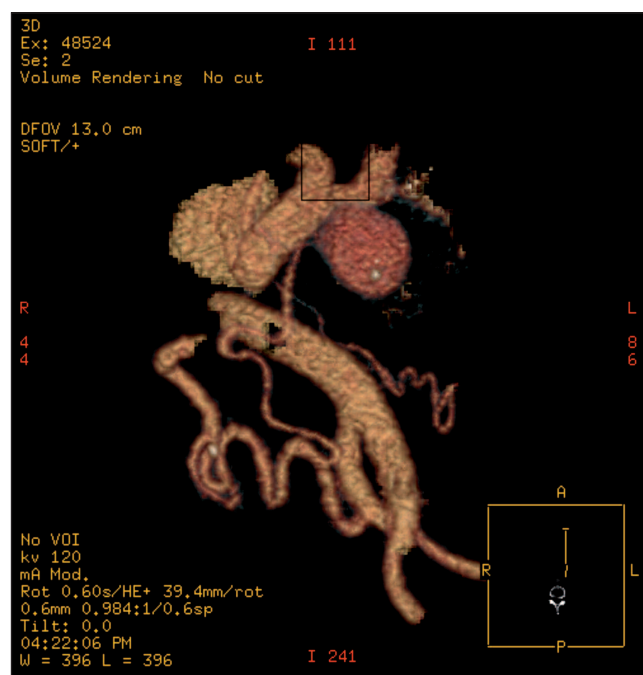


Fig. 1. Aortic angio-CT scan where 39-cm-in-diameter pancreatic pseudoaneurysm is verified, attached to a branch of the gastroduodenal artery.

a more dramatic approach as massive hemoperitoneum due to rupture to free cavity, as our first case was, a really dramatic episode indeed with very high postoperative mortality figures (1,5-8).

Surgery has been traditionally the treatment employed to solve this entity, however nowadays endovascular aneurysm embolization is the treatment chosen up to 80% of cases (5,9), with different techniques depending on the material used (6-8).

Surgery is often complex and difficult, owing to various circumstances, especially the presence of a large retroperitoneal hematoma and inflammatory component secondary to pancreatic process, its anatomical location and the presence of numerous collateral arteries (7,9,10).

As for the technique, control and vascular ligation of the aneurysm would be ideal, but on many occasions, we must resort to performing cephalic or distal pancreatectomy (8-10).

Direct puncture and embolization by laparotomy and percutaneous thrombin injection has been described as a definitive intraaneurismatic treatment as a secondary option when endovascular techniques fail (3,4).

José Vázquez-Ruiz, Diego Mansilla-Molina,  
Joaquín Francisco Civera-Muñoz, José Fernández-Moreno,  
José Eduardo Pérez-Folqués and Jesús Guirao-Manazano

*Department of General Surgery and Digestive Diseases.  
Hospital Virgen del Castillo. Yecla, Murcia. Spain*

## References

1. Mallick IH, Winslet MC. Vascular complications of pancreatitis. JOP 2004;5:328-37.
2. Izaguirre Loroño M, Estallo Laliena L, Vega De Céniga M, et al. Aneurismas y pseudoaneurismas peripancreáticos complicados. Angiología 2007;59:73-8.
3. Pacheco Jiménez M, Moreno Sánchez T, Moreno Rodríguez F, Guillen Rico M. Seudoaneurisma de la cola pancreática: tratamiento percutáneo mediante inyección de trombina. Radiología 2011; doi: 10.1016/j.rx.2011.04.009.
4. García Vila JH, Bordón F, Redondo M, Díaz C, Salvador JL. Tratamiento de pseudoaneurisma pancreático por punción directa y embolización. Radiología 2001;43:79-81.
5. Vujic I. Vascular complications of pancreatitis. Radiol Clin of North Am 1989;27:81-91.
6. Ducasse E, Roy F, Chevalier J, Massoille D, Smith M, Speziale F, et al. Aneurysm of the pancreaticoduodenal arteries with a celiac trunk lesion: current management. J Vasc Surg 2004;39:906-11.
7. Majerus B, Alexandrescu V, Shutsha E, Timmermans M, Van Ruyssevelt C, Wibin E. Spontaneous rupture of the pancreaticoduodenal artery: three cases. Dig Surg 1998;15:266-9.
8. Blanco I, Guillaumes S, Clavé P, Farré A, Pérez C, López-Gilbert J, et al. Tratamiento del pseudoaneurisma pancreático simple o asociado a hemossuccus pancreaticus. Rev Esp Enferm Dig 1992;81:189-94.
9. Moore E, Matthews MR, Minion DJ, Quick R, Schwarcz H, Loh FK, et al. Surgical management of peripancreatic arterial aneurysms. J Vasc Surg 2004;40:247-53.
10. Azcano González E, Álvarez Laso CJ, Irurzun J, Masot Pérez J. Hemorragia digestiva por pseudoaneurisma con drenaje espontáneo de pseudoquistes pancreáticos. Rev Esp Enferm Dig 2008;100:179-80.