

Letters to the Editor

***Aloe vera*: Not always so beneficial in patients with chronic liver disease**

Key words: Hepatotoxicity. Aloe vera.

Dear Editor,

In the reviewed literature, *Aloe vera* is presented as a detoxifying product used in natural medicine and recommendable for people with liver disease (1). However, hepatotoxicity due to *Aloe vera* has also been described. We present a case of hepatotoxicity in a patient with cirrhosis of the liver.

Case report

A 49-year-old man in follow-up due to chronic liver disease caused by the hepatitis C virus (HCV). The patient had rejected antiviral treatment and was in a state of compensated cirrhosis.

He was admitted to our service due to jaundice and right hypochondrium pain lasting three days. The patient did not mention dietary or alcoholic transgression or the ingestion of drugs except drinkable *Aloe vera* with 99.7 % purity. He been taking 150 mL daily for 10 days (it had been recommended for its liver-protective effect).

Physical examination: jaundice, no ascites in the abdomen, pain in right hypochondrium. The analysis showed AST 125 U/L (normal < 37 U/L), ALT (alanine aminotransferase) 93 U/L (normal < 41 U/L), ALP (alkaline phosphatase) 421 U/L (normal < 300 U/L), total bilirubin 21 mg/dL (direct bilirubin 19.3 mg/dL).

Normal coagulation. Ceruloplasmin, alpha-1 antitrypsin, cryoglobulins and alpha-fetoproteins normal, auto-antibodies negative, Ig M anti HAV (hepatitis A virus), HBs Ag (hepatitis B surface antigen) negative, RNA HCV quantification 4,958 IU/mL.

The abdominal ultrasound and MR cholangiogram showed findings associated with chronic liver disease with intra-, extra-hepatic bile duct and pancreatic conduit with no alterations.

A liver biopsy was performed (Fig. 1): "Compatible with chronic hepatitis due to HCV and signs of cholestasis".

Discussion

The diagnosis was supported by the biopsy showing cholestasis and the patient responding to suppression of the toxin.

In general, liver damage can be hepatocellular, cholestatic or mixed, depending on the value in the ratio (R) (ALT/LSN)/

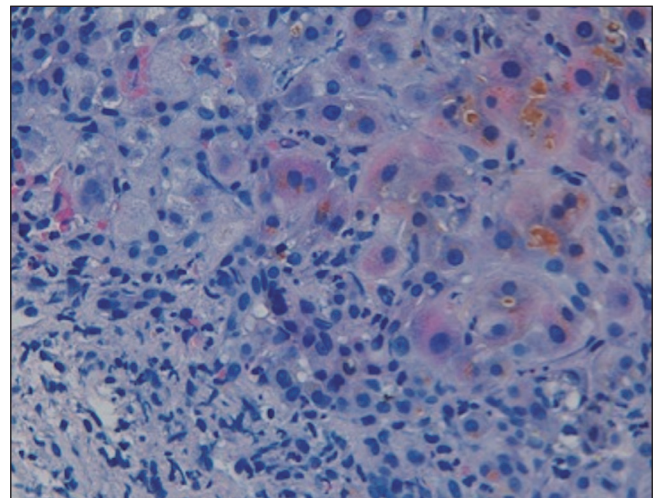


Fig. 1. Liver biopsy at 40 x HE (hematoxylin and eosin): Notable canalicular cholestasis and frequent images of biliary thrombi. In parenchyma: Increase in the reticulin section and lymphocytic inflammatory infiltrate with isolated eosinophils in the porta hepatis.

FA/LSN) (2). In cholestatic damage $R \leq 2$ and in our patient (R) it was 1.62. Causality was assessed using the Roussel Uclaf Causality Assessment Method (RUCAM) (3) with a score of 8, meaning that the Aloe vera is the “probable” cause.

There are around 400 species of Aloe, the most frequently used in phytomedicine being *Aloe vera* (*Aloe barbadensis miller*). It is said to have anti-inflammatory, liver protective, anti-carcinogenic and laxative properties. It can be administered topically or orally. It contains alkaloids that can induce the blockage of hepatic enzymes such as cytochrome P450 and certain compounds that can interact with the human autoimmune system; this has been used to explain its possible anti-tumour and detoxifying actions and its potential hepatic protector effect.

In recent years, several cases of hepatotoxicity due to *Aloe vera* have been published (4-9) but, as occurs with other alternative medicine products, no studies have been performed on its pharmacokinetics and toxicity. In most of these cases, the mechanism of hepatic lesion was idiosyncratic and the histology shows an inflammatory infiltrate with eosinophils in the porta hepatis.

To date, no cases of hepatotoxicity due to *Aloe vera* have been described in Spain (10), or in patients with chronic liver disease. Patients with chronic liver disease occasionally turn to alternative medicine and they should be warned that this is not free of risk.

Paola Vázquez-Fernández¹, Ana Garayoa-Roca¹, Ramón Añón-Rodríguez¹, María Cabezas-Macián², Miguel Ángel Serra-Desfilis¹ and Francisco Mora-Miguel¹

Departments of ¹Digestive Diseases and ²Pathology. Hospital Clínico Universitario de Valencia. Universidad de Valencia. Valencia, Spain

References

1. Vogler BK, Ernst E. Aloe vera: A systematic review of its clinical effectiveness. *Br J Gen Pract* 1999;49:823-8.
2. Bénichou C. Criteria of drug-induced liver disorders. Report of an International Consensus Meeting. *J Hepatol* 1990;11:272-6.
3. Rabe C, Musch A, Schirmacher P, Kruis W, Hoffmann R. Acute hepatitis induced by an aloe vera preparation: A case report. *World J Gastroenterol* 2005;11:303-4.
4. Yang HN, Kim DJ, Kim YM, Kim BH, Sohn KM, Choi MJ, et al. Aloe-induced toxic hepatitis. *J Korean Med Sci* 2010;25:492-5.
5. Kanat O, Ozet A, Ataergin S. Aloe vera-induced acute toxic hepatitis in a healthy young man. *Eur J Intern Med* 2006;17:589.
6. Bottenberg MM, Wall GC, Harvey RL, Habib S. Oral aloe vera-induced hepatitis. *Ann Pharmacother* 2007;41:1740-3.
7. Schoepfer AM, Engel A, Fattinger K, Marbet UA, Criblez D, Reichen J, et al. Herbal does not mean innocuous: Ten cases of severe hepatotoxicity associated with dietary supplements from herbalife products. *J Hepatol* 2007;47:521-6.
8. Bottenberg MM, Wall GC, Harvey RL, Habib S. Oral Aloe vera-induced hepatitis. *Ann Pharmacother* 2007;41:1740-3.
9. Curciarello J, De Ortúzar S, Borzi S, Bosia D. Hepatitis aguda grave asociada al consumo de Aloe vera. *Gastroenterol Hepatol* 2008; 31:436-8.
10. García-Cortés M, Borraz Y, Lucena M I, Peláez G, Salmerón J, Diago M, et al. Liver injury induced by “natural remedies”: An analysis of cases submitted to the Spanish liver toxicity registry”. *Rev Esp Enferm Dig* 2008;100:688-95.