

Letters to the Editor

Aspiration of capsule endoscope

Key words: Endoscope capsule. Complications. Aspiration.

Dear Editor,

The emergence of capsule endoscopy was an important breakthrough in the endoscopic study of the digestive tract, particularly in situations of iron-deficiency anemia and obscure gastrointestinal bleeding. The most common complication of the procedure is capsule retention, occurring in approximately 1-2 % of cases (1). Tracheal aspiration is a much rarer and potentially life-threatening complication, requiring immediate intervention for its extraction.

Case report

The authors present the case of a 78-year-old man, with chronic kidney failure treated with hemodialysis, referred for capsule endoscopy due to obscure gastrointestinal bleeding, demanding frequent blood transfusion. The capsule endoscope used was a PillCam SB (Given Imaging, Israel). It was swallowed in the presence of a doctor. The patient experienced deglutition difficulty, with several unsuccessful attempts. He suddenly developed vigorous coughing which ceased spontaneously a couple of minutes later, and did not experience further respiratory symptoms. The data recorder was recovered after battery depletion (9 h) and the video reviewed the following day. It became evident that, after a period of permanence in the oral cavity of 75 seconds, the capsule moved into the airway, showing the typical annular

structure of the trachea (Fig. 1A) and the tracheal bifurcation into the main bronchi (Fig. 1B). Following 2 minutes of inactivity, the capsule transmitted images from the esophagus (Fig. 1C). Once inside the digestive tract, it followed the normal trajectory, reaching the cecum after 7 h 28 m. Several small bowel angiodysplasias (Fig. 1D) were identified as the probable cause of the obscure gastrointestinal bleeding in this patient.

Discussion

Capsule endoscope aspiration is a very rare complication. Since 2005, more than 200 capsule procedures have taken place in our department, this one being the only time such complication

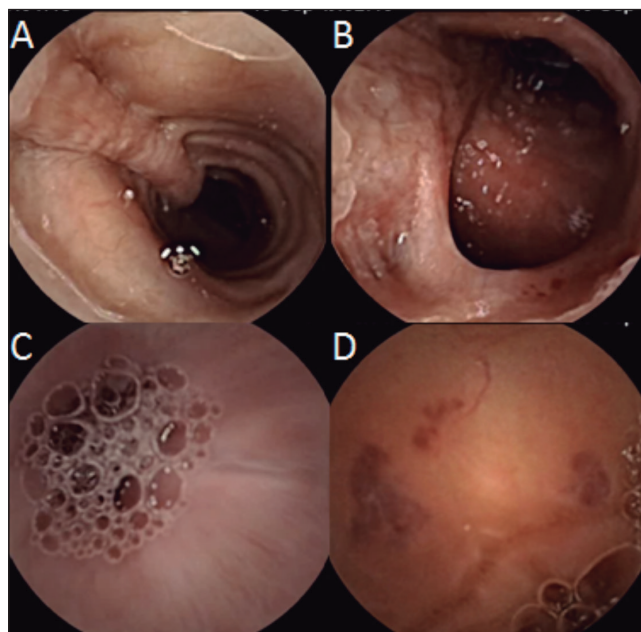


Fig. 1. Endoscopic capsule. A. Trachea. B. Trachea bifurcation into the main bronchi. C. Esophagus. D. Small bowel angiodysplasias.

occurred. Slightly more than ten cases have been reported in the English medical literature (2-10). The clinical spectrum is diverse, ranging from asymptomatic cases to severe hypoxemia and obstructive pneumonitis. In around half the reported cases, the capsule was expelled following effective coughing. In the remaining ones the capsule had to be retrieved through bronchofibroscopy, using devices like a net. This is the first case in which the capsule ended up being swallowed by the patient, after expulsion from the airway by cough, allowing the initially planned endoscopic evaluation of the small bowel and detection of a probable bleeding source. In order to prevent this complication, a past history of swallowing difficulty, which constitutes a relative contraindication, must be ruled out prior to the procedure. In the reported case, subsequent tests diagnosed oropharyngeal dysphagia, probably associated to cerebrovascular disease. In these patients, direct placement of the capsule in the duodenum through upper endoscopy is a viable alternative, allowing the procedure to be taken without the risk of aspiration.

Bruno Pereira, Antonieta Santos, Cátia Leitão and
António Bahudo

*Department of Gastroenterology. Hospital Amato Lusitano.
Castelo Branco, Portugal*

References

1. Ho KK, Joyce AM. Complications of capsule endoscopy. *Gastrointest Endosc Clin N Am* 2007;17:169-78. viii-ix.
2. Choi HS, Kim J, Kim HG, Lee TH, Kim WJ, Cho WY, et al. A case of asymptomatic aspiration of a capsule endoscope with a successful resolution. *Gut Liver* 2010;4:114-6.
3. Schneider AR, Hoepffner N, Rosch W, Caspary WF. Aspiration of an M2A capsule. *Endoscopy* 2003;35:713.
4. Tabib S, Fuller C, Daniels J, Lo SK. Asymptomatic aspiration of a capsule endoscope. *Gastrointest Endosc* 2004;60:845-8.
5. Nathan SR, Biernat L. Aspiration: An important complication of small-bowel video capsule endoscopy. *Endoscopy* 2007;39(Supl. 1):E343.
6. Fleischer DE, Heigh RI, Nguyen CC, Leighton JA, Sharma VK, Musil D. Videocapsule impaction at the cricopharynx: A first report of this complication and its successful resolution. *Gastrointest Endosc* 2003;57:427-8.
7. Sepehr A, Albers GC, Armstrong WB. Aspiration of a capsule endoscope and description of a unique retrieval technique. *Otolaryngol Head Neck Surg* 2007;137:965-6.
8. Shiff AD, Leighton JA, Heigh RI. Pulmonary aspiration of a capsule endoscope. *Am J Gastroenterol* 2007;102:215-6.
9. Sinn I, Neef B, Andus T. Aspiration of a capsule endoscope. *Gastrointest Endosc* 2004;59:926-7.
10. Guy T, Jouneau S, D'Halluin PN, Lena H. Asymptomatic bronchial aspiration of a video capsule. *Interact Cardiovasc Thorac Surg* 2009;8:568-70.