

Letters to the Editor

Carcinoid tumor of the common bile duct

Key words: Neuroendocrine tumors. Carcinoids. Bile duct. Surgery.

Dear Editor,

Neuroendocrine tumors represent an uncommon pathology of complex diagnosis. Among gastrointestinal neuroendocrine tumors, approximately 55 % are carcinoid tumors and about 40 % are neuroendocrine. Carcinoids of biliary tract are extremely rare, only 0.2-2 % of all gastrointestinal carcinoid (1). The most common sites of involvement are as follow: main bile duct (58 %), perihilar region (28 %), cystic duct (11 %), and common hepatic duct (3 %) (2).

Case report

We report the case of a 19 years-old woman with history of pruritus, jaundice, weight loss, and anorexia.

Physical examination revealed only mild scleral jaundice. Blood tests showed a total bilirubin of 3.3 mg/dl (2.6 mg/dl direct bilirubin). Plasma levels of aminotransferases, gamma-glutamyl transferase and serum alkaline phosphatase were also elevated. Tumor markers were within normal ranges.

Ultrasonography and magnetic resonance (Fig. 1) showed dilatation of the intra/extrahepatic bile ducts up to the proximal common hepatic duct where there was a mass measuring approximately 2 cm, with heterogeneous uptake, without lymph nodes. An endoscopic retrograde cholangiographic (ERCP) was attempted but it was unsuccessful.

Exploratory laparotomy was proposed, where a nodular tumor arising from the bile duct was observed. Full exploration of abdominal cavity resulted unremarkable. Resection of the extrahepatic biliary tree and lymphadenectomy, with "Roux Y" reconstruction were performed. Intraoperative biopsy confirmed resection margins without malignancy. Postoperative evolution was satisfactory.

Histopathology showed a moderately differentiated neuroendocrine tumor (G2), with a mitotic rate of 6-8/10-high-power-fields and Ki-67 index of 10%.

Patient was referred to Oncology Department but no further treatment was considered.

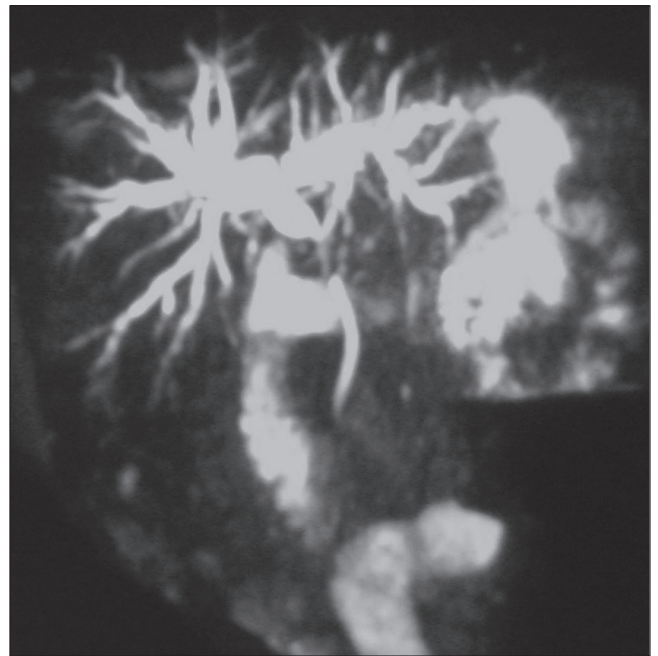


Fig. 1. Magnetic resonance: Stop in common hepatic duct with dilatation of the intrahepatic biliary tree.

Discussion

Carcinoid tumors arise from embryonal neural crest cells (Kulchitsky cells). They are present along the gastrointestinal tract; however, its presence in the biliary tree is very rare. Chronic inflammatory changes may result in metaplasia of endocrine cells in the biliary epithelium and that is thought to be precursor of carcinoid tumors (3). Its presentation is twice more common in female gender and they frequently appear in younger patients than other tumors of the biliary tree (mean age: 47 years old) (4).

Jaundice is the most common symptom, while pain at right upper quadrant is a predominant symptom when tumors arise from the cystic duct (4). Biliary carcinoids can be hormonally active (5).

Diagnosis may be the major challenge. Blood tests are commonly reported as useless and tumor markers usually are normal. Hormone detection could be helpful in hormonally active tumors. Imaging tests fail to differentiate between these tumors and others causes of biliary obstruction. ERCP could be considered as helpful and provide the possibility of taking biopsies, but they are usually reported as failed (4,6). Only histopathology confirmation can give us a certain diagnosis and usually surgery is needed for this.

Surgical resection is the primary treatment for biliary carcinoids (7). Local resection could be enough treatment if clear margin are achieved, but liver resection and liver transplantation have been described. The role of adjuvant therapy is controversial. 5-Fluorouracil and streptozocin appear to have the most activity against gastrointestinal carcinoids (8), however they have failed to demonstrate survival advantage. There is no current role for radiotherapy in the treatment of carcinoid tumors (9).

M.^a Dolores Ayllón-Terán, Amparo Valverde-Martínez,
Rafael Díaz-Nieto, Rubén Ciria-Bru, Antonio Luque-Molina,
Pedro López-Cillero and Javier Briceño-Delgado

*Department of Hepatobiliary Surgery. Hospital Universitario
Reina Sofía. Córdoba, Spain*

References

1. Hubert C, Sempoux C, Berquin A, Deprez P, Jamar F, Gigot JF. Bile duct carcinoid tumors: An uncommon disease but with a good prognosis? *Hepatogastroenterology* 2005;52:1042-7.
2. Jimenez R, Beguiristain A, Ruiz-Montesinos I, Villar F, Medrano MA, Garnateo F, et al. Intrahepatic biliary carcinoid. *Rev Esp Enferm Dig* 2007;99:287-8.
3. Barron-Rodriguez LP, Manivel JC, Mendez-Sanchez N, Jessurun J. Carcinoid tumor of the common bile duct: Evidence for its origin in metaplastic endocrine cells. *Am J Gastroenterol* 1991;86:1073-6.
4. Menezes AA, Diver AJ, McCance D, Diamond T. Carcinoid tumour of the extrahepatic bile duct -Report of a case and literature review. *Ulster Med J* 2004;73:59-62.
5. Hao L, Friedman AL, Navarro VJ, West B, Robert ME. Carcinoid tumor of the common bile duct producing gastrin and serotonin. *J Clin Gastroenterol* 1996;23:63-5.
6. Nafidi O, Nguyen BN, Roy A. Carcinoid tumor of the common bile duct: A rare complication of von Hippel-Lindau syndrome. *World J Gastroenterol* 2008 28;14:1299-301.
7. Podnos YD, Jimenez JC, Zainabadi K, Ji P, Cooke J, Busuttill RW, et al. Carcinoid tumors of the common bile duct: Report of two cases. *Surg Today* 2003;33:553-5.
8. Weatherstone K, Meyer T. Streptozocin-based chemotherapy is not history in neuroendocrine tumours. *Target Oncol* 2012;7:161-8.
9. Kulke MH, Mayer RJ. Carcinoid tumors. *N Engl J Med* 1999;340:858-68.