

Letters to the Editor

Massive gastrointestinal pneumatosis in a patient with celiac disease and superior mesenteric artery syndrome

Key words: Pneumatosis intestinalis. Celiac disease. Superior mesenteric artery syndrome.

Dear Editor,

A 55-year-old man was admitted into the emergency department presenting two-week history of vomiting after solid and liquid intake. In the latest 48 hours, he had presented clinical worsening, associating progressively deteriorating general health status and abdominal distension. The patient presented a history of symptomatic superior mesenteric artery syndrome (SMAS) with sporadic episodes of vomiting. Among his other precedents, five-year history of celiac disease (CD) with good compliance to the diet should be highlighted. He also was receiving beclometasone due to hip artrosis.

The first exploration revealed a distended abdomen painless on palpation, not presenting signs of peritoneal irritation. Blood analysis only showed elevated levels of C-reactive protein (45 mg/dL) with mild hypochloremic metabolic alkalosis. Plain abdomen X-ray showed generalized distension of small bowel and stomach, both presenting pneumatosis. Due to this, an abdominal computed tomography (TC) was carried out. It showed the same findings in stomach and the totality of small bowel limbs, associating important retroperitoneum. The aorta and mesenteric trunks were shown permeable (Fig. 1).

A nasogastric tube (NGT) was placed, obtaining 1 liter of biliar liquid. Due to clinical and exploration findings, the patient was admitted in our surgical department with restricted oral intake, fluidotherapy and prophylactic antibiotic. Since NGT placement, clinical improvement was observed with disappearance of abdominal distension. NGT was unproductive in 3 days and on the 6th the patient tolerated oral intake well. Radiological controls showed marked improvement on pneumatosis and retroperitoneum, and the patient was discharged on the 9th day.

Discussion

Pneumatosis intestinalis (PI) is a radiological finding representing the presence of gas in the bowel, independently of the

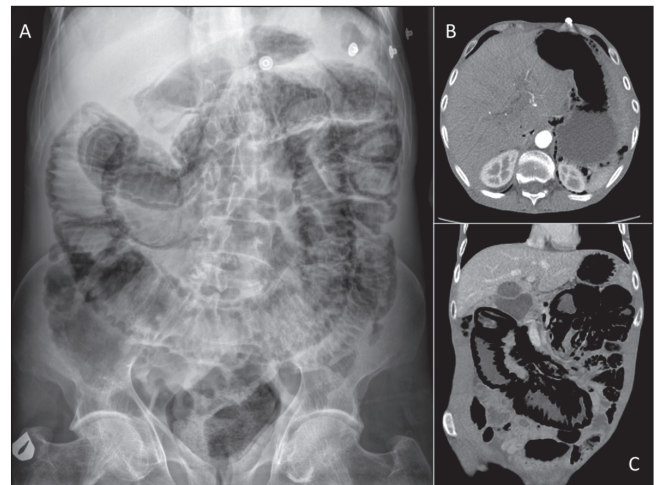


Fig. 1. A. Plain abdominal X-ray showing distended small bowel loops and pneumatosis, this was also observed in the stomach. B-C. CT scan demonstrating retroperitoneum and extensive gastric (B) and small bowel (C) pneumatosis.

cause or location (1). Its appearance in the setting of a CD patient is extremely rare, and its development in a patient with SAMS have not been reported previously (2). PI is a multifactorial disease, mechanisms involved in intramural gas formation included bowel necrosis and mucosal disruption or with increased permeability for gas (bacterial, intraluminal or pulmonary) (3-5).

Instead, more than 60 diseases and benign conditions have been identified, bowel necrosis is the most common and life-threatening cause of PI, and often is presented as an acute abdomen (5). In contrast to this, the benign causes of PI usually produce mild (or absent) abdominal symptoms, without septic signs or other TC abnormalities than pneumatosis (4).

Most-related risk factors observed in CD patients with PI are gluten ingestion and anti-inflammatory drug use; this last was presented in our patient (2). However, latest patient symptoms were in relation to previous history of intense vomiting attributed to SMAS. Also, unusual locations of air in the gastric wall and in the retroperitoneum, similar to duodenal perforations, make us unable to reject duodenal wall disruption due to SMAS as the cause of PI.

When a PI is diagnosed, treatment of predisposing conditions, if exists, is the basis of the patient's management. It is known that in patients diagnosed with PI who not underwent surgery, liver disease and sepsis increase risk of death. (6) However, as we have seen, a gastrointestinal massive pneumatosis in a setting of an asymptomatic patient, even accompanied with retroperitoneum, can be managed conservatively. Initial surgical

exploration in these patients, instead clinical alarm signs appear, should be avoided.

Aleix Martínez-Pérez, Ramón Trullenque-Juan,
Sandra Santarrufina-Martínez and Ernesto Armañanzas-Villena

*Department of General Surgery and Digestive Diseases.
Hospital Universitario Doctor Peset. Valencia, Spain*

References

1. Lassandro F, Valente T, Rea G, et al. Imaging assessment and clinical significance of pneumatosis in adult patients. *Radiol Med* 2015;120:96-104. DOI: 10.1007/s11547-014-0461-5
2. Nathan H, Singhal S, Cameron JL. Benign pneumatosis intestinalis in the setting of celiac disease. *J Gastrointest Surg* 2006;10:890-4. DOI: 10.1016/j.gassur.2005.11.004
3. Pear BL. Pneumatosis intestinalis: A review. *Radiology* 1998;207:13-9. DOI: 10.1148/radiology.207.1.9530294
4. Khalil PN, Huber-Wagner S, Ladurner R, et al. Natural history, clinical pattern, and surgical considerations of pneumatosis intestinalis. *Eur J Med Res* 2009;14:231-9. DOI: 10.1186/2047-783X-14-6-231
5. St. Peter SD, Abbas MA, Kelly KA. The spectrum of pneumatosis intestinalis. *Arch Surg* 2003;138:68-75. DOI: 10.1001/archsurg.138.1.68
6. Greenstein AJ, Nguyen SQ, Berlin A, et al. Pneumatosis intestinalis in adults: Management, surgical indications, and risk factors for mortality. *J Gastrointest Surg* 2007;11:1268-74. DOI: 10.1007/s11605-007-0241-9