

## Letters to the Editor

### Pylephlebitis and liver abscesses secondary to acute advanced appendicitis

*Key words: Appendicitis. Liver abscess. Pylephlebitis (thrombosis).*

Dear Editor,

Currently, pylephlebitis (septic thrombophlebitis of the porto-mesenteric veins) and liver abscesses are exceptional complications of acute advanced appendicitis.

#### Case report

A 53-year-old male patient consulted our service for distension, abdominal pain and general malaise for one month. The patient was in regular general condition with fever, hypotension, pain in right hemiabdomen, and hepatomegaly. Laboratory testing revealed a leukocyte count of  $33,000 \times 10^6/L$ , dissociated cholestasis and lactic acid concentration of 43.7 mg/dL. Abdominal computed tomography (CT) showed mesenteric-portal thrombosis, multiple liver abscesses and an inflammatory process in the right iliac fossa (RIF) suggestive of acute appendicitis (Fig. 1). Antibiotic treatment with Meropenem® was started, and later switched to Ceftriaxona®-Metronidazol®, based on blood culture results (multisensitive *Escherichia coli* and *Bacteroides fragilis*). Initially, a non-surgical approach was adopted and anticoagulation with low-molecular-weight heparin treatment was administered.

During the first days, the patients developed ascites with transudate characteristics, negative culture and occurrence of collat-

eral venous circulation in abdominal wall. Ascites was suspected in a context of portal thrombosis (presinusoidal) as the patient showed no signs of underlying chronic liver disease. Depletion therapy and serum albumin treatment were initiated with a good response.

Control CT revealed global radiographic improvement but no significant changes in the thrombosis.

Five weeks after admission, the patient was discharged on oral anticoagulant and amoxicillin-clavulanic acid for one month. Control CT performed at six months showed persistence of thrombosis and anticoagulation treatment was continued. The patient now receives regular follow-up at our outpatient clinic.

#### Discussion

Although acute appendicitis is a frequent emergency (7%) (1), such advanced cases are currently exceptionally rare (2,3). Clinical diagnosis of pylephlebitis may be missed in the presence of other abdominal infections. Abdominal CT is the most reliable diagnostic tool (2,3).

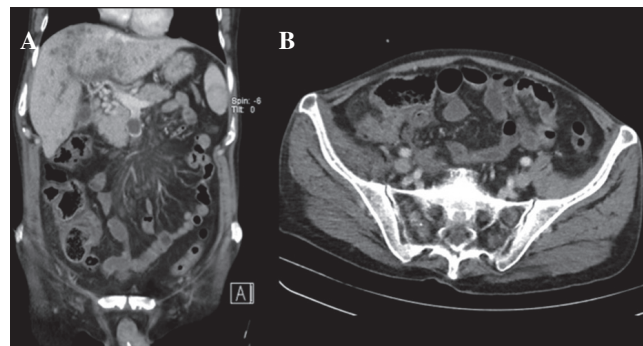


Fig. 1. Initial CT: A. Inflammatory process in right iliac fossa suggestive of acute advanced appendicitis. B. Thrombosis of the superior mesenteric vein, liver abscesses.

Management of this condition is based on 3 principles:

1. Control of the abdominal septic focus. Although appendectomy is considered the treatment of choice for acute appendicitis (4,5), conservative management is contemplated in cases of advanced appendicitis (plastron and/or intraabdominal abscess). Some authors (6) report better results with a conservative approach. Yet the superiority of the exclusively medical conservative treatment of advanced appendicitis has not been demonstrated to date.
2. Resolution of liver abscesses with empirical intravenous antibiotics for 2 weeks (considering that *E. coli* and *B. fragilis* are frequently isolated in such cases) associated with oral antibiotics for a further 4-6 weeks (7), adjusted to antibiogram results, assessing the need for percutaneous drainage.
3. Treatment of pylephlebitis (acute portal vein thrombosis) with early anticoagulation. A recently published study (8) observed a more favourable evolution in patients who received early anticoagulation compared to those who on antibiotics only. Antibiotics associated with anticoagulant seem to accelerate the process of recanalisation (9). The rate of complete recanalisation of portal thrombosis (PT) treated with anticoagulation is 22-45% while that of partial recanalisation is 15-35% (10).

Finally, we wish to stress that the management of these patients is complex and requires multidisciplinary management.

Anna Serracant-Barrera<sup>1</sup>, Heura Llaquet-Bayo<sup>1</sup>,  
 Jordi Sánchez-Delgado<sup>2,3</sup>, Andreu Romaguera-Monzonis<sup>1</sup>,  
 Blay Dalmau-Obrador<sup>2</sup>, Natàlia Bejarano-González<sup>1</sup>,  
 Ana María Navas-Pérez<sup>4,5</sup>, Eva Llopart-Valdor<sup>4</sup>,  
 Francisco Javier García-Borobia<sup>1</sup> and Salvador Navarro-Soto<sup>1</sup>

<sup>1</sup>Department of General and Gastroenterological Surgery.

<sup>2</sup>Digestive Diseases Unit. Unit of Hepatology. Hospital

de Sabadell. Corporació Sanitària Parc Taulí. Institut  
 Universitari Parc Taulí – Universitat Autònoma de Barcelona.  
<sup>3</sup>Centro de Investigación Biomédica en Red de enfermedades  
 hepáticas y digestivas (CIBERehd). <sup>4</sup>Critical Care Area.  
 Hospital de Sabadell. Corporació Sanitària Parc Taulí. Institut  
 Universitari Parc Taulí – Universitat Autònoma de Barcelona.  
<sup>5</sup>Centro de Investigación Biomédica en Red de enfermedades  
 respiratorias (CIBERes). Spain

## References

1. Tellado JM, Sitges-Serra A, Barcenilla F, et al. Pautas de tratamiento antibiótico empírico de las infecciones intraabdominales. *Emergencias* 2005;17:221-7.
2. Álvarez M, Rodrigo S, González JJ, et al. Pileflebitis tras apendicitis aguda. *Rev Esp Enferm Dig* 2007;99:49-60.
3. Granero P, Raposo L, Moreno M, et al. Pileflebitis como complicación de apendicitis aguda. *Rev Esp Enferm Dig* 2010;102:144-8.
4. Ruffolo C, Fiorot A, Pagura G, et al. Acute appendicitis: What is the gold standard of treatment? *World J Gastroenterol* 2013;19:8799-807.
5. Ansaloni L, Catena F, Coccolini F, et al. Surgery versus conservative antibiotic treatment in acute appendicitis: A systematic review and meta-analysis of randomized controlled trials. *Digestive Surgery* 2011;28:210-21.
6. Simillis C, Symeonides P, Shorthouse AJ, et al. A meta-analysis comparing conservative treatment versus acute appendectomy for complicated appendicitis (abscess or phlegmon). *Surgery* 2009;147:818-29.
7. Reid-Lombardo KM, Khan S, Sclabas G. Hepatic cysts and liver abscess. *Surg Clin North Am* 2010;90:679-97.
8. Kanellopoulou T, Alexopoulou A, Theodossiades G, et al. Pylephlebitis: An overview of non-cirrhotic cases and factors related to outcome. *Scand J Infect Dis* 2010;42:804-11.
9. Hall TC, Garcea G, Metcalfe M, et al. Impact of anticoagulation on outcomes in acute non-cirrhotic and non-malignant portal vein thrombosis: A retrospective observational study. Impact of anticoagulation in acute non-cirrhotic and non-malignant portal vein thrombosis: A retrospective observational study. *Hepato-Gastroenterology* 2013;60:317-23.
10. Tripodi A, Anstee QM, Sogaard KK. Hypercoagulability in cirrhosis: Causes and consequences. *J Thromb Haemost* 2011;9:1715-23.