

## PICTURES IN DIGESTIVE PATHOLOGY

### Acute abdomen from duodenal diverticulitis. A case report

Antonio José Fernández-López, Miguel González-Valverde, Nuria Martínez-Sanz, María, Encarnación Tamayo-Rodríguez and Antonio Albarracín-Marín-Blázquez

Department of General Surgery. Hospital General Universitario Reina Sofía de Murcia. Murcia, Spain

Duodenal diverticulitis is an uncommon though clinically significant complication that may be mistaken for other differently managed disorders.

An 82-year-old male with a history of hypertension and left hemicolectomy for colonic adenocarcinoma presented with pain in the epigastrium and right hypochondrium of 12 hours duration. He had fever at 38.7 °C, and the physical examination revealed tenderness in the right hypochondrium with a positive Murphy's sign. His CBC showed  $16.7 \times 10^9$  cells/L (88% neutrophils). An abdominal sonogram, supplemented with a CT scan, revealed duodenal diverticulitis around the ampulla and gallbladder inflammation by contiguity (Fig. 1).

The clinical picture remitted completely following antibiotic therapy (amoxicillin-clavulanic) for 7 days. Follow-

up sonograms and CT scans showed improved diverticulitis in the absence of other intra-abdominal complications. The patient was discharged symptom-free but returned on two occasions with the same diagnosis, which led to diverticular resection and cholecystectomy. After 6 months the patient remains asymptomatic.

The duodenum is the second most common site of diverticula in the digestive tract (1-2%), after the colon (5-60%) (1-3). Most common complications include diverticulitis (20-25%), bleeding and perforation; bile obstruction and obstructive pancreatitis are more uncommon (4). Duodenal diverticulitis remains underdiagnosed because, in the absence of pathognomonic data, it is usually mistaken for other intra-abdominal conditions (4). The picture is usually associated with other gastrointestinal manifestations, hence the benefit of reduced differential diagnoses such as cholecystitis, retrocecal appendicitis, perforated duodenal ulcer, pancreatitis, pancreatic pseudocysts and neoplasms, infected enteric duplication cyst, and duodenitis from trauma or Crohn's disease (1,2). CT is the ideal diagnostic test for upper GI tract diverticula (4). Surgery is the definitive therapy with diverticulectomy or duodenal resection.

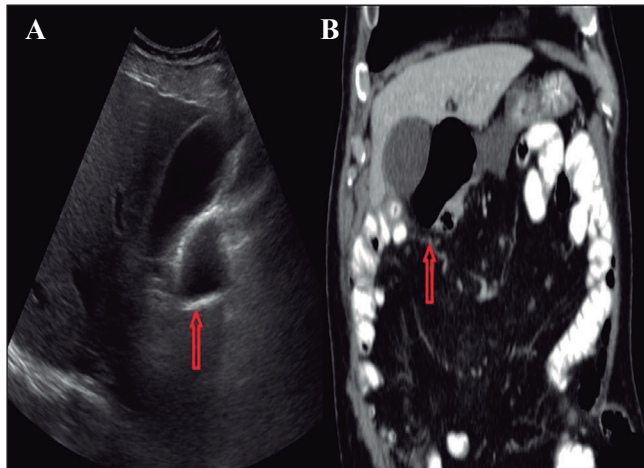


Fig. 1. A. Abdominal sonogram showing a stone-free gallbladder with thickened walls and a large diverticulum in the first portion of the duodenum, consistent with duodenal diverticulitis. B. Tomographic image of acute diverticulitis with increased peridiverticular attenuation touching the gallbladder.

#### REFERENCES

1. Kassir R, Boueil-Bourlier A, Baccot S, et al. Jejuno-ileal diverticulitis: Etiopathogenicity, diagnosis and management. *Int J Case Reports* 2015;10:151-3. DOI: 10.1016/j.ijscr.2015.03.044
2. Minicis S, Antonini F, Belfori V, et al. Small bowel diverticulitis with severe anemia and abdominal pain. *World J Clin Cases* 2015;3:462-5. DOI: 10.12998/wjcc.v3.i5.462
3. Rodríguez M, Artigas V, Trías M, et al. Enfermedad diverticular: revisión histórica y estado actual. *Cir Esp* 2001;70:253-60. DOI: 10.1016/S0009-739X(01)71893-3
4. Schroeder TC, Hartman M, Heller M, et al. Duodenal diverticula: potential complications and common imaging pitfalls. *Clin Radiol* 2014;69:1072-6. DOI: 10.1016/j.crad.2014.05.103