1130-0108/2016/108/12/815-816
Revista Española de Enfermedades Digestivas

Rev Esp Enferm Dig
2016, Vol. 108, N.º 12, pp. 815-816

PICTURES IN DIGESTIVE PATHOLOGY

Jejunitis secondary to Duodopa® probe, a different complication

Marta Magaz-Martínez, José Luis Martínez-Porras, Borja Oliva and Luis Abreu

Gastroenterology and Hepatology Department. Hospital Universitario Puerta de Hierro. Majadahonda. Madrid, Spain

CASE REPORT

We present the case of a 68-year-old woman with advanced Parkinson's disease, with treatment via Duodopa® pump therapy (levodopa/carbidopa) for two years. She presented with abdominal pain for a week. The abdominal CT showed a distension of proximal-intermediate jejunum loops, associating trabeculation of mesenteric fat.

We performed an enteroscopy until the proximal jejunum, which showed ulcerated bedsores due to decubitus in the path of the probe (Fig. 1), aiming the probe rod (Fig. 2), without reaching its distal end due to large angulation. Upon removal of the internal probe, we observed at its end the presence of material compatible with phytobezoar (Fig. 3), which prevents their extraction by the stoma performed orally. A new internal probe was placed into the second duodenal portion (free of injuries). The patient was treated with prophylactic antibiotic therapy with good results.

DISCUSSION

Treatment with continuous infusion of intraduodenal Duodopa® is indicated in patients with advanced Parkinson's disease who have not responded to conventional treatment. Most complications are similar to a conventional gastrostomy probe. The phytobezoar detected in our case is rare and may be associated with cases of intestinal hypomotility; in fact, it is not uncommon for patients with Parkinson's disease to take prokinetics, which, in the event

Fig. 2. We aimed the probe rod without reaching its distal end due to large angulation.

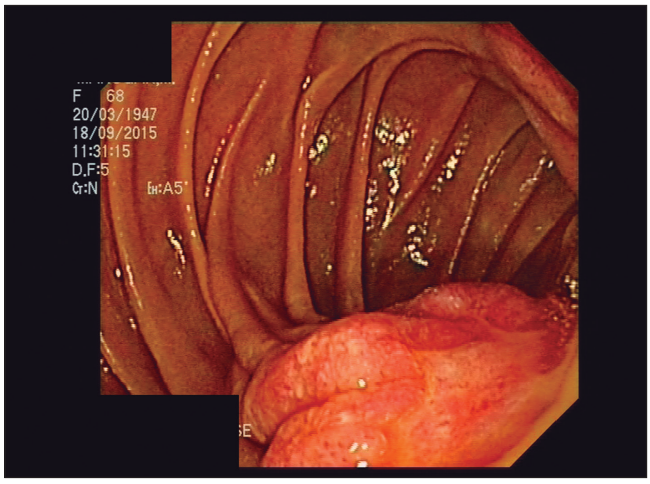

Fig. 1. Enteroscopy until proximal jejunum, which shows ulcerated bedsores due to decubitus in the path of the probe.

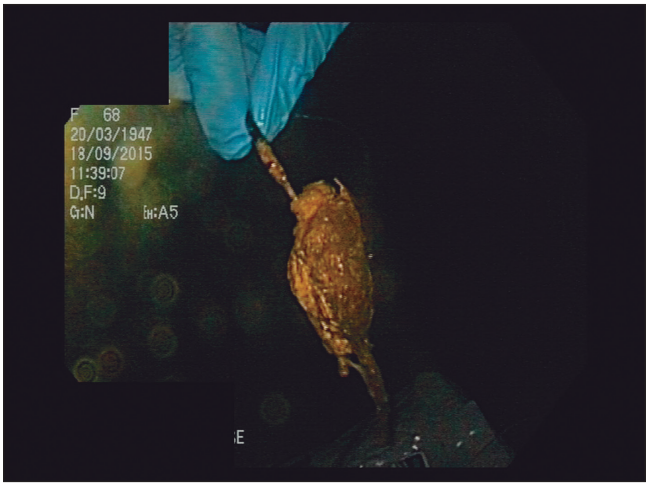

Fig. 3. Upon removal of the internal probe we observed at its end the presence of material compatible with phytobezoar.

of bezoar, aggravates the situation (since it generates aggressive peristalsis). Furthermore, this case presented ulcerated jejunal mucosa due to two different reasons (the probe was taut, and the decubitus bezoar). A CT scan three months later showed complete resolution of the initial changes.

REFERENCES

1. Antonini A1, Mancini F, Canesi M, et al. Duodenal levodopa infusion improves quality of life in advanced Parkinson's disease. Neurodegener Dis 2008;5:244-6. DOI: 10.1159/000113714
2. Bianco G, Vuolo G, Ulivelli M, et al. A clinically silent, but severe, duodenal complication of duodopa infusión. J Neurol Neurosurg Psychiatry 2012;83:668-70. DOI: 10.1136/jnnp-2011-301984
3. Nyholm D1. Duodopa® treatment for advanced Parkinson's disease: A review of efficacy and safety. Parkinsonism Relat Disord 2012;18:916-29. DOI: 10.1016/j.parkreldis.2012.06.022