1130-0108/2016/108/8/495-496
Revista Española de Enfermedades Digestivas

Rev Esp Enferm Dig
2016, Vol. 108, N.º 8, pp. 495-496

PICTURES IN DIGESTIVE PATHOLOGY

Common bile duct perforation sealed with a metal fully-covered stent

Jesús García-Cano[1], Ramón Ferri-Bataller[2] and Carmen Julia Gómez-Ruiz[1]

Departments of [1]Digestive Diseases and [2]Internal Medicine. Hospital Virgen de la Luz. Cuenca, Spain

CASE REPORT

A 79-yr-old woman underwent ERCP to treat symptomatic common bile duct stones (CBDS). Biliary endoscopic sphincterotomy (BES) was performed. Due to large CBDS size, extraction through BES was not possible. Endoscopic papillary large balloon dilation (EPBD) was deemed to be appropriate to enlarge BES in order to achieve CBDS extraction. Dilation balloon was inflated up to 16.5 mm in diameter (Fig. 1) and the common bile duct (CBD) was cleared after several extraction balloon sweeps. The procedure spanned for 25 minutes and was completed successfully.

Right eye swelling was noticed by her relatives upon patient's returning to her ward. Medical exam revealed also subcutaneous air with crepitation. A perforation was suspected. A CT scan (Fig. 2) showed large amount of air in the right retroperitoneal cavity and within the mediastinum. A small right pneumotorax was also diagnosed.

ERCP radiologic images were revised (Fig. 1). It was noticed that after balloon inflation to its maximum diameter, the CBDS was trapped and pushed against the CBD wall, resulting in perforation (Figs. 1 B, C and D). Immediately, the patient was transferred to the OR. An ERCP was performed under general anesthesia with orotracheal intubation and a 10 mm in diameter, 8 cm in length fully covered Wallflex stent was inserted in the CBD. After 24 hours in the ICU, the patient was transferred to ward. A control CT scan showed reduction in the ectopic air amount (Fig. 3). The patient did well and was discharged 7 days later. Stent removal was scheduled after two months.

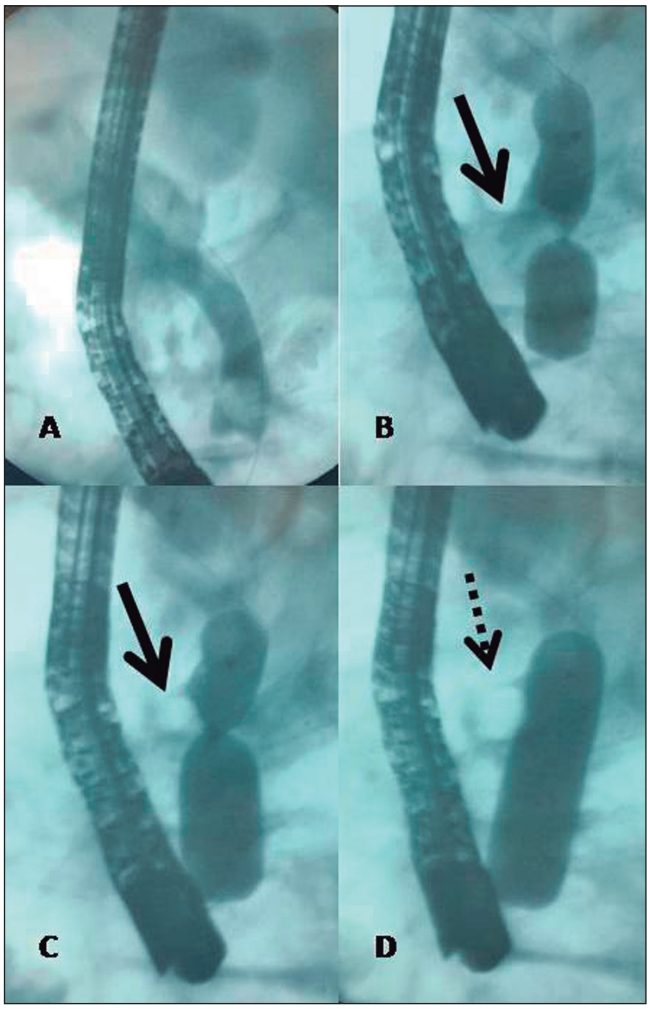

Fig. 1. A. A large common bile duct stone could not be extracted through a biliary sphincterotomy. B. Balloon biliary sphincterotomy dilation up to 16.5 mm was carried out. C. Balloon inflation was inadvertently performed against the common bile duct stone. D. A small perforation was seen with common bile duct wall rupture.

DISCUSSION

Biliary sphincterotomy dilation is a generalized procedure to extract difficult CBDS (1,2). Pancreatitis rate is low because the inflated balloon seems to direct its expansion force more to the bile duct, instead than to the pancreatic one. Hemorrhage is the most frequent severe complication. Perforation rate is low, but balloon diameter must be matched with those of the CBD. This case underlines another critical point, not to overdistend the CBD adding the stone diameter to the inflated balloon diameter. Recently, EPLBD with balloons larger than 15 mm in diameter appear to increase the risk of adverse events (3).

Diagnosis was made almost immediately in this case due to air passage to the neck and head through the dia-

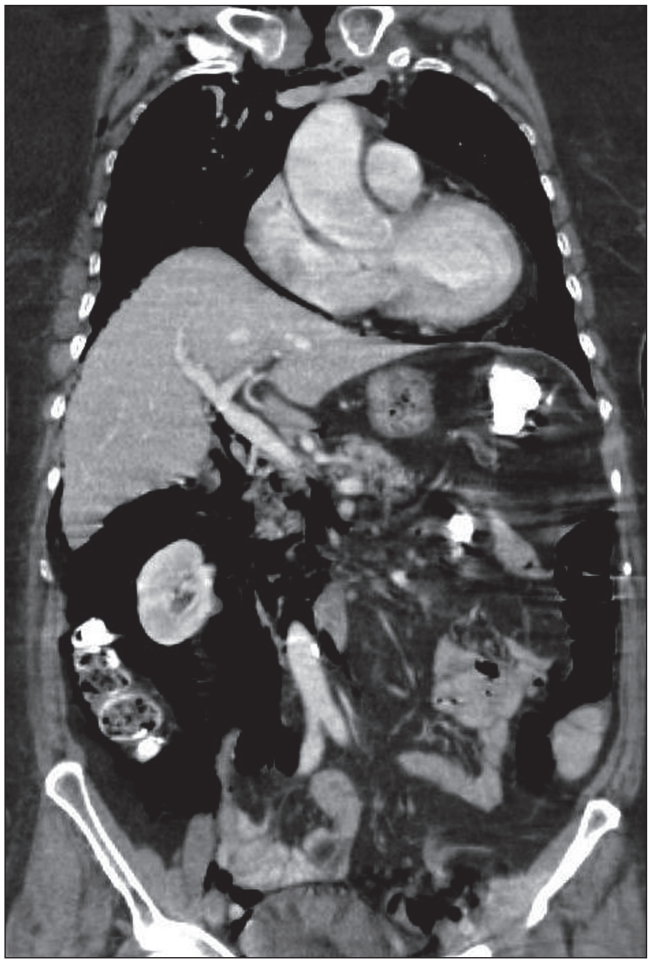

Fig. 2. CT scan showing a large amount of ectopic air in the retroperitoneum. Due to hiatal hernia presence, air was seen also in the mediastinum, neck and head.

phragmatic hiatus containing a large hiatal hernia. It is expected this type of peripapillary perforations heal satisfactorily when they are sealed by means of fully-covered metal stents.

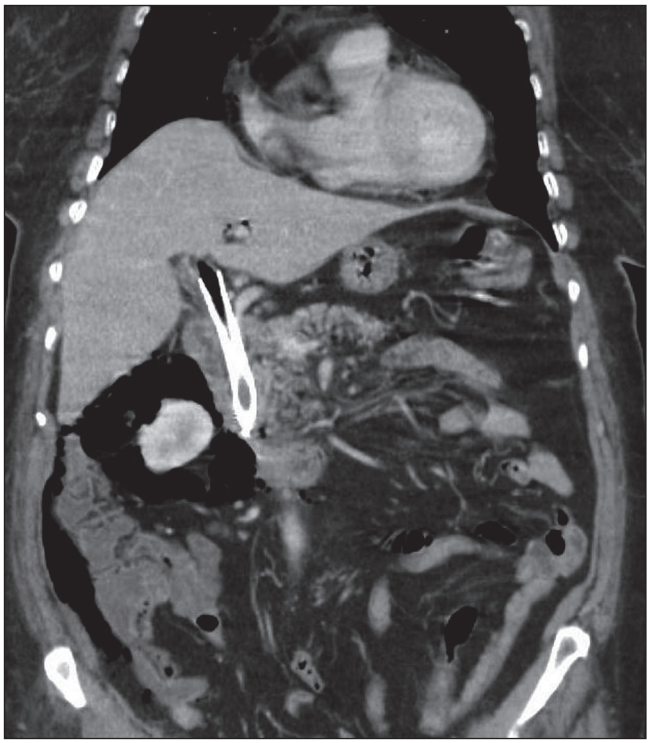

Fig. 3. Two hours after the initial ERCP a fully-covered biliary metal stent was inserted to seal common bile duct wall perforation. Patient's condition improved.

REFERENCES

1. García-Cano J, Taberna-Arana L, Jimeno-Ayllón C, et al. Biliary sphincterotomy dilation for the extraction of difficult common bile duct stones. Rev Esp Enferm Dig 2009;101:541-5. DOI: 10.4321/S1130-01082009000800004
2. Espinel J, Pinedo E. Large balloon dilation for removal of bile duct stones. Rev Esp Enferm Dig 2008;100:632-6.
3. Kim JH, Yang MJ, Hwang JC, et al. Do balloons larger than 15 mm size increase the risk of adverse events in endoscopic large balloon dilation? Gastrointest Endosc 2015;81:AB360. DOI: 10.1016/j.gie.2015.03.598