1130-0108/2017/109/1/79-80
Revista Española de Enfermedades Digestivas

Rev Esp Enferm Dig
2017, Vol. 109, N.º 1, pp. 79-80

Letters to the Editor

Rectal neuroendocrine neoplasia: a rare tumour

Key words: Rectal. Neuroendocrine. Neoplasia.

DOI: 10.17235/reed.2016.4351/2016

Dear Editor,

Colorectal neuroendocrine tumors are rare (0.3% of colorectal cancers) (1).

Case report

A 78 year old man with a history of hypertension, heart disease, pacemakers, prostate adenocarcinoma treated with radiotherapy.

On examination for rectal bleeding, a colonoscopy was performed and a 28 mm ulcerated neoformation with a malignant appearance was found at 5 cm of the anal margin. An echo-endoscopy (Fig. 1) revealed infiltration of the muscular layer with an area of loss in the cleavage plane and fraying of the perirectal fat, suggestive of tumor infiltration (T3). No lymph node infiltration or metastasis was identified by CAT.

Radiotherapy treatment was ruled out as the patient had previously received radiotherapy of the prostate, thus a proctectomy was performed with a mesorectal resection and Hartmann intervention.

The pathology examination revealed a large cell neuroendocrine carcinoma with numerous implants in the perirectal adipose tissue and lymph metastasis in 2 lymph nodes (pT4aN1b). The tumor was positive for synaptophysin, chromogranin and CD 56 with a Ki-67 proliferation index of 50% (Fig. 2).

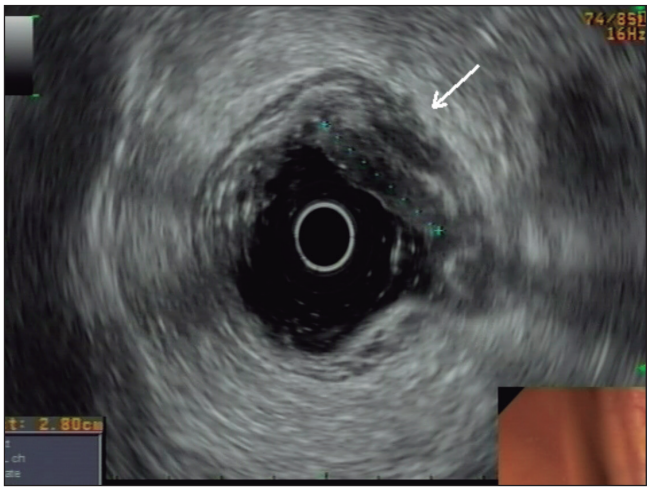

Fig. 1. Echoendoscopic image.

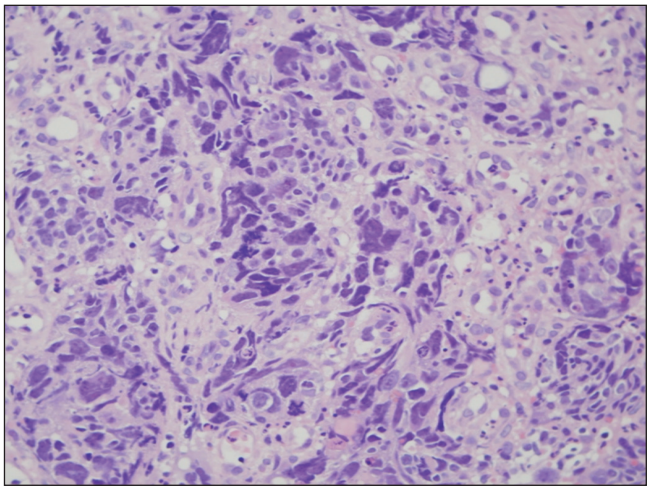

Fig. 2. Histologic image.

One month later, during routine follow-up, the patient was found to be recovering well.

Discussion

The incidence of neuroendocrine tumors of the colon and rectum is increasing (2.2% annually) compared to the downward trend of adenocarcinoma (-3.1%). Survival at five years is 16.3%, and even lower (10%) in tumors with a small cell phenotype (2).

Most of them are clinically silent, as carcinoid syndrome is very rare (0.7%) (3).

The frequency of metastasis is related to the size of the tumor and the most frequent location is the hepatic lymph node (4).

Treatment is endoscopic resection on 1-2 cm lesions without muscular, lymphovascular or lymph node infiltration, and surgery for older (5) patients with radio or chemotherapy in metastatic disease.

Histological data such as the mitotic index and Ki-67 proliferation are used to determine the aggressiveness and the need for subsequent periodic endoscopic monitoring.

Marina de-Benito-Sanz, Javier Santos-Fernández
and Mª Henar Núñez-Rodríguez

Department of Digestive Diseases. Hospital Río Hortega. Valladolid, Spain

References

1. Villalonga R, Espín Basany E, López Cano M, et al. Carcinomas neuroendocrinos de colon y recto: experiencia de una unidad en seis años. Rev Esp Enferm Dig 2008;100:11-6. DOI: 10.4321/S1130-01082008000100003
2. Shafqat H, Ali S, Salhab M, et al. Survival of patients with neuroendocrine carcinoma of the colon and rectum: A population-based analysis. Dis Colon Rectum 2015;58(3):294-303. DOI: 10.1097/DCR.0000000000000298
3. Caplin M, Sundin A, Nillson O, et al. ENETS consensus guidelines for the management of patients with digestive neuroendocrine neoplasms: Colorectal neuroendocrine neoplasms. Neuroendocrinology 2012;95:88-97 DOI: 10.1159/000335594
4. Modlin IM, Lye KD, Kidd M. A 5-decade analysis of 13,715 carcinoid tumors. Cancer 2003;97:934-59. DOI: 10.1002/cncr.11105
5. Varas Lorenzo M. J. Neuroendocrine tumors: Fascination and infrequency. Rev Esp Enferm Dig 2009;101(3):195-202. DOI: 10.4321/S1130-01082009000300006