

## Pancreatic stent insertion after an unintentional guidewire cannulation of the pancreatic duct during ERCP

Jesús García-Cano, Miriam Viñuelas-Chicano, María del-Moral-Martínez, Marta Muñiz-Muñoz, Claudio Murillo-Matamoras, Miguel Suárez-Matías, Laura Valiente-González, Teresa Martínez-Pérez, Raquel Martínez-Fernández, Carmen Julia Gómez-Ruiz, José Ignacio Pérez-García and Julia Morillas-Ariño

*Department of Digestive Diseases. Hospital Virgen de la Luz. Cuenca, Spain*

**Received:** 12/09/2017 · **Accepted:** 24/01/2018

**Correspondence:** Jesús García-Cano. Department of Digestive Diseases. Hospital Virgen de la Luz. C/ Hermandad Donantes de Sangre, 1. 16002 Cuenca, Spain. **e-mail:** jgcl7@live.com

### ABSTRACT

**Introduction:** the guidewire (GW) may enter the pancreatic duct during common bile duct (CBD) cannulation attempts in endoscopic retrograde cholangiopancreatography (ERCP). After GW passage into the pancreas, the most effective maneuver for CBD cannulation and pancreatitis prevention has not been determined.

**Aim:** to study CBD cannulation and post-ERCP pancreatitis rates when a pancreatic stent is inserted after an unintentional GW cannulation of the pancreatic duct.

**Material and methods:** a retrospective analysis of patients undergoing ERCP for biliary drainage that were included prospectively into a database. After unintentional GW cannulation of the pancreatic duct, a straight 5-Fr and 4-cm long plastic stent was inserted. The stents had no internal flaps to facilitate expulsion. CBD cannulation attempts were made above the stent. A pancreatic sphincterotomy was performed in patients older than 60 years before stent insertion.

**Results:** a total of 46 pancreatic stents were inserted during 154 ERCP (29.8%) procedures. In the stent group, CBD cannulation was accomplished in 44/46 (95.6%) subjects. A total of 21/46 (45.6%) pancreatic sphincterotomies were performed. Only 1/46 (2.17%) mild pancreatitis cases were observed and most stents were spontaneously expelled.

**Conclusions:** in this study, the CBD was eventually reached with the insertion of a plastic pancreatic stent after an unintentional GW passage into the pancreatic duct while attempting a CBD cannulation. No adverse events were observed following pancreatic stent insertion.

**Key words:** Pancreatic stent. ERCP cannulation. Post-ERCP pancreatitis.

### INTRODUCTION

The vast majority of endoscopic retrograde cholangiopancreatography (ERCP) procedures are intended to treat biliary conditions. Currently, many endoscopists use a sphincterotome loaded with a guidewire (GW) for common bile duct (CBD) cannulation. In this setting, inadvertent GW passage into the main pancreatic duct (MPD) is a common occurrence. This is due to the horizontal position of the pancreas compared to the vertical CBD axis.

Several maneuvers may be performed following GW passage into the MPD: a) GW removal and repeat attempts at CBD cannulation; b) a pancreatic sphincterotomy may be performed in order to facilitate access to the CBD; c) the GW is left within the MPD and CBD cannulation over the GW is attempted (double GW technique); and d) a pancreatic stent is inserted and access to the CBD may be improved by attempting cannulation above the stent (1). No conclusive studies clearly show which technique is better. Therefore, the maneuver is chosen according to the endoscopist preference that also considers the available material. Usually, the placement of a plastic pancreatic stent after GW passage into the MPD is recommended in order to prevent post-ERCP pancreatitis (2).

The aim of the study was to investigate CBD cannulation and post-ERCP pancreatitis rates when a pancreatic plastic stent was placed following an unintentional GW cannulation of the pancreatic duct during CBD cannulation attempts.

García-Cano J, Viñuelas-Chicano M, Del-Moral-Martínez M, Muñiz-Muñoz M, Murillo-Matamoras C, Suárez-Matías M, Valiente-González L, Martínez-Pérez T, Martínez-Fernández R, Gómez-Ruiz CJ, Pérez-García JI, Morillas-Ariño J. Pancreatic stent insertion after an unintentional guidewire cannulation of the pancreatic duct during ERCP. *Rev Esp Enferm Dig* 2018;110(7):416-420.

**DOI:** 10.17235/reed.2018.5230/2017

## MATERIAL AND METHODS

A retrospective analysis was performed of patients prospectively included in a specific ERCP database. All patients underwent ERCP for the purpose of CBD drainage. ERCPs were performed by two endoscopists (JGC and MVC) who had previously performed a total of 3,500 ERCP procedures. They also had experience in the placement of plastic pancreatic stents (3).

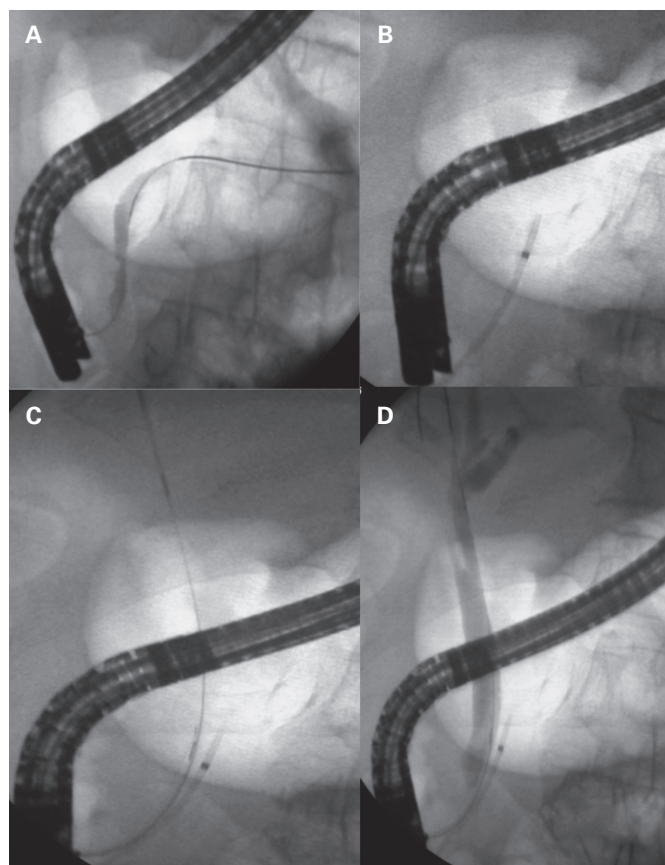
A sphincterotome (CleverCut 3V®, KD411M-0720, Olympus) with a 0.025" GW (Visiglide®, Olympus) was used for cannulation. The GW was handled by the endoscopist performing the ERCP. A small amount of contrast medium was injected during ERCP to confirm the GW position if the fluoroscopic images were unclear with regard to which duct had been cannulated (Fig. 1A). A pancreatic stent was then inserted (Fig. 1B) and repeat CBD cannulation attempts were made above the stent (Fig. 1C and D). A Fogarty balloon instead of a pushing catheter was used to push the stent over the GW. Furthermore, the Fogarty balloon was occasionally used to remove stones from the CBD.

Advanix® (Boston Scientific) 5-Fr, 4cm long plastic pancreatic stents were used. These stents have no internal flaps to facilitate spontaneous expulsion (Fig. 2A) and have two markers at both ends. The inner radiopaque marker is useful to show via fluoroscopy the pancreatic axis during CBD

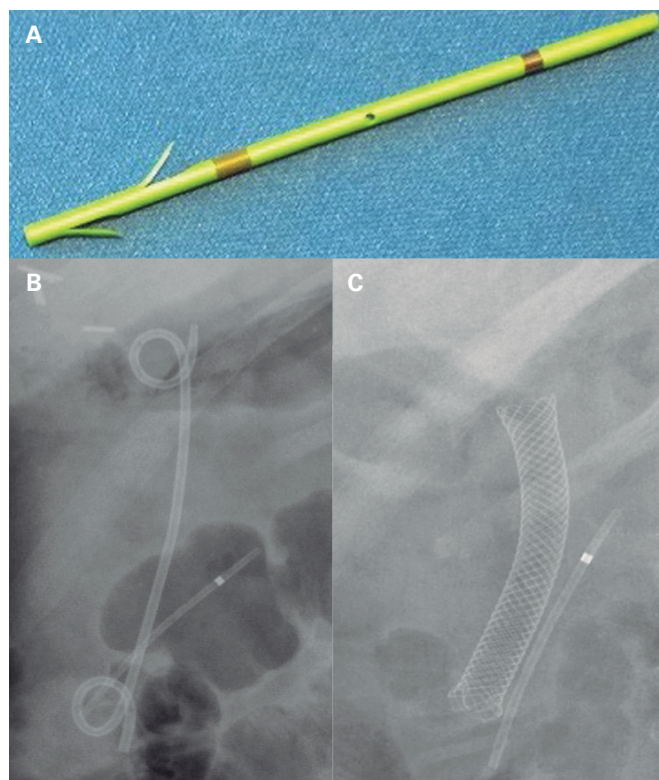
cannulation attempts over the stent and also to assess whether the stent had been expelled in the control x-ray films (Fig. 2C and B). The external marker is used for endoscopic purposes only. A 4 cm length was chosen so that the stent could be placed below the pancreatic duct bend present at the junction between the head and neck of the pancreas. This angle is also known as a "genu". A 5-Fr diameter was adequate to achieve effective pancreatic drainage, thus aiding the prevention of post-ERCP pancreatitis (4).

A small pancreatic sphincterotomy was performed in patients older than 60 years of age in order to facilitate the reengagement of the papilla after pancreatic stent insertion by the sphincterotome (Fig. 3). When fluoroscopic images suggested that the GW had passed into the pancreas but had not properly followed the MPD, a small amount of contrast medium was injected and further attempts to advance the GW towards the pancreatic tail were made by gentle GW manipulation. When this failed after three attempts, the GW was withdrawn and subsequent attempts at direct CBD cannulation were made, or a precut was used.

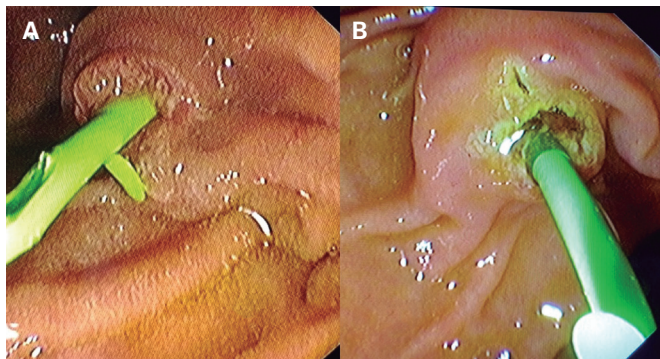
All patients were sedated by an anesthesiologist. Patients had previously signed both the anesthesia and ERCP related informed consent. During the endoscopic procedure, 75 mg of intravenous diclofenac were administered to all



**Fig. 1.** A. Unintentional guidewire passage into the pancreatic duct during biliary cannulation attempts in a patient with an inflammatory papillary stenosis. B. Pancreatic stent insertion. C. Common bile duct cannulation over the pancreatic stent. D. Cholangiography.



**Fig. 2.** A. A straight Advanix® (Boston Scientific) 4-cm, 5-Fr pancreatic stent without inner flaps to facilitate spontaneous expulsion. The exterior marker is for endoscopic visualization, whereas the interior marker is radiopaque. B. Radiological stent visualization after ERCP. C. The pancreatic stent four months after insertion in a benign biliary stricture treated with a fully covered metal stent. The pancreatic stent was spontaneously expelled a few weeks later without any adverse effects.



**Fig. 3.** A. A pancreatic stent inserted without a previous pancreatic sphincterotomy. B. Pancreatic sphincterotomy performed before stent insertion to facilitate the placement of the sphincterotome between the papillary orifice and the stent for a CBD cannulation attempt.

patients. Acute pancreatitis was defined as abdominal pain with a serum amylase increase of at least three times the upper normal limit (5). Quantitative variables are indicated as a mean, range and standard deviation. Qualitative variables are shown as percentages.

## RESULTS

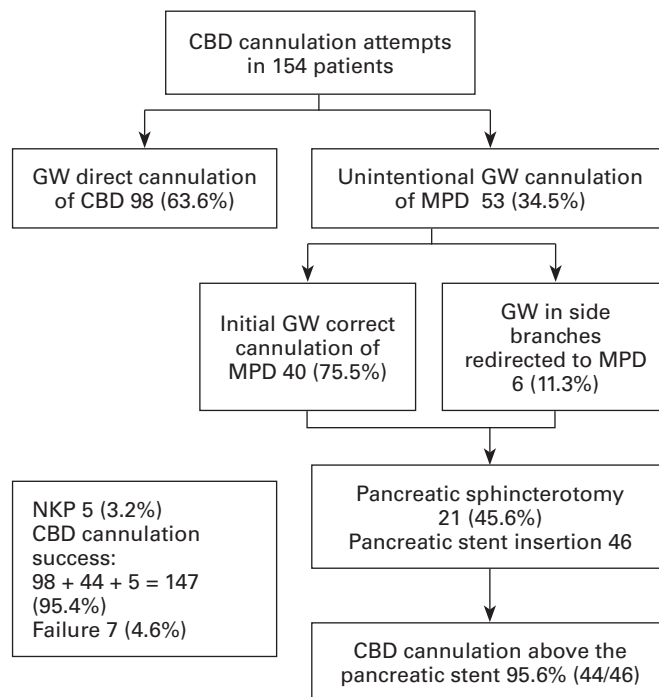
During a 24-month period from January 2015-December 2016, 154 patients underwent an ERCP intended for CBD drainage. Patient characteristics are shown in table 1. Unintentional GW cannulation of the pancreatic duct occurred in 46 (29.8%) patients and a pancreatic stent was inserted (Fig. 4). Following pancreatic stent insertion, CBD cannulation was accomplished in 95.6% (44/46) of subjects. Standardized techniques for biliary drainage were carried out after CBD cannulation. These techniques were not hindered in any case by pancreatic stents.

Following GW insertion into the pancreas and before stent placement, a pancreatic sphincterotomy (Fig. 3) was per-

**Table 1.** Patient characteristics. A pancreatic stent was inserted after an unintentional guidewire passage into the pancreatic duct

|   |                               |
|---|-------------------------------|
| Male/Female                                   | 25/21 (54%/46%)               |
| Age   | 63.23 (SD 18.72), range 26-93 |
| Common bile duct stones                       | 22 (48%)                      |
| Inflammatory papillary stenosis               | 11 (24%)                      |
| Pancreatic cancer                             | 4 (9%)                        |
| Sphincter of Oddi dysfunction                 | 3 (7%)                        |
| Biliary stricture due to chronic pancreatitis | 2 (4%)                        |
| Ampullary tumor                               | 2 (4%)                        |
| Leaks   | 1 (2%)                        |
| Klatskin tumor                                | 1 (2%)                        |

Percentages are rounded.



**Fig. 4.** Outcome flowchart (CBD: common bile duct; GW: guidewire; MPD: main pancreatic duct; NKP: needle-knife papillotomy).

formed in 21 (45.6%) patients older than 60 years of age (mean age, 73.64; SD, 12.43; range, 61-93). The biliary conditions in these patients were as follows: nine CBD stones, five inflammatory papillary strictures, four pancreatic head cancers, one biliary leak, one CBD stricture from chronic pancreatitis, and one Klatskin tumor.

The space between the papillary orifice and the stent was inadequate in one case and a needle-knife papillotomy (NKP) over the stent had to be performed to allow CBD cannulation. The pancreatic stent was dislodged during CBD cannulation attempts in another case. CBD cannulation was eventually possible and the patient had an uneventful ERCP. Two CBD cannulation failures occurred in papillae that were found on a diverticulum edge, which greatly distorted the distal CBD portion. One of these patients had mild pancreatitis (1/46 or 2.17%). This was the only complication reported in the series of patients. Abdominal x-rays were obtained after two weeks for the first 22 patients. Stents still remained in eight patients (37%) and had to be removed via gastroscopy. An abdominal radiograph that was performed for another reason showed a stent that remained four months after insertion (Fig. 2C) but no adverse events were observed.

## DISCUSSION

CBD cannulation was accomplished in this study in 95.6% of cases following a pancreatic stent insertion during a first unintentional GW passage into the pancreatic duct. With this approach, only a single case of post-ERCP pancreatitis was reported. This figure represents a pancreatitis rate of 2.17%, which is significantly lower than the 5.5% post-ERCP pancreatitis rate previously reported in our center (6). In



addition, there were no complications derived from pancreatic stent insertion. Furthermore, stents were spontaneously expelled in most cases. Obviously, further studies are needed in order to compare the current approach of stent insertion in the pancreatic duct after primary CBD cannulation failure with other strategies such as GW removal, a reattempt at direct CBD cannulation or the use of the double GW technique (7) among others. In fact, ERCP is considered as a difficult procedure after a GW has unintentionally passed into the pancreatic duct for a second time according to the European guidelines for the prophylaxis of post-ERCP pancreatitis. Therefore, a GW must be removed from the pancreatic duct after a first unintentional pancreatic cannulation and a second attempt at direct CBD cannulation may be performed (8).

Nakai et al. (2) described GW cannulation of the pancreatic duct as a risk factor for the development of acute post-ERCP pancreatitis. An incidence of pancreatitis of 16.9% was observed when the GW entered the pancreatic duct. This figure increased to 22.1% when a contrast medium was also injected. In this study, non-steroidal anti-inflammatory drugs (NSAID) were not used for pancreatitis prevention and only a few patients had a pancreatic stent. In view of the high rate of post-ERCP acute pancreatitis, the authors recommended the insertion of a pancreatic stent whenever an unintentional GW passage into the pancreatic duct occurs. A pancreatitis rate of 23% was observed in a study by Ito et al. (9) in the group of patients where the GW had entered the pancreatic duct but no stent was inserted, vs 2.9% in the group who received stents. Therefore, the authors recommend that stents be routinely inserted whenever GW passage into the pancreatic duct occurs during CBD cannulation attempts. In the study by Ito et al. (9), a similar stent to that in our study was used (5-Fr, 4-cm stent), although the duodenal portion was not straight and had a pigtail outline. In our study, even though the stent was straight, the stents' external flaps (Fig. 2A) prevented intrapancreatic migration. Other studies such as that of Coté et al. (10) have highlighted the role of pancreatic stents to facilitate CBD cannulation. The authors obtained a CBD cannulation rate of 93.4% after placing a pancreatic stent following an unintentional cannulation of the pancreas. In most cases (79%) CBD cannulation could be achieved over the stent and only a small percentage required a NKP to allow the tip of the sphincterotome to be inserted between the papillary orifice and the stent. In our study, fewer NKPs over the pancreatic stent were used as we tended to use pancreatic sphincterotomy, which widens the papillary orifice.

Having the same endoscopist perform ERCP and handle the GW may be another important factor for the successful outcomes of this study, i.e. a high rate of biliary cannulation with a low pancreatitis incidence. The recent study by Buxbaum et al. (11), which had to be terminated early, compared the results obtained with a GW controlled either by the endoscopist or by an assistant. The pancreatitis rate was much higher when the GW was not handled by the endoscopist. Pancreatic stent cost is another important aspect that should be taken into account (12) even though a single pancreatic stent is probably one of the cheapest tools used in ERCP. The stent can be pushed over the GW with a specific introducing catheter with an extractor balloon (as used in our study) or with the sphincterotome itself. Both the sphincterotome and the GW may be used for repeated

attempts in order to achieve CBD cannulation. However, from a different perspective, a pancreatic stent is one of the cheapest, most useful tools used in ERCP. It allows a high CBD cannulation rate whilst avoiding pancreatitis. Moffatt et al. (13) reported a rate of acute pancreatitis of 3% after removing retained pancreatic stents. Endoscopic procedures were necessary as 71% of stents had internal flaps and, therefore, it was unlikely that spontaneous expulsion could occur. In addition, the stent length was over 4 cm. In our series, only 8/46 (17%) stents were initially extracted after remaining for more than two weeks. Subsequently, spontaneous expulsion tended to occur even though the stents had remained for more than 15 days. No adverse effects were observed (Fig. 2C).

We have been using intravenous diclofenac instead of indomethacin suppositories in our center for many years in order to prevent acute post-ERCP pancreatitis (14). The absence of severe pancreatitis in this study may be attributed to the combination of both of these protective measures, NSAIDs (15-17) and a pancreatic stent. As acute pancreatitis is the most frequent ERCP complication and NSAIDs and pancreatic stents have been shown to reduce pancreatitis rates without causing adverse events, we believe that NSAIDs and pancreatic stents can be used generally. Attempting pancreatic duct cannulation for the sole purpose of stent insertion in order to prevent pancreatitis can be as risky as not placing a stent once the GW has entered the pancreatic duct. In addition, a pancreatic stent can aid the access to the CBD.

The current study has several limitations. It is a retrospective study with a small number of patients. Pancreatic sphincterotomy was performed in only one group of patients and NSAIDs were administered in all cases. Moreover, there was no control group.

In conclusion, the insertion of a plastic pancreatic stent following an unintentional GW passage into the MPD during CBD cannulation attempts assisted in the achievement of a 95.6% rate of CBD cannulation. The stent used in this study was of 5 Fr in diameter, 4 cm in length and with no internal flaps. A single mild pancreatitis case (2.17%) was reported and stent insertion did not result in any adverse events.

## REFERENCES

1. García-Cano J. What is the most cost-effective method for a difficult biliary cannulation in ERCP? *Rev Esp Enferm Dig* 2017;109:171-3. DOI: 10.17235/reed.2017.4863/2017
2. Nakai Y, Isayama H, Sasahira N, et al. Risk factors for post-ERCP pancreatitis in wire-guided cannulation for therapeutic biliary ERCP. *Gastrointest Endosc* 2015;81:119-26. DOI: 10.1016/j.gie.2014.06.005
3. García-Cano J, Godoy-López MA, Taberna-Arana L. Common bile duct access in ERCP over a new plastic pancreatic stent after unintentional pancreatic guidewire cannulation. *Gastrointest Endosc* 2016;83(5S):AB455-6. DOI: 10.1016/j.gie.2016.03.598
4. Afghani E, Akshintala VS, Khashab MA, et al. 5-Fr vs. 3-Fr pancreatic stents for the prevention of post-ERCP pancreatitis in high-risk patients: a systematic review and network metaanalysis. *Endoscopy* 2014;46:573-80. DOI: 10.1055/s-0034-1365701
5. Cotton PB, Lehman G, Vennes J, et al. Endoscopic sphincterotomy complications and their management: an attempt at consensus. *Gastrointest Endosc* 1991;37:383-93. DOI: 10.1016/S0016-5107(91)70740-2

6. García-Cano J, González Martín JA, Morillas Ariño J, et al. Complications of endoscopic retrograde cholangiopancreatography. A study in a small ERCP unit. *Rev Esp Enferm Dig* 2004;96:163-73.
7. Laquiere A, Desilets E, Belle A, et al. Double guidewire endoscopic technique, a major evolution in endoscopic retrograde cholangiopancreatography: results of a retrospective study with historical controls comparing two therapeutic sequential strategies. *Dig Endosc* 2017;29:182-9. DOI: 10.1111/den.12740
8. Dumonceau JM, Andriulli A, Elmunzer BJ, et al. Prophylaxis of post-ERCP pancreatitis: European Society of Gastrointestinal Endoscopy (ESGE) Guideline updated June 2014. *Endoscopy* 2014;46:799-815. DOI: 10.1055/s-0034-1377875
9. Ito K, Fujita N, Noda Y, et al. Can pancreatic duct stenting prevent post-ERCP pancreatitis in patients who undergo pancreatic duct guidewire placement for achieving selective biliary cannulation? A prospective randomized controlled trial. *J Gastroenterol* 2010;45:1183-91. DOI: 10.1007/s00535-010-0268-7
10. Coté GA, Ansstas M, Pawa R, et al. Difficult biliary cannulation: use of physician-controlled wire-guided cannulation over a pancreatic duct stent to reduce the rate of precut sphincterotomy (with video). *Gastrointest Endosc* 2010;71(2):275-9. DOI: 10.1016/j.gie.2009.08.028
11. Buxbaum J, Leonor P, Tung J, et al. Randomized trial of endoscopist-controlled vs. assistant-controlled wire-guided cannulation of the bile duct. *Am J Gastroenterol* 2016;111:1841-7. DOI: 10.1038/ajg.2016.268
12. Hwang HJ, Guidi M, Curvale C, et al. Post-ERCP pancreatitis: early precut or pancreatic duct stent? A multicenter, randomized-controlled trial and cost-effectiveness analysis. *Rev Esp Enferm Dig* 2017;109:174-9. DOI: 10.17235/reed.2017.4565/2016
13. Moffatt DC, Coté GA, Fogel EL, et al. Acute pancreatitis after removal of retained prophylactic pancreatic stents. *Gastrointest Endosc* 2011;73:980-6. DOI: 10.1016/j.gie.2011.01.012
14. García-Cano J, Reyes Guevara AK, Martínez Pérez T, et al. Prevención de la pancreatitis aguda post-CPRE con la administración de diclofenaco intravenoso tras la intervención endoscópica. *Rev Esp Enferm Dig* 2013;105 (Supl.I):106.
15. Hamada T, Nakai Y, Isayama H, et al. Toward routine use of non-steroidal anti-inflammatory drugs for patients undergoing endoscopic retrograde cholangiopancreatography. *Dig Endosc* 2017;29:291-3. DOI: 10.1111/den.12831
16. Patai Á, Solymosi N, Mohácsi L, et al. Indomethacin and diclofenac in the prevention of post-ERCP pancreatitis: a systematic review and meta-analysis of prospective controlled trials. *Gastrointest Endosc* 2017;85:1144-56. e1. DOI: 10.1016/j.gie.2017.01.033
17. Fujita Y, Hasegawa S, Kato Y, et al. Intravenous injection of low-dose flurbiprofen axetil for preventing post-ERCP pancreatitis in high-risk patients: an interim analysis of the trial. *Endosc Int Open* 2016;4:E1078-82. DOI: 10.1055/s-0042-115172