






Case Report

Cutaneous leishmaniasis in an albino child: a peculiar presentation

Ahmed Samaouel Chehad ^{a,b} , Nada Boutrid ^{c,d,*} , Hadjer Khouidmi ^b, Hakim Rahmoune ^{c,e} 

^a Faculty of Medicine, University of Constantine-3, Algeria

^b Department of Dermatology, University Hospital of Constantine, Algeria

^c LMCVGN Research Laboratory, Faculty of Medicine, University Setif-1, Algeria

^d Department of Pediatrics, EHS Mère-Enfant, El-Eulma, Algeria

^e Department of Pediatrics, University Hospital of Setif, Algeria

ARTICLE INFO

Article history:

Received 17 November 2022

Received in revised form 19

February 2023

Accepted 21 March 2023

Keywords:

Cutaneous leishmaniasis

Albino

Child

ABSTRACT

Cutaneous leishmaniasis (CL) is the most common form of leishmaniasis. It is characterized by nodulo-ulcerative skin lesions and occasionally nodular, papular/plaque, and/or impetiginous lesions on exposed parts of the body. However, other atypical lesions of CL have been reported worldwide such as lupoid, eczematous, erysipeloid, verrucous, dry, zosteriform, paronychia, sporotrichoid, chancriform, annular and erythematous volcanic ulcers. These non-specific lesions often make the diagnosis challenging due to the large number of differential diagnoses and may lead to a delay in the implementation of CL therapy and therefore a higher risk of lifelong scars and major quality of life issues and stigma. We report a case of an 11-year-old immunocompetent albino child boy that presented with 3 years' history of persistent multiple asymptomatic, small ulcers and cribriform scars of the forehead. Diagnosis of CL was confirmed by detecting *Leishmania* parasites in tissue specimens, and treatment by antimony drugs resulted in healing of lesion within one month. This is a novel case of a rare, atypical form of CL, which resulted in delayed diagnosis and management. Clinicians, especially those practicing in CL endemic areas like the Americas and the Mediterranean basin, should consider systematically the diagnosis of CL in front of long-lasting and/or non-specific lesions.

© 2023 The Authors. Published by Iberoamerican Journal of Medicine. This is an open access article under the CC BY license (<http://creativecommons.org/licenses/by/4.0/>).

* Corresponding author.

E-mail address: nadaboutrid@gmail.com

ISSN: 2695-5075 / © 2023 The Authors. Published by Iberoamerican Journal of Medicine. This is an open access article under the CC BY license (<http://creativecommons.org/licenses/by/4.0/>).

<https://doi.org/10.53986/ibjm.2023.0013>

Leishmaniasis cutánea en un niño albino: una presentación peculiar

INFO. ARTÍCULO

Historia del artículo:

Recibido 17 Diciembre 2022
 Recibido en forma revisada 19
 Febrero 2023
 Aceptado 21 Marzo 2023

Palabras clave:

Leishmaniasis cutánea
 Albino
 Niño

RESUMEN

La leishmaniasis cutánea (LC) es la forma más común de leishmaniasis. Se caracteriza por lesiones cutáneas nódulo-ulcerosas y, en ocasiones, lesiones nodulares, papulares/en placas y/o impetiginosas en las partes expuestas del cuerpo. Sin embargo, a nivel mundial se han reportado otras lesiones atípicas de LC como úlceras lupoides, eccematosas, erisipelosas, verrugosas, secas, zosteriformes, paroniquiales, esporotricoides, chancriformes, anulares y eritematosas volcánicas. Estas lesiones inespecíficas a menudo dificultan el diagnóstico debido a la gran cantidad de diagnósticos diferenciales y pueden provocar un retraso en la implementación de la terapia LC y, por lo tanto, un mayor riesgo de cicatrices de por vida y problemas importantes de calidad de vida y estigma. Presentamos el caso de un niño albino inmunocompetente de 11 años de edad que presentó una historia de 3 años de evolución de múltiples úlceras asintomáticas persistentes, pequeñas y cicatrices cribosas en la frente. El diagnóstico de LC se confirmó mediante la detección de parásitos *Leishmania* en muestras de tejido, y el tratamiento con fármacos de antimonio resultó en la curación de la lesión en un mes. Este es un caso novedoso de una forma rara y atípica de LC, que resultó en un diagnóstico y manejo tardíos. Los médicos, especialmente aquellos que practican en áreas endémicas de LC como las Américas y la cuenca del Mediterráneo, deben considerar sistemáticamente el diagnóstico de LC frente a lesiones de larga duración y/o inespecíficas.

© 2023 Los Autores. Publicado por Iberoamerican Journal of Medicine. Éste es un artículo en acceso abierto bajo licencia CC BY (<http://creativecommons.org/licenses/by/4.0/>).

HOW TO CITE THIS ARTICLE: Chehad AS, Boutrid N, Khoudmi H, Rahmoune H. Cutaneous leishmaniasis in an albino child: a peculiar presentation. *Iberoam J Med.* 2023(2):88-92. doi: 10.53986/ibjm.2023.0013.

1. INTRODUCTION

Cutaneous leishmaniasis (CL) is the most common form of leishmaniasis [1]. In 2020, more than 85% of world's new cases of CL occurred in 10 countries, including Algeria as well as Brazil, Peru and Colombia [2]. Ulcerative skin lesions characterize CL and occasionally nodular, psoriasiform, and verrucous lesions on exposed parts of the body [1]. These lesions, mainly ulcers, leave life-long scars and serious disability and stigma [3]. Atypical lesions (such as erythematous volcanic ulcers and eczematous or erysipeloid lesions) may lead to a large panel of differential diagnoses [4].

We report a peculiar presentation of CL in an Algerian albino child, with a multiple cribriform ulcers and scars on the forehead.

2. CASE REPORT

An 11-year-old child boy with an unremarkable medical history apart from albinism was brought to our department for numerous tiny ulcers covering a large part of his forehead and glabella, persistent over the last 3 years despite many cycles of empiric antibiotic treatments. Physical

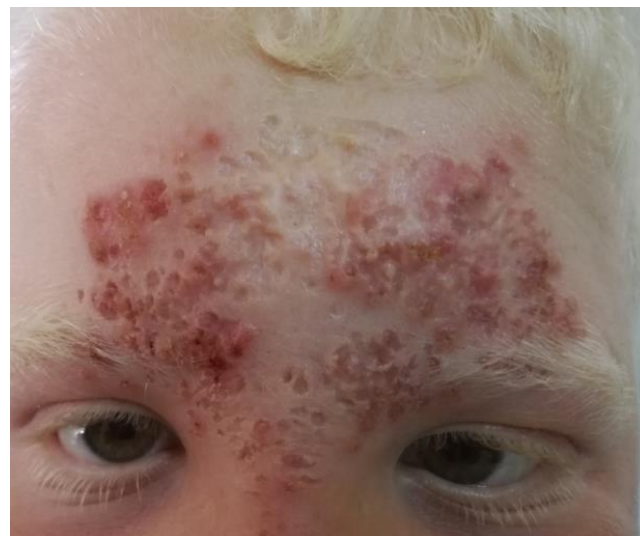

Figure 1: Multiple small and superficial ulcers, with surrounding erythema and cribriform scars, of the middle forehead, glabella and nose.

examination revealed multiple asymptomatic, small and superficial ulcers with surrounding erythema and cribriform scars running from his middle forehead until the upper part of the nose (Figure 1). The underlying skin was infiltrated painless. His biochemical parameters were within normal limits, and there were mainly no signs of immunodeficiency syndrome. A history of staying in a leishmaniasis endemic

Table 1: Classification of cutaneous leishmaniasis (adaptation of the classifications of Akilov et al [6])	
Main entities	Sub-entities
Localized cutaneous leishmaniasis	<p>Typical</p> <p>Popular/ plaque Nodular Nodulo-ulcerative Impetiginous</p>
	<p>Atypical</p> <ul style="list-style-type: none"> • Atypical morphology <ul style="list-style-type: none"> — Zosteriform — Eczematoid — Erysipeloid — Verrucoid — Psoriasiform • Atypical localization <ul style="list-style-type: none"> — Chancriform and trichophytoid — Parenchymal — Palmoplantar — Macrocheilia
Disseminated Cutaneous leishmaniasis	<ul style="list-style-type: none"> • Subcutaneous nodules <ul style="list-style-type: none"> — Discrete — Sporotrichoid pattern — “beaded cord” • Diffuse (pseudolepromatous)
Recurrent (lupoid) leishmaniasis	<p>Planus Ulcerans Tumidus Serpiginous Psoriasiformis</p>
Post kala-azar dermal leishmaniasis	<ul style="list-style-type: none"> • Indian type <ul style="list-style-type: none"> — Erythematoid — Vitiligoid — Papulonodular • African type <ul style="list-style-type: none"> — Macular — Maculopapular — Measles-like — papulonodular

area has been reported, and the diagnosis of CL has been confirmed by detecting Leishmania parasites in tissue specimens from skin ulcers via light-microscopic examination. Treatment by intramuscular injection of pentavalent antimony drugs at 10 mg/kg/day for a period of 15 consecutive days associated with oral prednisone 0.5 mg/kg/day for 5 days resulted in a clear regression and healing of ulcers within one month (Figure 2).

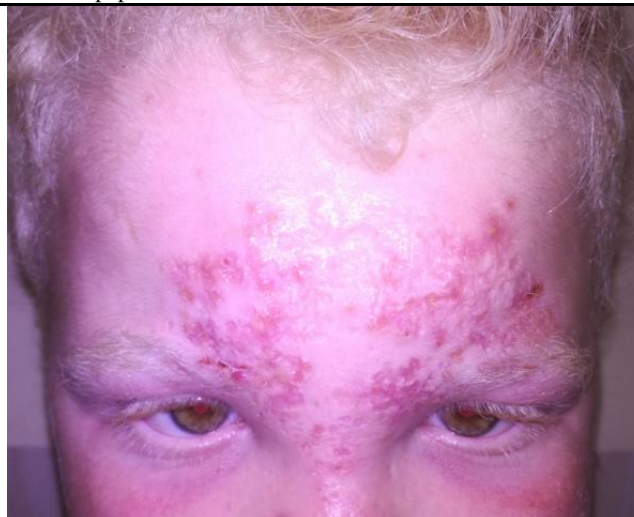

Figure 2: Healing aspect of cutaneous leishmaniasis lesions one month after treatment initiation.

Table 2: Treatments for Cutaneous Leishmaniasis in adults and Children [7-9]

Drugs	Administration route	Dosage regimen in adults	Dosage regimen in children	Comments
Meglumine antimoniate	IM, IV	20 mg /kg/d for 20 d	Same dose as in adults	Most standard CL treatment around the world
	IL	1-2injection / wk of 1-5 mL for 3-4 wk		High IL drug concentrations with minimal toxicity
Amphotericin B deoxycholate	IV	1mg/kg/d every other day. Total dose 2-3g	0.5–1.0mg/kg daily or every other day for a cumulative dose of 15–30mg/kg	Considered after the failure of antimony drugs
Liposomal amphotericin B	IV	10–30mg/kg total dose (single dose 3–5mg/kg/dose)	3mg/kg/d IV for 5d and then a sixth dose on day 10 or daily for 7d for a cumulative dose of 18–21mg/kg	Less toxic but more expensive than the former
Pentamidine	IM	3 or 4 injections of 3mg/kg/d every other day	Same dose as adults	Infections by <i>L. guyanensis</i> or <i>L. panamensis</i> .
Miltefosine	Oral	2-2.5 mg/kg/d for 28 d	Same dose as adults	FDA-approved as the first drug designated for the treatment of CL in the USA
Fluconazole	Oral	200 -600mg/d for 4-6 weeks	12mg/kg/d for 6 weeks	Variable efficacy depending on species
Paromomycin	Topic	1-2 direct application/d for 20-28 d		Infections by <i>L. major</i>
Imiquimod	Topic	Every other day direct application for 20 d in combination with antimony		Useful in refractory cases.
Thermotherapy	Topic	1 treatment/week for 3 weeks of 50 °C for 30 seconds		Appear as effective than IL MA
Cryotherapy	Topic	1 treatment/week for 6 weeks of Liquid nitrogen at –195 °C		Combination with IL MA appear more effective than either treatment alone.

CL: Cutaneous leishmaniasis; D: day (s); FDA: Food and Drug Administration; IL: Intralesional; IM: Intramuscular; IV: Intravenous; L: *Leishmania*; MA: Meglumine antimoniate.

3. DISCUSSION

The leishmaniasis are considered as a spectrum ranging from benign forms represented by CL to mucocutaneous leishmaniasis and systemic visceral leishmaniasis. Further, CL encompasses other entities including localized CL, disseminated CL, recurrent (lupoid) CL and post Kala azar dermal leishmaniasis (Table 1). Different peculiar lesions of CL have been reported worldwide [4]. They may display various aspects, such as lupoid, eczematous, erysipeloid, verrucous, dry, zosteriform, paronychia, sporotrichoid, chancriform, annular and erythematous volcanic ulcers [5]. Our patient presented a rare, atypical form of CL with a number of superficial tiny ulcers and scars, and the affected area appeared as a “cribriform” plaque. Often, these atypical forms of CL are misdiagnosed as blastomycosis, sporotrichosis, diverse fungal skin infections, cutaneous anthrax, eczema, lepromatous leprosy, tuberculosis, *Mycobacterium marinum* infections, basal and squamous

cell carcinomas, and even infected insect bites [4]; and this would result in delayed diagnosis and treatment, as in our case. The reason for this pleomorphism is still unclear, but it might reflect an underlying immune disturbance; and variations in parasite virulence and host factors have been hypothesized to modulate the CL presentation [4]. Our patient depicts only albinism, which is not an immune deficiency by itself.

Treatment of CL differs according to infecting species, extent, location and progression of the disease. Usually, for limited infection when one or a few small lesions are present (excluding periorificial areas or over a joint) topical treatment could be proposed as the sole therapy. However, systemic therapy (mainly antimony drugs) should be used for more extensive lesions (Table 2).

4. CONCLUSIONS

We report an exceptional clinical observation of CL with a

multiple cribriform ulcers and scars on the forehead of albino child. Although, a large number of atypical morphological forms of CL have already been described, such presentation has not been reported in the literature before as far as we know. Thus, the healthcare professionals should perform the best diagnostic and treatment methods to lessen misdiagnoses and control disease progression. Physicians, especially those practicing in CL endemic areas like the Americas and the Mediterranean basin, should bear in mind that the disease may present with various clinical features and even unexpected aspects.

5. CONFLICT OF INTERESTS

The authors have no conflict of interest to declare. The authors declared that this study has received no financial support.

6. REFERENCES

1. Reithinger R, Dujardin JC, Louzir H, Pirmez C, Alexander B, Brooker S. Cutaneous leishmaniasis. *Lancet Infect Dis*. 2007;7(9):581-96. doi: 10.1016/S1473-3099(07)70209-8.
2. World Health Organization. Leishmaniasis Available from: <https://www.who.int/news-room/fact-sheets/detail/leishmaniasis> (accessed Nov 2022).
3. Bennis I, De Brouwere V, Belrhiti Z, Sahibi H, Boelaert M. Psychosocial burden of localised cutaneous Leishmaniasis: a scoping review. *BMC Public Health*. 2018;18(1):358. doi: 10.1186/s12889-018-5260-9.
4. Meireles CB, Maia LC, Soares GC, Teodoro IPP, Gadelha MDSV, da Silva CGL, et al. Atypical presentations of cutaneous leishmaniasis: A systematic review. *Acta Trop*. 2017;172:240-254. doi: 10.1016/j.actatropica.2017.05.022.
5. Jombo GTA, Gyoh SK. Unusual presentations of cutaneous leishmaniasis in clinical practice and potential challenges in diagnosis: A comprehensive analysis of literature reviews. *Asian Pac J Trop Med*. 2010;3(11):917-21. doi: 10.1016/S1995-7645(10)60220-9.
6. Akilov OE, Khachemoune A, Hasan T. Clinical manifestations and classification of Old World cutaneous leishmaniasis. *Int J Dermatol*. 2007;46(2):132-42. doi: 10.1111/j.1365-4632.2007.03154.x.
7. Barba PJ, Morgado-Carrasco D, Quera A. Miltefosine to Treat Childhood Cutaneous Leishmaniasis. *Actas Dermosifiliogr*. 2022;113(8):827-831. doi: 10.1016/j.ad.2020.11.033.
8. Uribe-Restrepo A, Cossio A, Desai MM, Dávalos D, Castro MDM. Interventions to treat cutaneous leishmaniasis in children: A systematic review. *PLoS Negl Trop Dis*. 2018;12(12):e0006986. doi: 10.1371/journal.pntd.0006986.
9. Eiras DP, Kirkman LA, Murray HW. Cutaneous Leishmaniasis: Current Treatment Practices in the USA for Returning Travelers. *Curr Treat Options Infect Dis*. 2015;7(1):52-62. doi: 10.1007/s40506-015-0038-4.