

Original

The correlation of alveolar trabecular bone microstructure with bone density measured by cone-beam computed tomography (CBCT) and implant stability

Salwan Y. Bede^{1*} and Ali Tareef Noaman²

¹Department of Oral and Maxillofacial Surgery. College of Dentistry. University of Baghdad, Iraq. ²Oral Surgery Unit. Specialized Dental Health Center AL-Sheikh Omar. Baghdad Health Directorate-Al-Rusafa. Baghdad, Iraq

ARTICLE INFORMATION

Article history:

Received: 12-07-2024

Accepted: 10-09-2024

Keywords:

Bone density, dental implants, cone-beam computed tomography.

A B S T R A C T

Objectives: This study aimed to determine the correlation between the trabecular bone microstructure and bone density, measured by cone-beam computed tomography (CBCT), and implant stability.

Materials and methods: This study was designed and implemented as a prospective observational clinical study. The bone density of the planned implant site was assessed by CBCT preoperatively. Histomorphometric analysis was performed for the bone specimens harvested from the implant sites before implant insertion using a trephine head. The primary stability was measured immediately after implant insertion while the secondary stability was measured 16 weeks postoperatively using Osstell device. Pearson and Spearman correlation tests were used to determine the correlation between the trabecular bone microstructure and bone density and implant stability.

Results: This study included 31 bone specimens harvested from implant sites. The preoperative bone density demonstrated a positive correlation with bone volume density ($r = 0.735, p < 0.0001$) and trabecular thickness ($r = 0.575, p = 0.0007$), while there was a negative correlation with bone surface density ($r = -0.513, p = 0.003$) and trabecular separation ($r = -0.585, p = 0.0005$). Primary stability implant stability quotient values demonstrated a positive correlation with trabecular thickness ($r = 0.520, p = 0.002$) and a negative correlation with bone surface density ($r = -0.431, p = 0.015$). No correlation regarding the secondary stability was detected.

Conclusions: The bone volume density and trabecular thickness correlated positively with the bone density measured by CBCT, whereas bone surface density and trabecular separation demonstrated negative correlation. The primary stability correlated positively with the trabecular thickness and negatively with bone surface density.

*Correspondence:

E-mail: salwan.bede@gmail.com (Salwan Y. Bede).

<http://dx.doi.org/10.20986/recom.2024.1559/2024>

Correlación de la microestructura del hueso trabecular alveolar con la densidad ósea medida mediante tomografía computerizada de haz cónico (CBCT) y la estabilidad de los implantes

R E S U M E N

Palabras clave:

Densidad ósea, implantes dentales, tomografía computerizada de haz cónico.

Objetivos: Este estudio tenía como objetivo determinar la correlación entre la microestructura del hueso trabecular y la densidad ósea, medidas mediante tomografía computerizada de haz cónico (CBCT) y la estabilidad del implante.

Materiales y métodos: Este estudio se diseñó e implementó como un estudio clínico observacional prospectivo. La densidad ósea del lecho implantario previsto se evaluó mediante CBCT preoperatoria. Se realizó un análisis histomorfométrico de las muestras óseas extraídas de los lechos de los implantes antes de su inserción mediante un cabezal de trépano. La estabilidad primaria se midió inmediatamente después de la inserción del implante, mientras que la estabilidad secundaria se midió 16 semanas después de la intervención, utilizando el dispositivo Osstell. Se utilizaron las pruebas de correlación de Pearson y Spearman para determinar la correlación entre la microestructura del hueso trabecular y la densidad ósea y la estabilidad del implante.

Resultados: Este estudio incluyó 31 especímenes óseos extraídos de zonas de implantes. La densidad ósea preoperatoria demostró una correlación positiva con la densidad del volumen óseo ($r = 0,735$; $p < 0,0001$) y el grosor trabecular ($r = 0,575$; $p = 0,0007$), mientras que se produjo una correlación negativa con la densidad de la superficie ósea ($r = -0,513$; $p = 0,003$) y la separación trabecular ($r = -0,585$; $p = 0,0005$). Los valores del cociente de estabilidad primaria de los implantes mostraron una correlación positiva con el grosor trabecular ($r = 0,520$; $p = 0,002$) y una correlación negativa con la densidad de la superficie ósea ($r = -0,431$; $p = 0,015$). No se detectó ninguna correlación con respecto a la estabilidad secundaria.

Conclusiones: La densidad del volumen óseo y el grosor trabecular se correlacionaron positivamente con la densidad ósea medida mediante CBCT, mientras que la densidad de la superficie ósea y la separación trabecular demostraron una correlación negativa. La estabilidad primaria se correlacionó positivamente con el grosor trabecular y negativamente con la densidad de la superficie ósea.

INTRODUCTION

Proper treatment planning is one of the critical aspects of dental implant success. The sole determinants of implant diagnosis and treatment planning in the past were periapical and panoramic radiographs. Cone-beam computed tomography (CBCT) is becoming increasingly important for appropriate implant placement, especially in cases of complex reconstructions¹.

Bone quantity and quality are two frequently discussed parameters that influence surgical technique, healing time, and progressive loading during prosthodontic rehabilitation. The term bone quantity refers to the amount of bone namely; the height and width of the alveolar crest available for implant placement², whereas bone quality refers to the mechanical properties, architecture, degree of mineralization of the bone matrix, chemistry, and structure of the bone mineral crystals, and bone remodeling properties³. Dental implants installed in alveolar bone of poor quality and insufficient volume significantly affect implant failure rates⁴.

The trabecular (cancellous) bone is one of the main components that influence bone quality⁵. The trabecula is consi-

dered the fundamental anatomical and functional unit of the trabecular bone. Although cortical bone aids in initial implant stability, cancellous bone also plays an important role because it has a greater rate of bone turnover than cortical bone⁶ and is in direct contact with the majority of the implant surface⁷. As a result, it has an impact on the healing and osseointegration process at the bone-implant surface⁸.

Trabecular density and trabecular microstructure should be integrated to improve bone strength prediction⁹. This is because these measurements do not always correspond to one another. High bone density, for example, does not always imply high trabecular parameters like trabecular number and trabecular thickness¹⁰. Therefore, relying solely on trabecular density to predict implant success is no longer recommended¹¹.

For bone microarchitecture analysis, histomorphometry has long been regarded as the gold standard¹². This method allows for two-dimensional (2D) evaluation and produces a high-spatial-resolution and high-contrast image, but it is time-consuming¹³. A third dimension can be added based on stereology¹⁴. Histomorphometry also has the drawback of being destructive and not allowing for further measurements of samples¹⁵.

Microcomputed tomography (micro-CT) is another method to study bone microarchitecture, it provides high resolution and accurate imaging for both the 2D and three-dimensional (3D) study of bone morphology¹⁴. González-García and Monje analyzed the osseous microstructure using micro-CT and compared it with the conventional stereological-based histomorphometry performed by optic microscopy and low-vacuum surface electronic microscopy, and they demonstrated that micro-CT correlates with the percentage of bone assessed by conventional stereological-based histomorphometry¹⁶. Moreover, the same authors first demonstrated that the radiographic bone density assessed by CBCT had a high positive correlation with bone volumetric fraction assessed by micro-CT at the recipient site of dental implants within the maxillary bones¹⁷.

There appear to be a few clinical studies that address the relationship between conventional histomorphometric analysis of the trabecular bone and the bone density measured by CBCT and dental implant stability, therefore, this study aimed to investigate the trabecular bone histomorphometric parameters and their correlation with bone density values measured by CBCT and implant stability.

MATERIALS AND METHODS

This prospective observational clinical study was conducted at the Department of Oral and Maxillofacial Surgery, College of Dentistry, University of Baghdad during the period extending from September 2019 to June 2021. This study was conducted in accordance with the Declaration of Helsinki guidelines and was approved by the institutional Research Ethics Committee (protocol # 036118), and each patient signed informed consent to participate in this study.

The sample included patients who presented with missing teeth that were restored with implant-supported fixed prostheses. The inclusion criteria included healthy adult patients with partially edentulous maxilla or mandible, with a minimum of 6 months after teeth extraction, who were indicated for delayed implant placement protocol and presented with sufficient vertical and horizontal alveolar ridge dimensions.

The exclusion criteria were any systemic condition that could interfere with normal healing such as uncontrolled diabetes mellitus, patients with a history of irradiation to the head and neck region or chemotherapy, patients treated with oral or intravenous bisphosphonates, local conditions such as the presence of acute or chronic infection, or any local pathology in the proposed implant zone, inadequate interocclusal space, active periodontitis and clinical evidence of parafunctional habits (bruxism or clenching).

A preoperative CBCT (Kavo OP 3D PRO, Germany) was taken for all patients to assess the bone density and to measure the bone height and width of the alveolar ridge at the proposed implant sites using the OnDemand3D™ software (Cybermed Inc.®, Seoul, Korea). The bone density graph tool was used to determine the bone density inside the implant fixture in Hounsfield units (HU).

Surgical procedure

All the procedures were performed under local anesthesia. After reflecting a mucoperiosteal flap, the implant site preparation started by harvesting a bone sample from the implant sites using EasyRetrieve two-piece trephine burs kit (ACE Surgical Supply Co., Inc., USA), with a 3.2 mm outer diameter and 2.5 mm inner diameter trephine head on a contra-angle handpiece, the height of the bone sample corresponded to the planned length of dental implants. After bone sample procurement, the preparation of the implant site proceeded in a sequential manner using the final drills rotating at a speed of 800 rpm and 35 Ncm torque with copious saline irrigation and according to the planned implant dimensions.

The dental implants (Superline, Dentium, Seoul, Korea), with implant diameters of 3.6 mm, 4 mm, or 4.5 mm and lengths of 8 mm, 10 mm, or 12 mm, were installed into the osteotomy site using the motorized method with the engine set at 50 rpm and 35 Ncm torque. A ratchet was used to place the implant to the desired depth when an insertion torque of more than 35 Ncm was required.

After the insertion of dental implants, the primary stability was measured using a resonance frequency analysis device (Osstell ISQ, Gothenburg, Sweden). Two repeated implant stability quotient (ISQ) measurements were obtained for each implant along the buccolingual and mesiodistal axis and the mean of these two readings was recorded as the primary stability.

After 16 weeks postoperatively, the implants were exposed and the implant stability was measured in the same manner and recorded as the secondary stability, and a healing abutment was inserted.

Histomorphometry

The 2.5 mm diameter bone samples that were harvested from the implant site were rinsed with a physiologic solution and were fixed in 10 % formalin for 24 hours. Then they were decalcified with 10 % formic acid and under routine processing prepared in paraffin blocks. Following this processing, the samples were longitudinally sectioned in 5-micrometer slices, a middle section was selected for histomorphometric analysis corresponding to the greatest dimension of the specimen in length and diameter, and were stained with hematoxylin/eosin for light microscopic examination. Digital images were acquired and measurements of total bone perimeter length (PB), total bone area [trabecular bone] (AB), and total section area [trabecular bone plus bone marrow] (AT) were performed using the ImageJ v1.52a software (U.S. National Institutes of Health, Bethesda, Maryland, USA) (Figure 1).

The primary 2D histomorphometric measurements (P_b , A_b , and A_r) were used to calculate 3D parameters based on the stereology as follows¹⁴:

- Bone volume density (BV/TV): is the ratio of the trabecular bone volume (BV) to the total tissue volume (TV) of the volume of interest (VOI) calculated as $(AB/AT) \times 100$. The unit is %.

- Bone surface fraction (BS/TV): is the ratio of the bone surface area (BS) to the total TV of VOI calculated as $(PB/AT) \times 1.199$. The unit is mm^{-1} .
- Bone surface density (BS/BV): is a ratio of BS area to the trabecular BV of VOI calculated as $(PB/AB) \times 1.199$. The unit is mm^{-1} .
- Trabecular thickness (Tb. Th): is calculated from BV and TV as $(2/1.199) (AB/PB)$. The unit is mm.
- Trabecular Number (Tb. N): calculated from the reciprocal of the distance between the center and the center of trabeculae as $(1.199/2) (PB/AT)$. The unit is mm^{-1} .
- Trabecular separation (Tb. Sp): is the distance between adjacent trabeculae calculated as $(2/1.199) (AT-AB)/PB$. The unit is mm.

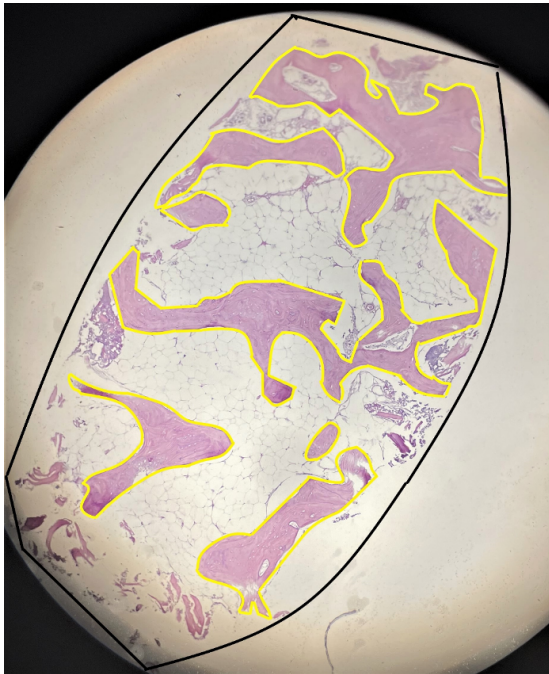


Figure 1. Histological slice of bone specimen (Hematoxylin and Eosin/original magnification $\times 4$) obtained from lower right first molar area. Histomorphometric measurements show the total section area (trabecular bone + bone marrow) outlined in black, and total bone area (trabecular bone) outlined in yellow, using Imagej v1.52 software.

Study variables and statistical analysis

The predictor variables included the bone density measured by CBCT as Hounsfield units (HU), the trabecular bone morphometric parameters, and the primary and secondary stability measured as ISQ. The outcome variables were the correlation of the trabecular bone morphometric parameters with the bone density and implant stability. Other variables included the age and sex (male or female) of the patients and the recipient jaw (maxilla or mandible).

The statistical analysis was performed using GraphPad Prism version 6 for Windows (GraphPad Software, La Jolla, CA, USA). Descriptive statistical analysis included the calculation of percentages and mean, standard deviation (SD), and median. The inferential analysis included using the Shapiro-Wilk normality test, Pearson correlation test, and Spearman correlation test. The probability value $P < 0.05$ was considered statistically significant.

RESULTS

Initially, this study included 24 patients who received 42 dental implants and from whom 42 bone samples were harvested. After excluding the distorted bone samples ($n = 11$), 31 specimens were available for histomorphometric analysis; the specimens belonged to 15 patients; 9 (60 %) females and 6 (40 %) males. The mean (SD) age of the patients was 45.13 (14.61) years with a range of 25-75 years and a median of 43.00 years. The mean (SD) and median preoperative bone density measured by CBCT were 238.6 (113.9) and 223.3 HU, respectively (range 28.40- 451.9 HU).

The descriptive statistics of the histomorphometric parameters of the trabecular bone are shown in Table I. Most samples ($n = 23$, 74.2 %) were from the mandible.

Table I. Descriptive statistics of the histomorphometric parameters of trabecular bone.

Histomorphometric parameters	Mean	SD	Median
Total area (AT)	6.19	2.06	5.98
Bone area (AB)	1.90	1.20	1.64
Bone perimeter (PB)	20.73	10.10	18.62
Bone volume density / %	29.55	13.13	28.13
Bone surface fraction / mm^{-1}	4.13	2.07	3.69
bone surface density / mm^{-1}	15.44	5.97	13.73
Trabecular thickness / mm	0.15	0.06	0.15
Trabecular number / mm^{-1}	2.06	1.03	1.84
Trabecular separation / mm	0.39	0.14	0.41

SD: Standard deviation.

The bone density measured by CBCT correlated positively with bone volume density and trabecular thickness, while there was a negative correlation with bone surface density and trabecular separation. This indicated that bone density assessed by CBCT increased with the increase in bone volume density and trabecular thickness and decreased with the increase in bone surface density and trabecular separation. The correlation of histomorphometric parameters with bone density measured by CBCT is summarized in Table II.

Table II. The correlation of histomorphometric parameters with bone density measured by CBCT.

Histomorphometric parameters	Correlation with bone density measured by CBCT
Bone volume density/ %	$r = 0.735^*$ $p < 0.0001$ [S]
Bone surface fraction / mm-1	$r = 0.236^*$ $p = 0.199$ [NS]
Bone surface density /mm-1	$r = -0.513 \dagger$ $p = 0.003$ [S]
Trabecular thickness /mm	$r = 0.575 \dagger$ $p = 0.0007$ [S]
Trabecular number /mm-1	$r = 0.236^*$ $p = 0.199$ [NS]
Trabecular separation /mm	$r = -0.585 \dagger$ $p = 0.0005$ [S]

*: Spearman r . †: Pearson r . S: significant. NS: non-significant.

The mean (SD) and median of the primary stability were 79.06 (4.494) and 79.00 ISQ, respectively, while for the secondary stability were 72.87 (6.318) and 73.00 ISQ, respectively. All dental implants were successfully osseointegrated after 16 weeks postoperatively.

There was a significant positive correlation between the primary stability ISQ values and the trabecular thickness, and a significant negative correlation with the bone surface density, indicating that increased trabecular thickness resulted in higher primary stability values while increased bone surface density resulted in lower primary stability values. For the secondary stability ISQ values, no significant correlation was recorded with any of the histomorphometric parameters. The correlation of histomorphometric parameters with implant stability is summarized in Table III.

Table III. The correlation of histomorphometric parameters with implant stability.

Histomorphometric parameters	Correlation with primary stability	Correlation with secondary stability
Bone volume density/%	$r = 0.308^*$ $p = 0.091$ [NS]	$r = -0.082^*$ $p = 0.662$ [NS]
Bone surface fraction /mm-1	$r = -0.148^*$ $p = 0.426$ [NS]	$r = -0.0446^*$ $p = 0.812$ [NS]
Bone surface density /mm-1	$r = -0.431 \dagger$ $p = 0.015$ [S]	$r = -0.092 \dagger$ $p = 0.625$ [NS]
Trabecular thickness /mm	$r = 0.520 \dagger$ $p = 0.002$ [S]	$r = 0.200 \dagger$ $p = 0.280$ [NS]
Trabecular number /mm-1	$r = -0.148^*$ $p = 0.426$ [NS]	$r = -0.045^*$ $p = 0.811$ [NS]
Trabecular separation /mm	$r = -0.124 \dagger$ $p = 0.504$ [NS]	$r = 0.192 \dagger$ $p = 0.300$ [NS]

*: Spearman r . †: Pearson r . S: significant. NS: non-significant.

DISCUSSION

In the peri-implant healing phase, trabecular bone tissue is regarded to be the most significant¹⁸. The use of CBCT in assessing alveolar bone density is considered a reliable method¹⁹⁻²¹ but its accuracy and reliability in representing the actual bone quality is not clear. For this reason, studying trabecular bone microarchitecture is important for understanding its mechanical competency²², its relationship with bone density, and its impact on the outcome of dental implant therapy²³. Therefore, this study aimed to investigate the trabecular bone histomorphometric parameters and their correlation with bone density values measured by CBCT and implant stability.

The result of this study showed that the bone density measured by CBCT correlated positively with bone volume density and trabecular thickness while there was an inverse correlation with bone surface density and trabecular separation. These findings are in line with a recent study²⁴ that compared trabecular bone density measurement in HU with trabecular microstructure using CBCT obtained from 58 patients, the authors demonstrated a significant positive correlation of bone volume fraction, trabecular thickness, and trabecular number with bone density measured by CBCT, while trabecular separation negatively correlated with the density. They suggested that when analyzing the structural characteristics of the trabecular bone, it is desirable to use trabecular thickness, trabecular number, and trabecular separation, and they considered that the bone volume fraction or HU is for the evaluation of the overall bone.

Blok et al.²⁵ also reported a significant positive correlation between bone density and trabecular thickness and they suggested that trabecular thickness and bone volume density may be predictors for successful osseointegration of the implants.

González-García and Monje analyzed the relationship between the preoperatively determined radiographic bone density assessed by the density values obtained by CBCT and several histomorphometric microstructural variables assessed by micro-CT, the authors included 39 cylindrical bone biopsies extracted from the maxillary bones at the site of the planned dental implants and demonstrated a strong positive correlation between the radiographic bone density and bone volumetric fraction (BV/TV) concluding that preoperative estimation of density values by CBCT is a reliable tool to objectively determine bone density and to determine the best sites for dental implant insertion¹⁷.

Regarding the correlation between the trabecular bone morphometric parameters and the primary implant stability in this study, the data showed a significant positive correlation between the trabecular thickness and the primary stability ISQ values. This concurs with the findings of Kang et al.²⁶, who reported a similar finding in dental implants placed into swine bone specimens and measured by impact response frequency. Moreover, Pauwels et al.²⁷ reported a significant correlation between the trabecular thickness around the entire implant and the primary stability ISQ values of dental implants placed into 21 hemimandible bones of human cadavers.

On the other hand, in another study²³ that analyzed 46 alveolar bone biopsies harvested from different sites of the maxilla and the mandible of 32 partially edentulous volunteers utilizing micro-CT, poor or no correlation was present between primary stability ISQ values and 3D bone microarchitecture.

Of the alveolar bone microarchitecture parameters, Trabecular thickness is an important predictor for improved primary stability and successful osseointegration of dental implants, it correlates positively with bone density measured by CBCT suggesting that it is a reliable tool to assess the bone quality indirectly since direct evaluation requires using histomorphometry or micro-CT which is currently regarded to be the gold standard modality for quantitative and objective assessment of bone microarchitecture parameters²⁸.

In this study, bone surface density showed a significant negative correlation with the primary stability ISQ values, this is in keeping with other studies that demonstrated an increase in implant stability when bone surface density decreased as the bone had thick trabeculae or a plate-like trabecular pattern^{10,26}.

Bone volume density, bone surface fraction, trabecular number, and trabecular separation presented no significant correlations with the primary stability ISQ values which concurs with previous studies^{23,29}.

In this study, no significant correlation between any of the bone histomorphometric parameters and the secondary stability ISQ values was recorded. This is in line with a previous study²³ that reported no correlation between micro-CT 3D bone microstructure parameters and uncovering ISQ values (secondary stability). Secondary stability is a biological phenomenon that is not related to the structural characteristics of bone which are more associated with the mechanical primary stability³⁰, may explain the lack of correlation between the histomorphometric parameters and the secondary stability.

One of the main limitations encountered in this study is related to the distortion of some of the bone samples harvested whether during procurement or processing which further reduced the sample size adding to the difficulty in obtaining relevant generalizations.

CONCLUSIONS

Within the limitations of this study, it can be concluded that the histomorphometric parameters that correlated positively with the bone density measured by CBCT were the bone volume density and trabecular thickness, while bone surface density and trabecular separation demonstrated negative correlations. The primary stability of dental implants correlated positively with the trabecular thickness and negatively with bone surface density.

CONFLICT OF INTEREST

None declared.

FUNDING

This study did not receive any specific grant from funding agencies in the public, commercial, or not-for-profit sectors.

ETHICAL APPROVAL AND CONSENT TO PARTICIPATE

This study was conducted in accordance with the Declaration of Helsinki guidelines and was approved by the institutional Research Ethics Committee (protocol # 036118), and each patient signed informed consent to participate in this study.

DATA AVAILABILITY

The data will be provided upon request.

REFERENCES

- Chan HL, Misch K, Wang HL. Dental imaging in implant treatment planning. *Implant Dent.* 2010;19(4):288-98. DOI: 10.1097/ID.0b013e3181e59ebd.
- Lindh C, Obrant K, Petersson A. Maxillary bone mineral density and its relationship to the bone mineral density of the lumbar spine and hip. *Oral Surgery, Oral Med Oral Pathol Oral Radiol Endod.* 2004;98(1):102-9. DOI: 10.1016/s1079-2104(03)00460-8.
- de Oliveira RCG, Leles CR, Normanha LM, Lindh C, Ribeiro-Rotta RF. Assessments of trabecular bone density at implant sites on CT images. *Oral Surgery, Oral Med Oral Pathol Oral Radiol Endod.* 2008;105(2):231-8. DOI: 10.1016/j.tripleo.2007.08.007.
- Chrcanovic BR, Albrektsson T, Wennerberg A. Bone Quality and Quantity and Dental Implant Failure: A Systematic Review and Meta-analysis. *Int J Prosthodont.* 2017;30(3):219-37. DOI: 10.11607/ijp.5142.
- Licata A. Bone density vs bone quality: what's a clinician to do? *Cleve Clin J Med.* 2009;76(6):331-6. DOI: 10.3949/ccjm.76a.08041.
- Sakka S, Coulthard P. Bone quality: A reality for the process of osseointegration. *Implant Dent.* 2009;18(6):480-5. DOI: 10.1097/ID.0b013e3181bb840d.
- Fanuscu MI, Chang TL. Three-dimensional morphometric analysis of human cadaver bone: Microstructural data from maxilla and mandible. *Clin Oral Implants Res.* 2004;15(2):213-8. DOI: 10.1111/j.1600-0501.2004.00969.x.
- Minkin C, Marinho VC. Role of the osteoclast at the bone-implant interface. *Adv Dent Res.* 1999;13:49-56. DOI: 10.1177/08959374990130011401.
- Müller R. Bone microarchitecture assessment: current and future trends. *Osteoporos Int.* 2003;14 Suppl 5:89-99. DOI: 10.1007/s00198-003-1479-z.
- Gomes de Oliveira RC, Leles CR, Lindh C, Ribeiro-Rotta RF. Bone tissue microarchitectural characteristics at dental implant sites. Part 1: Identification of clinical-related parameters. *Clin Oral Implants Res.* 2012;23(8):981-6. DOI: 10.1111/j.1600-0501.2011.02243.x.
- Wirth AJ, Goldhahn J, Flaig C, Arbenz P, Müller R, Van Lenthe GH. Implant stability is affected by local bone microstructural quality. *Bone.* 2011;49(3):473-8. DOI: 10.1016/j.bone.2011.05.001.
- Chappard D, Retailliau-Gaborit N, Legrand E, Baslé MF, Audran M. Comparison insight bone measurements by histomorphometry and μ CT. *J Bone Miner Res.* 2005;20(7):1177-84. DOI: 10.1359/JBMR.050205.

13. Müller R, Van Campenhout H, Van Damme B, Van Der Perre G, Dequeker J, Hildebrand T, et al. Morphometric analysis of human bone biopsies: A quantitative structural comparison of histological sections and micro-computed tomography. *Bone*. 1998; 23(1):59-66. DOI: 10.1016/s8756-3282(98)00068-4.
14. Dias DR, Leles CR, Batista AC, Lindh C, Ribeiro-Rotta RF. Agreement between Histomorphometry and Microcomputed Tomography to Assess Bone Microarchitecture of Dental Implant Sites. *Clin Implant Dent Relat Res*. 2015;17(4):732-41. DOI: 10.1111/cid.12176.
15. Dalle Carbonare L, Valenti MT, Bertoldo F, Zanatta M, Zenari S, Realdi G, et al. Bone microarchitecture evaluated by histomorphometry. *Micron*. 2005;36(7-8):609-16. DOI: 10.1016/j.micron.2005.07.007.
16. González-García R, Monje F. Is micro-computed tomography reliable to determine the microstructure of the maxillary alveolar bone? *Clin Oral Implants Res*. 2013;24(7):730-7. DOI: 10.1111/j.1600-0501.2012.02478.x
17. González-García R, Monje F. The reliability of cone-beam computed tomography to assess bone density at dental implant recipient sites: a histomorphometric analysis by micro-CT. *Clin Oral Implants Res*. 2013;24(8):871-9. DOI: 10.1111/j.1600-0501.2011.02390.x
18. Davies JE. Understanding peri-implant endosseous healing. *J Dent Educ*. 2003;67(8):932-49.
19. Al-Jamal MFJ, Al-Jumaily HA. Can the Bone Density Estimated by CBCT Predict the Primary Stability of Dental Implants? A New Measurement Protocol. *J Craniofac Surg*. 2021;32(2):e171-e174. DOI: 10.1097/SCS.0000000000006991.
20. Noaman AT, Bede SY. The Effect of Bone Density Measured by Cone Beam Computed Tomography and Implant Dimensions on the Stability of Dental Implants. *J Craniofac Surg*. 2022;33(6):e553-e557 DOI: 10.1097/SCS.0000000000008429.
21. Xiao Y, Lv L, Xu Z, Zhou L, Lin Y, Lin Y, et al. Correlation between peri-implant bone mineral density and primary implant stability based on artificial intelligence classification. *Sci Rep*. 2024;14. 3009. DOI: 10.1038/s41598-024-52930-7.
22. Chappard D, Baslé MF, Legrand E, Audran M. Trabecular bone microarchitecture: A review. *Morphologie*. 2008;92(299):162-70. DOI: 10.1016/j.morpho.2008.10.003.
23. Ribeiro-Rotta RF, de Oliveira RCG, Dias DR, Lindh C, Leles CR. Bone tissue microarchitectural characteristics at dental implant sites part 2: Correlation with bone classification and primary stability. *Clin Oral Implants Res*. 2014;25(2):47-53. DOI: 10.1111/clr.12046.
24. Kim TH, Lee DY, Jung SK. Comparison of Trabecular Bone Mineral Density Measurement Using Hounsfield Unit and Trabecular Microstructure in Orthodontic Patients Using Cone-Beam Computed Tomography. *Appl. Sci*. 2021;11:1028. DOI: 10.3390/app11031028.
25. Blok Y, Gravesteyn FA, Van Ruijven LJ, Koolstra JH. Micro-architecture and mineralization of the human alveolar bone obtained with microCT. *Arch Oral Biol*. 2013;58(6):621-7. DOI: 10.1016/j.archoralbio.2012.10.001.
26. Kang SR, Bok SC, Choi SC, Lee SS, Heo MS, Huh KH, et al. The relationship between dental implant stability and trabecular bone structure using cone-beam computed tomography. *J Periodontal Implant Sci*. 2016;46(2):116-27. DOI: 10.5051/jpis.2016.46.2.116.
27. Pauwels R, Sessirisombat S, Panmekiate S. Mandibular Bone Structure Analysis Using Cone Beam Computed Tomography vs Primary Implant Stability: An Ex Vivo Study. *Int J Oral Maxillofac Implants*. 2017;32(6):1257-65. DOI: 10.11607/jomi.6210.
28. Theye CEG, Hattingh A, Cracknell TJ, Oetlé AC, Steyn M, Vandeweghe S. Dento-alveolar measurements and histomorphometric parameters of maxillary and mandibular first molars, using micro-CT. *Clin Implant Dent Relat Res*. 2018;20(4):550-61. DOI: 10.1111/cid.12616.
29. Rozé J, Babu S, Saffarzadeh A, Gayet-Delacroix M, Hoornaert A, et al. Correlating implant stability to bone structure. *Clin Oral Implants Res*. 2009;20(10):1140-5. DOI: 10.1111/j.1600-0501.2009.01745.x.
30. Quesada-García MP, Prados-Sánchez E, Olmedo-Gaya MV, Muñoz-Soto E, González-Rodríguez MP, Valllecillo-Capilla M. Measurement of dental implant stability by resonance frequency analysis: a review of the literature. *Med Oral Patol Oral Cir Bucal*. 2009;14(10):538-46. DOI: 10.4317/medoral.14.e538.