

## Cockayne's Syndrome: A case report. Literature review.

María de la Luz Arenas Sordo <sup>1,4</sup>, Edgar Hernández Zamora <sup>1</sup>, Luis Alberto Montoya Pérez <sup>2</sup>, Beatriz Catalina Aldape Barrios <sup>3,4</sup>

- (1) Servicio de Genética, Instituto Nacional de Rehabilitación Secretaría de Salud
- (2) Cirujano Dentista, Servicio Social, Universidad Nacional Autónoma
- (3) Servicio de Patología Bucal, Estudios de Postgrado Universidad Nacional Autónoma
- (4) Académico de la Universidad Nacional Autónoma. México

### Correspondence:

Dra. María de la Luz Arenas Sordo  
 Instituto Nacional de Rehabilitación S.S.  
 Servicio de Genética (Torre de Investigación tercer piso).  
 Calzada México-Xochimilco 289,  
 Col. Arenal de Guadalupe.  
 Delegación Tlalpan, C.P. 14389, México D.F.  
 E-mail: [asgk@servidor.unam.mx](mailto:asgk@servidor.unam.mx)

Arenas-Sordo ML, Hernández-Zamora E, Montoya-Pérez LA, Aldape-Barrios BC. Cockayne's Syndrome: A case report. Literature review. Med Oral Patol Oral Cir Bucal 2006;11:E236-8.  
 © Medicina Oral S. L. C.I.F. B 96689336 - ISSN 1698-6946

Received: 23-02-2005

Accepted: 21-01-2006

[Click here to view the article in Spanish](#)

Indexed in:  
 -Index Medicus / MEDLINE / PubMed  
 -EMBASE, Excerpta Medica  
 -Índice Médico Español  
 -IBECs

### ABSTRACT

Cockayne's syndrome is a genetic disorder with a recessive autosomal inheritance, described first by Cockayne in 1936. Patients with this syndrome present failure to thrive, short stature, premature aging, neurological alterations, photosensitivity, delayed eruption of the primary teeth, congenitally absent of some permanent teeth, partial macrodontia, atrophy of the alveolar process and caries. It could be caused by two gene mutations, CNK1 (ERCC8) and ERCC6, located on the 5 and 10 chromosomes respectively, causing two variations of Cockayne's syndrome, CS-A, secondary to a ERCC8 mutation and CS-B with ERCC6 mutation, the last one causes hypersensitivity to the ultraviolet light secondary to a DNA repair defect. The syndrome is also associated with mutations of the XPB, XPD and XPG genes.

In this report we present a 9 year and 4 month old patient. He had a height of 94 cm, weight of 8.6 Kg, head circumference of 42 cm. and blood pressure of 120/80. Cachectic habitus, kyphosis, microcephaly, oval face, sunken eyes, a thin and beaklike nose, lack of subcutaneous facial fat (especially in the middle of the face), and large ears give the patient a birdlike appearance. It is notorious the photosensitivity in all the sun-exposed skin. The patient also displays delayed psychomotor skills and mental retardation.

In the oral cavity we found deficient hygiene, gingivitis, cervical caries, enamel hypoplasia, abnormal position of the upper and inferior lateral incisors, macrodontia of the upper central teeth, the left one presented a caries. In the x-ray we observed congenital absence of 14, 23 and 24 teeth and mandibular hypoplasia.

The aim of this review is to show the dentistry community the characteristics of the Cockayne's syndrome by means of a clinical case.

**Key words:** *Premature aging, photosensitivity, CKN1 gene, CSA gene, CSB gene, ERCC6 gene, ERCC8 gene, XPB gene, XPD gene, XPG gene, macrodontia, oligodontia, growth and development retardation, Cockayne's syndrome.*

### RESUMEN

El Síndrome de Cockayne (CS) es un desorden genético con un patrón de herencia autosómico recesivo que fue descrito por primera vez en 1936 por Cockayne. Los pacientes con este síndrome presentan detención del crecimiento, talla baja, envejecimiento prematuro, anomalías neurológicas, fotosensibilidad, retraso en la erupción de los dientes primarios, ausencia congénita de dientes permanentes, macrodoncia parcial, atrofia de los procesos alveolares y caries dental. Puede ser causado por mutación en dos genes, el CKN1 (ERCC8) y el ERCC6, localizados en los cromosomas 5 y 10 respectivamente; originando dos tipos: CS-A que tienen mutación en ERCC8 y CS-B con mutación en ERCC6,

este último provoca sensibilidad a la luz ultravioleta, secundaria a una deficiencia en la reparación de DNA. También se ha asociado el síndrome a mutaciones de los genes XPB, XPD y XPG.

En el presente reporte se informa de un paciente de 9 años con cuatro meses de edad. En la exploración física se registró talla de 94 cm, peso de 8.6 kg y perímetro cefálico de 42 cm. TA 120/80. Hábito caquético, problemas posturales con encurvamiento, así como microcefalia, cara ovalada, ojos hundidos, nariz delgada y afilada, falta de grasa en la cara, más notorio en el tercio medio y orejas grandes que le confieren una apariencia de "pajarito". Se observa marcada fotosensibilidad en toda la piel expuesta al sol. Presenta retraso psicomotor y mental.

Intrabucalmente se aprecia higiene deficiente, gingivitis, caries cervical, hipoplasia del esmalte, mala posición dentaria de los incisivos laterales superiores e inferiores, y macrodoncia de los dientes centrales superiores, el izquierdo presenta una lesión por caries. Radiográficamente se observa ausencia congénita de los dientes 14, 23, 24 e hipoplasia mandibular.

El objetivo de este trabajo es dar a conocer a la comunidad odontológica las características del síndrome de Cockayne a través de un caso clínico.

**Palabras clave:** *Envejecimiento prematuro, fotosensibilidad, gen CKN1, gen CSA, gen CSB, gen ERCC6, gen ERCC8, gen XPB, gen XPD, gen XPG, macrodoncia, oligodoncia, retraso en el crecimiento y desarrollo, síndrome de Cockayne.*

## INTRODUCTION

There are at least fifteen human disorders caused by defects in the DNA repair (1). One of these is the Cockayne's syndrome (CS), described by Cockayne in 1936 (2,3). This syndrome occurred with a frequency of 1/100 000 live births and can be caused by mutations of two genes, the CKN1 or ERCC8 (Excision-Repair Cross- Complementing Group 8), and the ERCC6 (Excision-Repair Cross Complementing, Group 6), located on chromosomes 5 and 10q11 respectively. These give rise to two variations of the syndrome: CS-A for the CKN1 and CS-B for the ERCC6. It has also been associated with mutations in XPB (Xeroderma pigmentosum B) gene, XPD (Xeroderma pigmentosum D) gene and XPG (Xeroderma pigmentosum G) gene (1,3-6).

The CS clinical findings are growth failure, premature aging, short stature, cachectic aspect, disproportionately long limbs, kyphosis, microcephaly, sparse hair. The findings also show a lack of subcutaneous facial fat (particularly of the cheeks), prominence of the facial bones, sunken eyes, a thin and beaklike nose, and large ears, which all give the patient a "birdlike" appearance (1,2,5-7). There is photosensitivity to UV light but no significant increase in skin cancer is noted (6-9).

They present delayed psychomotor skills and mental retardation, which lead to severe problems for talking and walking (2,5-8,10,11). However, cases of normal intelligence have been reported (7). There are ophthalmologic diseases like pigmentary retinopathy, degeneration of the retina, cataracts and decreased tearing. The patients commonly have hearing loss. Other frequent complications are liver and spleen enlargement, renal disease and hypertension (3,5,7).

The usual oral findings are delayed deciduous teeth eruption, congenital absence of some permanent teeth (oligodontia), partial macrodontia principally of the central incisors, dental hypoplasia, short roots, more incidence of caries, a deep palate, atrophy of the alveolar processes, mandibular prognathism and condylar hypoplasia (3,5,7,10,11).

## CASE REPORT

Male 9 year and 4 month old patient, with negative family history, consanguinity and inbred denied. He was born weighing 2,900 Kg after a preterm pregnancy (36 weeks) from a gravida 2. He had completely congenital cataracts that were surgically removed. He presented delayed psychomotor skills.

At the age of 3 years he started with failure to grow. In the physical examination we found a height of 94 cm, weight of 8.6 Kg, head circumference of 42 cm, his blood pressure was 120/80. He appears to have cachectic habitus, kyphosis, sunken eyes, a thin and beaklike nose, lack of subcutaneous cheeks fat, and large ears, giving the patient a "birdlike" appearance. We observed photosensitivity, principally in the face. He has motor and mental retardation. He does not walk and cannot stand-up on his own. Fig 1.

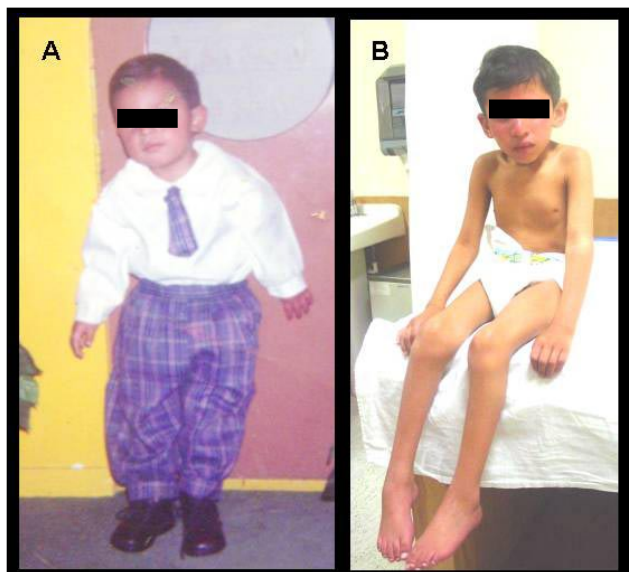
In the oral cavity we founded normal mucosa, deeply arched palate, deficient hygiene and gingivitis. The eruption of 11,12,16,21,22,26,31,32,33,34,36,41,42,41 and 46 and partial eruption of 15 and 25 teeth were present, teeth rotation of 12,22,32,and 42, macrodontia of 11 and 21 teeth. The 21 has an incisal caries, hypoplasia of 16, 26 and 36 teeth, the 26 and 46 have restorations. The inferior central incisors have cervical caries.

In the x-ray we can see the teeths' germs 13,17,27,35,37,44,45,47 and congenital absence of the 14, 23 and 24, short roots in the erupted teeth and mandibular and condylar hypoplasia and atrophy of the alveolar processes.

## DISCUSSION

The clinical findings in our patient permitted us to establish a diagnosis of Cockayne's syndrome. Correlating the syndrome with the CBS gene mutation is not possible, however, we hypothesize that the mutation gives rise to the protein responsible for coding the gene due to its absence resulting in a much more abnormal phenotype (10).

Our patient presents a blood pressure of 120/80 above what is considered to be optimal (diastolic less than 80). This data is important as it may reflect the patient's health (12).



**Fig. 1.** A) Two years old patient, there is not evidence of Cockayne's syndrome. B) Actual phenotype of the patient. Note the cachectic habitus, sunken eyes, lack of subcutaneous facial fat and others characteristics of the Cockayne's syndrome.

9. Lee SK, Yu SL, Prakash L, Prakash S. Requirement of yeast RAD2, a homolog of human XPG gene, for efficient RNA polymerase II transcription. implications for Cockayne syndrome. *Cell*. 2002;109:823-34.
10. Spivak G. The many faces of Cockayne syndrome. *Proc Natl Acad Sci U S A*. 2004;101:15273-4.
11. Rapin I, Lindenbaum Y, Dickson DW, Kraemer KH, Robbins JH. Cockayne syndrome and xeroderma pigmentosum. *Neurology* 2000;55:1442-9.
12. Williams B, Poulter NR, Brown MJ, Davis M, McInnes GT, Potter JF, et al. Guidelines for management of hypertension: report of the fourth working party of the British Hypertension Society, 2004-BHS IV. *J Hum Hypertens* 2004;18:139-85.

The present case is relevant because Cockayne's syndrome is a rare condition and presents important oral findings (5,9). For this reason, the dentistry community must look for signs and symptoms aside from those presented in the oral cavity, so that they may recognize and diagnose the development of the syndrome and provide adequate treatment.

How the CSB gene's abnormal protein produces such alterations is not known (11) and, therefore, it should be considered in future research.

## REFERENCES

1. Lehmann AR. DNA repair-deficient diseases, xeroderma pigmentosum, Cockayne syndrome and trichothiodystrophy. *Biochimie* 2003;85:1101-11.
2. Rawlinson SC, Webster VJ. Spinal anaesthesia for caesarean section in a patient with Cockayne syndrome. *Int J Obstet Anesth* 2003;12:297-9.
3. Gorlin RJ, Cohen MM, Hennekam RCM. *Syndromes of the Head and Neck*. New York: Oxford University Press; 2001. p. 596-600.
4. Shiomi N, Kito S, Oyama M, Matsunaga T, Harada YN, Ikawa M, et al. Identification of the XPG region that causes the onset of Cockayne syndrome by using Xpg mutant mice generated by the cDNA-mediated knock-in method. *Mol Cell Biol* 2004;24:3712-9.
5. Schneider PE. Dental findings in a child with Cockayne's syndrome: Case reports. *J Dent Child* 1983;50:58-64.
6. Tuo J, Chen C, Zeng X, Christiansen M, Bohr VA. Functional crosstalk between hOgg1 and the helicase domain of Cockayne syndrome group B protein. *DNA Repair (Amst)*. 2002;1:913-27.
7. Nance MA, Berry SA. Cockayne syndrome: review of 140 cases. *Am J Med Genet* 1992;42:68-84.
8. Horibata K, Iwamoto Y, Kuraoka I, Jaspers NG, Kurimasa A, Oshimura M, et al. Complete absence of Cockayne syndrome group B gene product gives rise to UV-sensitive syndrome but not Cockayne syndrome. *Proc Natl Acad Sci U S A*. 2004;101:15410-5.