

## Drill failure during ORIF of the mandible. Complication management

Lipa Bodner <sup>1</sup>, Yizthak Woldenberg <sup>1</sup>, Max Puterman <sup>2</sup>

(1) Department of Oral and Maxillofacial Surgery

(2) Department of Otolaryngology Head and Neck Surgery. Soroka University Medical Center and Ben Gurion University of the Negev, Beer-Sheva, Israel

### Correspondence:

Prof. Lipa Bodner,

Department of Oral and Maxillofacial Surgery,

Soroka Medical Center,

P.O. Box 151,

Beer-Sheva 84101, Israel.

E-mail: lbodner@bgu.ac.il

Received: 8-02-2007

Accepted: 1-06-2007

Bodner L, Woldenberg Y, Puterman M. Drill failure during ORIF of the mandible. Complication management. Med Oral Patol Oral Cir Bucal. 2007 Dec 1;12(8):E591-3.

© Medicina Oral S. L. C.I.F. B 96689336 - ISSN 1698-6946

### Indexed in:

-Index Medicus / MEDLINE / PubMed  
-EMBASE, Excerpta Medica  
-SCOPUS  
-Indice Medico Español  
-IBECs

### ABSTRACT

A case of a drill breakage during open reduction and internal fixation (ORIF) of a mandibular fracture is reported. The clinical decision, diagnosis and surgical management of the complication are described.

**Key words:** Mandible, fracture, fracture fixation, internal, operative complication.

### INTRODUCTION

The use of ORIF with or without intermaxillary fixation is considered the standard of care for mandibular fractures (1,2) The reported complications of this technology include: malunion, infection, disturbed wound healing, hypoesthesia or paresthesia, impalement of tooth or the inferior alveolar canal and fracture of miniplate (3).

Breakage of surgical instruments, as an intraoperative complication have been reported sporadically in the orthopedic literature (4,5), where surgical drills account for the most common instrument to be broken (6). We are unaware of reports on drill breakage as an intraoperative complication in oral and maxillofacial surgery, though it is a quite common mishap.

The aim of the present report is to describe an unusual case of a drill breakage during ORIF of a mandibular fracture its diagnosis, operative and postoperative management.

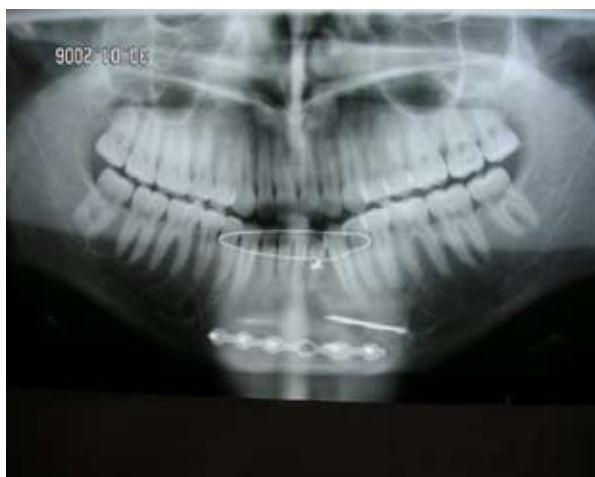### REPORT OF CASE

A 20-year-old male patient with a comminuted fracture of the left mandible was scheduled for ORIF under general anesthesia, using a 2.0 mm Craniomaxillofacial Fixation system (W. Lorenz Surgical, Jacksonville, Florida, USA). A 1.5 twist drill (1.5x115 mm, 37mm Stop, 01-9203) was used to place a 2.0 mm, 6-hole, straight, regular, mono-cortical mini plate. While drilling at the far left side of the

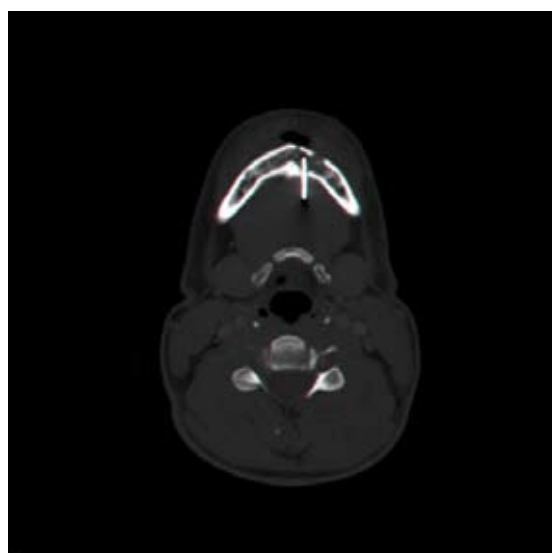
mandible, the drill brok. Attempts to retrieve the drill bit were unsuccessful. This included, creation of a 5 mm hole in the buccal cortex, allowing to insert into the medulla a spoon-shaped excavator, periodontal curette and a magnet. Intraoperative fluoroscope revealed that the broken drill was in situ, but did not enable a precise localization. A clinical decision was made to go ahead with the ORIF procedure and to postpone the retrieval of the drill. Postoperative panoramic radiograph (Fig 1) demonstrated that the drill was located adjacent to the left mental foramen. Axial CT of the mandible (Fig 2) showed that the drill was located partially in the medulla of the mandible but most of its length outside the mandible, extending through the lingual cortex toward the floor of the mouth. Under local anesthesia via a lingual approach the drill was retrieved (Fig 3). The follow up was uneventfull.

### DISCUSSION

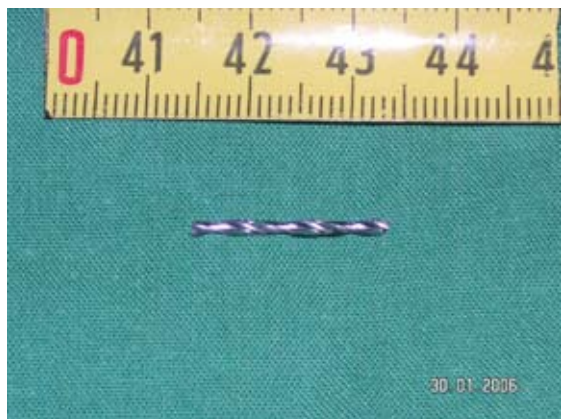The application of internal fixation in maxillofacial trauma is among the great advances that have been made in the field. The use of this technique has resulted in many advantages for the patients, however complications can arise (3). The most common complications are malunion, infection / osteitis, paresthesia and iatrogenic piercing of tooth roots or the mandibular canal.



**Fig. 1.** Panoramic photograph demonstrate that the broken drill is located horizontally anterior to the mental foramen and superior to the left part of the mini plate. The bucco-lingual localization of the drill is still unclear.



**Fig. 2.** Axial CT of the mandible shows that the drill is parallel to the midsagittal plane. A small part of the drill is located in the medulla of mandible while most of it is outside the jaw extending through the lingual cortex of the mandible toward the floor of the mouth.



**Fig. 3.** The broken drill 19 mm long, after its removal.

Instrument breakage as an operative complication during ORIF, have been reported in orthopedic surgery, and drill breakage is the most common one (6). The fact that in many trauma centers the drills used for ORIF are re-used, may be in part, the reason for the high breakage rate. It is likely that re-used drills are at increased risk of failure. It was proposed that surgeons should ensure the single use by bending them at the end of each case to prevent re-use (7).

Equipment failure, such as fracture of bicortical screws or fracture of intermaxillary fixation screws have been reported in oral and maxillofacial surgery (8,9). Drill bit breakage was mentioned among the disadvantages of the standart self-tapping screws and the rational for development of the drill free screws (10).

In the present case, the intraoperative attempts to retrieve the broken drill bit were unsuccessful. This was apparently due to lack of adequate imaging that could tell the precise location of the drill. A clinical decision was made that no additional trauma could be justified under these circumstances and the drill was left in situ. The next day and following the analysis of the panoramic radiograph and axial CT of the mandible, the precise location of the drill was determined and consequently the lingual surgical approach, under local anesthesia, was selected and performed successfully.

How mandatory is it to remove a broken drill? According to guidelines offered in orthopedic surgery, a broken drill bit that is not in contact with an implant or a screw can be left in situ without any risk of delayed healing. However a drill fragment that is situated near a joint or one that can be easily removed without further trauma to the bone, should be removed. Once the fracture has healed the broken drill bit should be removed along with the implant (11).

It seems that these guidelines, with some adjustments, may be adopted to oral and maxillofacial surgery.

The following guidelines are recommended:

- Ideally, a broken drill should be removed intraoperatively.
- The amount of effort to remove the drill intraoperatively, without having optimal imaging, should be restricted to "minor surgery".
- The patient should be informed about the complication and the future steps to be taken.
- As soon as possible, appropriate imaging modalities (panoramic radiograph, occlusal radiograph, axial CT scan) should be performed to determine the precise location of the drill.
- A clinical decision should be made, whether or not to remove the drill, based on the following parameters: the length and the exact location, possible future damage if left in situ, proximity to nerves or tooth buds, extent of surgery required for removal, possible iatrogenic damage during the removal and the patient's personality and understanding of the situation.

## REFERENCES

1. Dimitroulis G. Management of fractured mandibles without the use of intermaxillary wire fixation. *J Oral Maxillofac Surg.* 2002 Dec;60(12):1435-8.
2. Mukerji R, Mukerji G, McGurk M. Mandibular fractures: Historical perspective. *Br J Oral Maxillofac Surg.* 2006 Jun;44(3):222-8.
3. Ellis E 3rd. Complications of rigid internal fixation for mandibular fractures. *J Craniomaxillofac Trauma.* 1996 Summer;2(2):32-9.
4. Fothi U, Perren SM, Auer JA. Drill bit failure with implant involvement--an intraoperative complication in orthopaedic surgery. *Injury.* 1992;23 Suppl 2:S17-29.
5. Williams RL, Kunzru KM. A new technique for the removal of a broken cannulated screw. *Injury.* 1995 Jan;26(1):59-60.
6. Price MV, Molloy S, Solan MC, Sutton A, Ricketts DM. The rate of instrument breakage during orthopaedic procedures. *Int Orthop.* 2002;26(3):185-7.
7. Ashford RU, Pande KC, Dey A. Current practice regarding re-use of trauma instrumentation: results of a postal questionnaire survey. *Injury.* 2001 Jan;32(1):37-40.
8. Ellis JA Jr, Laskin DM. Analysis of seating and fracturing torque of bicortical screws. *J Oral Maxillofac Surg.* 1994 May;52(5):483-6.
9. Coburn DG, Kennedy DW, Hodder SC. Complications with intermaxillary fixation screws in the management of fractured mandibles. *Br J Oral Maxillofac Surg.* 2002 Jun;40(3):241-3.
10. Heidemann W, Gerlach KL, Gröbel KH, Köllner HG. Drill Free Screws: a new form of osteosynthesis screw. *J Craniomaxillofac Surg.* 1998 Jun;26(3):163-8.
11. Hirt U, Auer JA, Perren SM. Drill bit failure without implant involvement--an intraoperative complication in orthopaedic surgery. *Injury.* 1992;23 Suppl 2:S5-16.