

Dados estos hallazgos descritos en las numerosas pruebas realizadas, el diagnóstico parece compatible con una ascitis nefrogénica. Debido a su situación basal, incapaz de asumir su autocuidado, el paciente no es candidato a diálisis peritoneal. Asimismo, se descartó el trasplante renal debido a su comorbilidad y su importante arterioesclerosis ilíaca bilateral. De acuerdo con el Servicio de Digestivo, se manejó con paracentesis evacuadora a demanda. Se intensificó la terapia dialítica y se pautó nutrición parenteral intradiálisis con mejoría progresiva de los parámetros nutricionales y desaparición completa del cuadro de ascitis. En la actualidad el paciente se encuentra asintomático.

Conflictos de interés

Los autores declaran que no tienen conflictos de interés potenciales relacionados con los contenidos de este artículo.

1. Han SH, Reynolds TB, Fong TL. Nephrogenic ascites. Analysis of 16 cases and review of the literature. *Medicine* (Baltimore) 1998;77(4):233-45.
2. Cintin C, Joffe P. Nephrogenic ascites. Case report and review of the literature. *Scand J Urol Nephrol* 1994;20(3):311-4.
3. Elloumi H, Arfaoui D, Zayane A, Ajmi S. [Nephrogenic ascites. A case report]. *Ann Med Interne (Paris)* 2001;153(7):478-80.[PubMed]
4. Hammond TC, Takiyuddin MA. Nephrogenic ascites: a poorly understood syndrome. *J Am Soc Nephrol* 1994;5(5):1173-7.
5. Melero M, Rodriguez M, Araque A, Alamo C, Andrés A, Praga M. Idiopathic dialysis ascites in the nineties: resolution after renal transplantation. *Am J Kidney Dis* 1995;26(4):668-70.

Raquel Díaz-Mancebo,
Rafael Sánchez-Villanueva,
Elena González-García,
Marta Ossorio-González,
Rafael Selgas-Gutiérrez

Servicio de Nefrología.
Hospital Universitario La Paz. Madrid.

Correspondencia: Raquel Díaz Mancebo
Servicio de Nefrología.
Hospital Universitario La Paz.
Paseo de la Castellana 261. 28046 Madrid.
rdiazm.hulp@salud.madrid.org

Postpartum hemolytic uremic syndrome with multiple organ involvement in a severe case

Nefrología 2012;32(3):408-10

doi:10.3265/Nefrologia.pre2012.Jan.11334

Dear Editor,

Postpartum hemolytic uremic syndrome (PHUS), first described in 1968, is defined as a thrombotic microangiopathy (TMA) typically following a normal delivery after a symptom-free interval (mean 26.6 ± 35 days).¹ It usually occurs in primigravida with the mean age of 27.0 ± 6 years and preeclampsia is historically associated with the disease.^{1,2} The involvement of extrarenal vascular beds in PHUS has been less reported. Here we report for the first time a severe case of PHUS complicated by pancreatic necrosis, bilateral visual loss due to central retinal artery occlusion (CRAO) and disseminated intravascular coagulation (DIC).

A 20-year-old primigravid was admitted for edema and headache when she was 34 weeks pregnant. On presentation her blood pressure (BP) was 180/115 mmHg and moderate edema on face was noted. Initial investigations showed 3+ proteinuria and normal serum creatinine (Scr) concentration. The diagnosis of preeclampsia was established and a cesarean section was performed in the 35th week of gestation.

Nine days later, the patient complained of oliguria, nausea with BP of 175/105 mmHg. Laboratory tests revealed hemolytic anemia, with hemoglobin of 81 g/L, serum haptoglobin < 0.2 g/L, and schistocytes shown in peripheral blood smear. Platelets (Plt) were markedly reduced at 41×10^9 /L and an acute rise of Scr to $463.2 \mu\text{mol/L}$ showed acute renal failure. The immunologic studies revealed negative anti nuclear antibody and Coomb's tests. Under suspicion of PHUS, antihypertensives, aspirin and furosemide were commen-

ced on the 1st day of presentation and renal biopsy was performed on day 2.

The patient complained of left-upper abdominal pain after renal biopsy and developed a sudden bilateral painless visual loss. The subcutaneous bleeding over her upper arms was noted and she rapidly developed anuria, dyspnea, confusion, hypotension with BP of 70/50 mmHg. The ultrasound scan excluded the existence of perinephric / subcapsular hematoma caused by renal biopsy. The fundus exam revealed bilateral CRAO. Laboratory tests on day 3 showed elevated serum amylase, lipase and Scr up to $625 \mu\text{mol/L}$, Plt down to 12.2×10^9 /L. The level of fibrinogen decreased to $3.82 \mu\text{mol/L}$ with delaying activated partial thromboplastin time and positive D-dimer. Computed tomography scan confirmed pancreatic necrosis. Renal pathology showed thickened glomerular capillary walls with subendothelial edematous expansion that forming double contouring and renal arteriolar intimal expansion with fibrin exudation on the arteriolar wall (Figure 1). Based on these findings, the diagnosis of PHUS complicated by pancreatic necrosis, CRAO and DIC was established.

She was treated with pulse methylprednisolone 500mg/d and intravenous immunoglobulin (IVIG) 20g/d for 3 days. Meanwhile, plasma exchange (PE) with fresh frozen plasma (FFP) infusion and CRRT were initiated. Anticoagulant therapy for DIC and CRAO were also carried out. On day 15, she was improved significantly and the urinary output increased whereas the bilateral vision improved only slightly and hyperglycemia became noted. On review after 6 months of onset, she remained bilateral visual loss, elevated blood glucose and Scr when hemodialysis and subcutaneous injection of insulin were suspended. These showed the irreversible visual impairment, secondary diabetes mellitus dependent on insulin and the progression to CRF.

HUS and thrombotic thrombocytopenic purpura (TTP), collectively referred to

as TMAs, occur with increased frequency during pregnancy or the postpartum period. These two disorders are considered by many to be manifestations of the same disease process; however, others consider HUS and TTP to be distinct entities.³ Since TTP and HUS share many overlapping features, distinguishing the two disorders may be difficult.⁴ As in the case we showed, the patient developed TMA with disturbance of consciousness that seemed to suggest TTP; however, the prominent renal insufficiency and the lack of diffused thrombi in renal tissue might support PHUS rather than TTP. Another differential diagnosis should be included in this case is hemolysis, elevated liver enzymes, and low platelets syndrome (HELLP syndrome). HELLP, usually associated with preeclampsia is more common in multiparous women and approximately 70% of HELLP occur prior to term, with the remainder usually occurring within 48 hours after delivery.⁵ Patients with HELLP frequently present with severe right upper quadrant pain. Based on these characteristics of HELLP, we prefer to diagnose our case as PHUS.

Although the pathogenesis of PHUS is unknown, the previous cases reported^{2,6,7} and the case presented here demonstrated preeclampsia could possibly trigger PHUS by causing platelet aggregation, deposition of microthrombi and occlu-

sions in the microvasculature of the kidney, resulting in acute renal failure. The deficiency of ADAMTS-13, a metalloprotease that cleaves ultra-large von Willebrand factor (VWF) multimers observed in PHUS⁸ which suggest PHUS may be also associated with ADAMTS-13 deficiency. Recent studies revealed alternative complement 3 convertase dysregulation were detected in most PHUS patients suggesting PHUS was probably associated with complement gene mutation.⁹

Multiple organ involvement such as pancreas and ocular structures were reported in non-pregnancy-related HSP,^{10,11} whereas PHUS involving extrarenal vascular beds has been less reported so far except central nervous system and liver damage.^{12,13} Does this mean PHUS have a better prognosis than non-pregnancy HUS? The case we described here developed multiple organ damage such as pancreatic necrosis, CRAO, DIC and progressed to secondary diabetes mellitus, bilateral visual loss and CRF eventually. The severe complications of pancreatic necrosis and CRAO might be the manifestations of TMA in PHUS, but might be more likely induced by DIC in this patient. Anyway, this case suggests PHUS could also involve multiple organ dysfunctions and resulted in bad outcomes even if the appropriate treatments were given without delay.

The renal pathology in HUS is characterized by glomerular capillary subendothelial expansion, arteriolar fibrinoid necrosis, arterial edematous intimal expansion and vascular thrombosis. The preceding etiologic conditions of HUS and the histological findings appeared not to be related to each other.¹⁴ Our case showed typical subendothelial edematous expansion and renal arteriolar intimal expansion with fibrin exudation which supported renal microangiopathy, but without diffused thrombi and fibrinoid necrosis in renal tissue which seemed to be inconsistent with the following development of multiple organ complications and the progression to CRF. This was considered to be due to the early performance of renal biopsy after the attack and the early pathological findings in PHUS presented here may be difficult to predict the disease development and poor prognosis.

In conclusion, pancreatic necrosis, CRAO and DIC were observed in PHUS. Although renal replacement therapy and PE with FFP infusion have improved the survival of PHUS significantly, multiple organ complications such as pancreatic necrosis, CRAO and DIC may cause severe sequelae and lead to a poor prognosis of PHUS.

Conflict of interest

The authors declare that there is no conflict of interest associated with this manuscript.

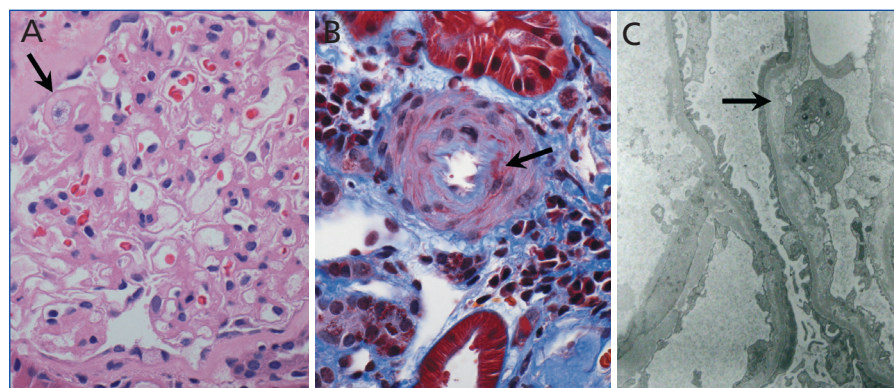


Figure 1. Renal biopsy findings in postpartum hemolytic uremic syndrome (A) Light microscopy showing thickened glomerular capillary walls forming double contouring (H & E stain, x400). (B) Light microscopy showing renal arteriolar intimal expansion with fibrin exudation on the arteriolar wall (Masson stain, x400). (C) Electron micrograph showing thickened glomerular capillaries and subendothelial edematous expansion (x4000).

1. Weiner CP. Thrombotic microangiopathy in pregnancy and the postpartum period. *Semin Hematol* 1987;24:119-29.
2. Santos Nores J, Bravo López JJ, Borrajo Prol MP, Iglesias Forneiro A. HTA-pre-eclampsia-postpartum haemolytic-uraemic syndrome: good results can be achieved. *Nefrologia* 2010;30:593-4.
3. Hosler GA, Cusumano AM, Hutchins GM. Thrombotic thrombocytopenic purpura and hemolytic uremic syndrome are distinct pathologic entities. A review of 56 autopsy cases. *Arch Pathol Lab Med* 2003;127:834-9.
4. George JN. The thrombotic thrombocytopenic purpura and hemolytic uremic syndromes: overview of pathogenesis (Experience of The Oklahoma TTP-HUS Registry, 1989-2007). *Kidney Int Suppl* 2009;(112):S8-S10.

5. Kirkpatrick CA. The HELLP syndrome. *Acta Clin Belg* 2010;65:91-7.
6. Iannuzzi M, Siconolfi P, D'Angelillo A, Capuano M, Tufano L, Macri M. A postpartum hemolytic-uremic-like-syndrome in a patient with pre-eclampsia: description of a clinical case. *Transfus Apher Sci* 2006;34:11-4.
7. Karam JS, Pitirangon P, Wheat H, Stefanick B, Venuto RC. Postpartum hemolytic uremic syndrome in a patient with preexisting hypertension and resolving preeclampsia. *Clin Nephrol* 2007;68:38-41.
8. Vesely SK, George JN, Lämmle B, Studt JD, Alberio L, El-Harake MA, et al. ADAMTS13 activity in thrombotic thrombocytopenic purpura-hemolytic uremic syndrome: relation to presenting features and clinical outcomes in a prospective cohort of 142 patients. *Blood* 2003;102:60-8.
9. Fakhouri F, Roumenina L, Provot F, Sallée M, Caillard S, Couzi L, et al. Pregnancy-associated hemolytic uremic syndrome revisited in the era of complement gene mutations. *J Am Soc Nephrol* 2010;21:859-67.
10. Primhak RA, Taitz LS, Variend S, Webb DH, Cser A. Necrosis of the pancreas in the haemolytic uraemic syndrome. *J Clin Pathol* 1984;37:655-8.
11. Sturm V, Menke MN, Landau K, Laube GF, Neuhaus TJ. Ocular involvement in paediatric haemolytic uraemic syndrome. *Acta Ophthalmol* 2010;88:804-7.
12. Lampinen K, Peltonen S, Pettilä V, Kaaja R. Treatment of postpartum thrombotic microangiopathy with plasma exchange using cryosupernatant as replacement. *Acta Obstet Gynecol Scand* 2004;83:175-9.
13. Mocan H, Mocan MZ. Postpartum hemolytic uremic syndrome with a more severe liver involvement. *Clin Nephrol* 1998;49:319-20.
14. Matsumae T, Takebayashi S, Naito S. The clinico-pathological characteristics and outcome in hemolytic-uremic syndrome of adults. *Clin Nephrol* 1996;45:153-62.

Guang-Yu Zhou

Department of Nephrology, China-Japan Union Hospital of Jilin University, Changchun, Jilin Province (China)

Correspondencia: Guang Yu Zhou

Department of Nephrology, China-Japan Union Hospital of Jilin University, No.126, Xiantai Street, 130033, Changchun, Jilin Province, China.
guangyu8@yahoo.com.cn
zhougy@jlu.edu.cn

Colangitis esclerosante primaria y nefropatía intersticial: ¿una asociación emergente?

Nefrología 2012;32(3):410-2

doi:10.3265/Nefrología.pre2012.Jan.11305

Sr. Director:

La colangitis esclerosante primaria (CEP) es una enfermedad hepática colestásica crónica, caracterizada por inflamación y fibrosis de los conductos biliares intra y extrahepáticos, que afecta fundamentalmente a varones de edad media^{1,2}. Puede presentarse de forma aislada o en asociación con enfermedad inflamatoria intestinal. Su mecanismo etiopatogénico es desconocido, aunque evidencias crecientes apuntan a factores genéticos e inmunológicos como los responsables de su etiopatogenia¹.

La asociación de nefropatía intersticial en pacientes con enfermedad hepática colestásica crónica se ha descrito en la literatura en los años noventa en población pediátrica y se sugería que esta asociación podría representar un nuevo síndrome^{3,4}.

Recientemente se ha propuesto la existencia de una nueva entidad denominada «enfermedad esclerosante relacionada con la IgG4»^{5,6}.

Publicamos el caso de una mujer con el diagnóstico de CEP que presentó una nefropatía intersticial severa.

CASO CLÍNICO

Mujer de 77 años de edad remitida a la consulta de Nefrología por creatinina plasmática de 2,4 mg/dl. Entre sus antecedentes personales destacaban diversas intervenciones quirúrgicas: (menisco en 1985; timoma con anatomía patológica benigna en 1999; pólipos nasosinusales hacía más de 20 años y en 2008; varices en 2006; cistocele en 2008; fractura de cadera en julio de 2010); colangitis esclerosante primaria diagnosticada en el año 2003, en tratamiento con ácido ursodesoxicólico. En varias ocasiones se había realizado cateterismo biliar retrógrado con esfinte-

rectomía y dilatación de zonas de estenosis. También se había diagnosticado de enfermedad inflamatoria intestinal por la misma época; en el seguimiento posterior se le practicaron varias colonoscopias que en unas ocasiones eran normales y, en otras, mostraban mínimas ulceraciones a nivel iliocolon y en colon. Pericarditis de etiología no filiada en enero de 2010. Gonartrosis bilateral. Intolerancia al hierro oral. No tenía hábitos tóxicos.

En el primer momento de ser vista en consulta externa se encontraba en tratamiento con zolpidem, 10 mg/día; ácido ursodesoxicólico, 1250 mg/día; pantoprazol, 40 mg/día; mirtazapina, 15 mg/día; dextropropoxifeno, y paracetamol de forma ocasional.

En el interrogatorio refería intenso cansancio, disnea de medianos esfuerzos; disminución del apetito; náuseas ocasionales con la tos; estreñimiento habitual de unos 48 horas que alternaba con diarrea de 3 a 4 deposiciones al día, pero sin presencia de productos patológicos; nicturia de 2 veces desde hacía unos meses; micciones diurnas cada 3-4 horas; no relataba antecedentes de crisis renoureterales ni haber tenido hematuria.

En cuanto a sus antecedentes familiares, padres fallecidos en edad avanzada y tres hermanos fallecidos por tumores.

En la exploración física: talla: 159 cm; peso: 53 kg. Presión arterial: 137/72 mmHg; frecuencia cardíaca: 95 lpm. Sin ingurgitación yugular; carótidas rítmicas y simétricas; auscultación cardiopulmonar normal; en el abdomen destacaba una hepatomegalia de alrededor de 4 traveses de dedo más evidente en lóbulo derecho, no dolorosa y sin soplos abdominales. Extremidades: sin edemas y pulsos distales presentes.

Revisada la historia analítica, se observó que en noviembre de 2010 la creatinina plasmática osciló entre 2,4-2,5 mg/dl; en diciembre de 2010 la creatinina plasmática fue de 2,9 mg/dl y en enero de 2011, de 2,7 mg/dl.