

---

Original

## Unremitting early stage Hodgkin disease: Report of 7 cases and bone marrow tissue immunohistochemical marker study

D. Tamiolakis<sup>1</sup>, S. Nikolaidou<sup>1</sup>, A. Kotini<sup>2</sup>, T. Jivannakis<sup>3</sup>, A. Efthimiadou<sup>4</sup>, P. Boglou<sup>5</sup>, S. Bolioti<sup>1</sup>, J. Venizelos<sup>5</sup>

### Summary

Bone marrow is infrequently implicated in early stage Hodgkin's disease. We studied the immunohistochemical bone marrow tissue of 7 out of 20 cases with early stage Hodgkin's disease of the mixed cellularity variant, diagnosed by lymph node biopsy at initial presentation, not responding to radiotherapy alone, in order to examine possible marrow attack. A statistically significant prevalence of CD45, CD45RO, and CD4 positive infiltrates, to the advantage of unremitting hosts, was found. The predominance of CD4-positive cells in the bone marrow space: 1) might be suggestive of involvement in the process, 2) could explain the abnormal cytokine production leading to reduced T-cell immunity and inefficient antitumor response despite the existence of a vast majority of reactive infiltrating immune cells.

#### Key words:

Hodgkin's disease. Immunohistochemistry. Bone marrow

**Oncología, 2005; 28 (4):183-187**

---

<sup>1</sup> Department of Cytology, Regional Hospital of Chania

<sup>2</sup> Department of Medical Physics, Democritus University of Thrace

<sup>3</sup> Department of Pathology, General Hospital of Drama

<sup>4</sup> Department of Physiology, Democritus University of Thrace

<sup>5</sup> Department of Pathology, Ippokration General Hospital of Salonica  
Greece

Recibido: 15.04.05

Aceptado: 18.04.05

## Resumen

Es infrecuente la implicación de la médula ósea en la enfermedad de Hodgkin temprana. Estudiamos la composición inmunohistoquímica del tejido de la médula ósea en 7 de 20 casos de enfermedad de Hodgkin temprana, de la variante de celularidad mixta, diagnosticada en la presentación inicial por biopsia de los ganglios linfáticos, que no respondieron a la radioterapia sola, con objeto de examinar la posible afectación de la médula ósea. Se encontró una frecuencia estadísticamente significativa de infiltrados positivos para CD45, CD45RO y CD4 asociados a la falta de remisión de la enfermedad. El predominio de células positivas para CD4 en la composición de la médula ósea: 1) podrían corresponder a su compromiso en el proceso, 2) podrían explicar la producción anormal de citoquinas que llevan a una reducción de la capacidad inmunológica de las células T y a la ineficacia de las respuestas antitumorales, a pesar de que la gran mayoría de las células infiltrantes son células inmunológicamente reactivas.

**Palabras clave:** Enfermedad de Hodgkin. Inmunohistoquímica. Médula ósea.

## Introduction

Bone marrow involvement in Hodgkin's disease is low at initial presentation (6%) in patients with stages I and II disease and in nodular sclerosis (1, 2 and 4% respectively)<sup>1</sup>. The highest incidence of bone marrow involvement is found with lymphocyte depletion and mixed cellularity Hodgkin's disease<sup>2,3</sup>. However, since one of the criteria for systemic spread (stage IV) is involvement of the bone marrow, a bone marrow biopsy is still an integral part of the initial investigation of patients with HD.

It is of interest that CD4+ T lymphocytes with a T helper 2 (Th2)-like immunophenotype are the most abundant cell type in Hodgkin's lymphoma tissues<sup>4</sup>. Th2 cells produce IL-5, which primes T cells and activates eosinophils<sup>5</sup>. Moreover, interaction of these T cells with neoplastic cells and eosinophils also involves ligands of TNF (tumor necrosis factor) receptors (CD30L and CD40L)<sup>6</sup>. T lymphocytes as well as eosinophils transmit via these ligands proliferative and antiapoptotic signals to Hodgkin/Reed-Sternberg cells and thereby influence tumor biology<sup>6,7</sup>.

In our series, we studied the immunohistochemical profile of bone marrow infiltrates in early stages (I - II) of classical Hodgkin's disease mixed cellularity variant treated with radiotherapy alone, in order to explain partial non-response to treatment, given

that the reactive lymphocytes in HD involved marrow are predominantly CD4 positive T-cells.

## Materials and methods

Our study population included 20 patients (age range 32-72 years; 16 males and 4 females) with stage I - II Hodgkin's disease according to the Ann Arbor criteria.

All our selected cases included the classical HD mixed cellularity variety recovered from routine lymph node histological and immunohistochemical examination. The Regional Committees of Ethics approved the study. Written informed consent was obtained from all patients, and the procedures followed were in accordance with the institutional guidelines.

The genotypic profile of our HD cases (affected cervical lymph nodes) is shown in table 1. In brief, the HRS cells (the Hodgkin and Reed-Sternberg cells) of 18 cases harbored highly mutated rearranged *IgH* genes, whereas the other 2 cases displayed HRS cells with clonal TCR rearrangements. Southern blot hybridization using a specific EBV Bam HIW fragment probe, showed the presence of EBV genomes in two of our cases (patient no. 5 and 8).

The possibility that the two Hodgkin lymphomas with rearranged TCR genes were confused with anaplastic large cell lymphomas, which may mimic HD,

TABLE I

**Genotype of the classical Hodgkin's disease mixed cellularity variety (Affected cervical lymph nodes)**

Patient no	Age/sex	Genotype
1	55/M	B
2	71/M	B
3	60/F	T
4	34/M	B
5	36/M	B
6	32/F	T
7	38/M	B
8	42/F	B
9	43/M	B
10	35/M	B
11	53/M	B
12	47/M	B
13	38/F	B
14	49/M	B
15	51/M	B
16	40/M	B
17	56/M	B
18	64/M	B
19	39/M	B
20	72/M	B

was excluded by their negative labeling for ALK-1 whose expression is restricted to anaplastic large-cell lymphoma<sup>8,9</sup>. We included in our study antibodies recognizing megakaryocytes CD61 (Y2/51) to be certain that the abnormal cells are truly derived from Hodgkin's disease.

All patients were treated with radiotherapy alone. Seven of the patients showed no remission of the disease presenting the characteristic clinical symp-

toms of the disease (fever, night sweats, and weight loss). An Iliac crest trephine bone marrow biopsy was performed in all twenty subjects.

**Immunohistochemistry:** Bone marrow biopsy specimens following a short decalcification time were processed for routine and immunohistochemical examination by a panel of monoclonal antibodies against CD30 (Ber-H2), CD15 (C3D1), EMA, CD45 (LCA), CD20 (L26), CD4, CD8, ALK-1, CD45RO (UCHL1), CD56 (NK cells), CD61 (Y2/51), and CD68 (PG-M1). Immunostaining was performed on formalin-fixed, paraffin-embedded sections employing the of alkaline phosphatase anti-alkaline phosphatase (APAAP) technique<sup>10</sup>. Paraffin-embedded sections were pre-treated by pressure-cooking as previously described<sup>11</sup>.

The immunostained sections were examined with a X 40 objective and the distribution of the above antibodies within the cell was recorded. Every stained cell was scored as positive regardless of staining intensity. To count the number of positive cells, a 10 X 10 square calibrated grid was inserted into the eyepiece of an Olympus BX40 binocular microscope.

Five-to-ten high power fields were examined for each section, and at least 1000 cells were scored, depending on cellularity. The number of positive cells was recorded per high power field.

**Results** (Table II)

**Histology:** The bone marrow appearance was that of a hypercellular one in eight cases, a hypocellular

TABLE II

**Immunophenotype of the classical Hodgkin's disease mixed cellularity variety (Bone marrow biopsy)**

Immunohistochemistry	Untreated cases No 7	Treated cases No 13	Statistic analysis
CD45(+) cells/mm <sup>2</sup>	68.1±20.8	45.7±15.2	P=0.021
CD45 RO (+) cells/mm <sup>2</sup>	70.4±32.7	32.5±17.8	P=0.019
CD4 (+) cells/mm <sup>2</sup>	38.20±6.4	28.90±7.60	P=0.015
CD61 (+) cells/mm <sup>2</sup>	2.65±0.73	2.55±0.81	Non significant
CD20(+) cells/mm <sup>2</sup>	9.1±2.7	8.9±1.8	Non significant
CD56(+) cells/mm <sup>2</sup>	—	—	—
CD30(+) cells/mm <sup>2</sup>	—	—	—
CD15(+) cells/mm <sup>2</sup>	—	—	—
EMA(+) cells/mm <sup>2</sup>	—	—	—
CD68(+) cells/mm <sup>2</sup>	3.12±0.38	3.21±0.79	Non significant
CD8(+) cells/mm <sup>2</sup>	5.68±0.96	5.85±1.08	Non significant
ALK(+) cells/mm <sup>2</sup>	—	—	—

## D. Tamiolakis y cols.

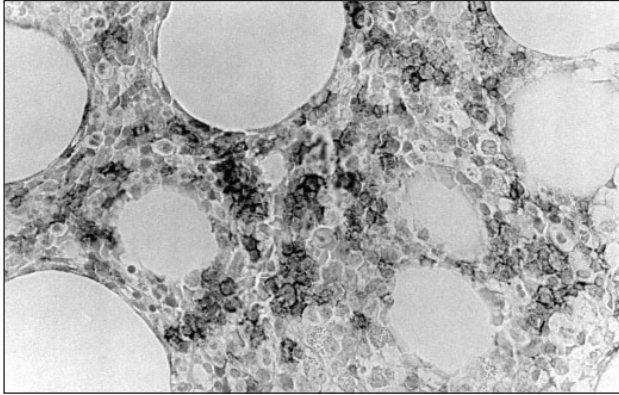


Figure 1. Immunohistochemical expression of CD4 in the bone marrow space in patients with untreated stage I - II Hodgkin's disease (strong reactivity). Immunostaining with CD4 Mab, APAAP technique, original magnification X400.

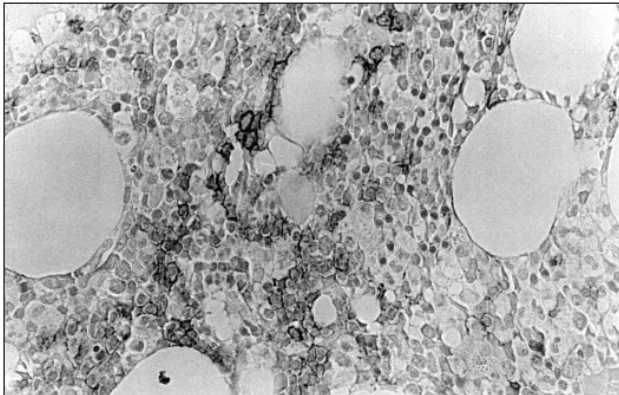


Figure 2. Immunohistochemical expression of CD4 in the bone marrow space in patients with treated stage I - II Hodgkin's disease (mild reactivity). Immunostaining with CD4 Mab, APAAP technique, original magnification X400.

in seven, and a normocellular in the remaining ones. In all twenty patients no replacement of the bone marrow space by fibrous or granulomatous tissue was observed.

**Immunohistochemistry:** The sections were examined independently by two observers, and positive cellular staining for the relevant antibodies were manifested as yellow cytoplasmic granularity and / or surface membrane expression.

There was: 1) No evidence of lymphocyte-rich Hodgkin's disease (L&H cells), mononuclear HD, binuclear HD, or nodular sclerosis variant (lacunar cells): CD30-, CD15-, EMA-. 2) Evidence for the presence of megakaryocytes: CD61+. 3) A mild in-

crease in the number of the lymphoid cells constituting up to 20% - 25% of the nucleated cell population in the bone marrow: CD45+. The T-cell to B-cell ratio had been estimated of 81 to 91. Lymphocytes of small-cell type, preferentially located in the center of marrow space, were arranged either in small clusters of 2-10 lymphocytes resembling minute bunches of grapes, or in 1-2 cell thickness layers distributed in a way that we have called "streamlet like" pattern or "Indian" like. A paratrabecular pattern of localization has not been considered, while randomly reactive lymphoid follicles were observed. On immunohistochemical grounds the lymphocytes were identified as of T-cell origin. Such a cellular arrangement has been considered as a piece of evidence against lymphomatous lesion.

A predominance of CD4 expression in the bone marrow stroma was found in the seven non-respondered patient-cases (Fig. 1) over the thirteen cases with a favorable outcome (Fig. 2). The difference was statistically significant ( $p=0.015$ ,  $\chi^2$  square test). A contralateral iliac crest trephine was obtained from all seven unfavorable hosts, which showed a polymorphous cellular composition of lymphocytes, plasma cells, histiocytes, neutrophils, and granulocytes. On multiple sections rare abnormal CD30 positive cells were disclosed and B.M.involvement was established. Chemotherapy was employed.

## Discussion

The diagnostic criteria of HL in BM have essentially not changed since the now historic clinical pathologic studies of Lukes and Bartl<sup>12, 13</sup>. The criteria differ somewhat depending on whether a primary diagnosis of HL is being established or whether the patient already has a diagnosis of HL established at another site.

1) Diagnostic: Typical Reed-Sternberg cells or their variants in a proper background. Mononuclear variants in a proper background are diagnostic only in patients with a previously established diagnosis.

2) Strongly suggestive, but not diagnostic: Abnormal large cells that lack the nuclear features of R-S-cells, but which are present in a cellular and/or fibrotic background that is characteristic of HL.

3) Suggestive: Focal or diffuse fibrosis or necrosis only in a previously diagnosed patient.

Various combinations of these patterns may be seen in the same biopsy specimen or in different biopsy specimens from the same patient. In addition, amorphous eosinophilic background material may be apparent. Necrosis is occasionally detected prior to treatment<sup>14</sup> but is more common in treated patients. Granulomas are sometimes associated with infiltration, but also occur in the absence of bone marrow infiltration. Reticulin is increased in areas of infiltration and collagen is often present. There is sometimes osteolysis or osteosclerosis; increased bone remodelling is usual<sup>13</sup>.

Preferentially the diagnosis of HL should be confirmed by immunohistochemistry (CD3, 20, 15, 45, 30 and EMA). When the first diagnosis of HL is made on a trephine, a biopsy of lymph node should always be performed before treatment, both for confirmation of the diagnosis and for subclassification. One should not attempt to classify HL on the basis of the BMB. The histology of HL in BM and lymph node may differ significantly, and all types of HL may produce the appearance of lymphocyte depletion and fibrosis in the BM.

In our settings we found a statistically significant ( $p=0.015$ ) higher CD4 positive bone marrow infiltrate in unremitting HD over favorable disease, and we imply this increase might indicate bone marrow involvement. On the other hand, our findings could explain that the locally produced chemokines by T-lymphocytes are implicated in the accumulation of the abundant reactive infiltrates (e.g. eosinophils) in classical HD and thereby influence tumor biology. Confirmation of this indication needs large groups of patients and longer observation time together with adverse outcome of illness.

---

Correspondence  
Tamiolakis Demetrio M.D.  
Department of Cytology  
Regional Hospital of Chania  
Crete, Greece  
E-mail: cyto@chaniahospital.gr  
alexrad@in.gr

## References

1. Frisch B, Bartl R. Biopsy Interpretation of Bone and Bone Marrow. In: Hodgkin's disease (HD). Arnold 2nd Edition 1999; p.305.
2. Neiman RS, Rosen PJ, Lukes RJ. Lymphocyte-depletion Hodgkin's disease. A clinicopathologic entity. *N Engl J Med* 1973;288:751.
3. O'Carroll DI, McKenna RW, Brunning RD. Bone marrow manifestations of Hodgkin's disease. *Cancer* 1976; 38:1717.
4. Popema S. Immunology of Hodgkin's disease. *Clin Hematol* 1996; 9:447.
5. Sallustro F, MacKay CR, Lanzavecchia A. Selective expression of the eotaxin receptor CCR3 by human T helper 2 cells. *Science* 1997; 277:2005.
6. Pinto A, Aldinucci D, Gloghini A, Zagonel V, Degan M, Perin V, Todesco M, De Iullis A, Improta S, Sacco C, Gattei V, Gruss HJ, Carbone A. The role of eosinophils in the pathobiology of Hodgkin's disease. *Ann Oncol* 1997; 8:89.
7. Pinto A, Aldinucci D, Gloghini A, Zagonel V, Degan M, Improta S, Juzbaxic S, Todesco M, Perin V, Gattei V, Herrmann F, Gruss HJ, Carbone A. Human eosinophils express functional CD30 ligand and stimulate proliferation of a Hodgkin's disease cell line. *Blood* 1996; 88: 3299.
8. Sarris AH, Luthra R, Papadimitracopoulou V, et al. Amplification of genomic DNA demonstrates the presence of the t(2;5) (p23;q35) in anaplastic large cell lymphoma, but not in other non-Hodgkin's lymphomas, Hodgkin's disease, or lymphomatoid papulosis [see comments]. *Blood* 1996; 88:1771.
9. Herbst H, Anagnostopoulos J, Heinze B, Durkop H, Hummel M, Stein H. ALK gene products in anaplastic large cell lymphomas and Hodgkin's disease. *Blood*. 1995; 86:1694.
10. Cordell JL, Falini B, Erber WN, et al. Immunoenzymatic labeling of monoclonal antibodies using immune complexes of alkaline phosphatase and monoclonal anti-alkaline phosphatase (APAAP complexes). *J Histochem Cytochem*. 1984; 32:219.
11. Norton AJ, Jordan S, Yeomans P. Brief, high- temperature heat denaturation (pressure cooking): a simple and effective method of antigen retrieval for routinely processed tissues. *J Pathol*. 1994; 173:371.
12. Lukes RJ. Criteria for involvement of lymph node, bone marrow, spleen, and liver in Hodgkin's disease. *Cancer Research* 1971; 31: 1755.
13. Bartl R, Frisch B, Burkhardt R, Huhn D, Pappenberger R. Assessment of bone marrow histology in Hodgkin's disease: correlation with clinical factors. *Br J Haematol* 1982; 51:345.
14. Kinney MC, Greer JP, Stein RS, Collins RD, Cousar JB. Lymphocyte-depletion Hodgkin's disease. Histopathologic diagnosis of marrow involvement. *Am J Surg Pathol* 1986; 10: 219.