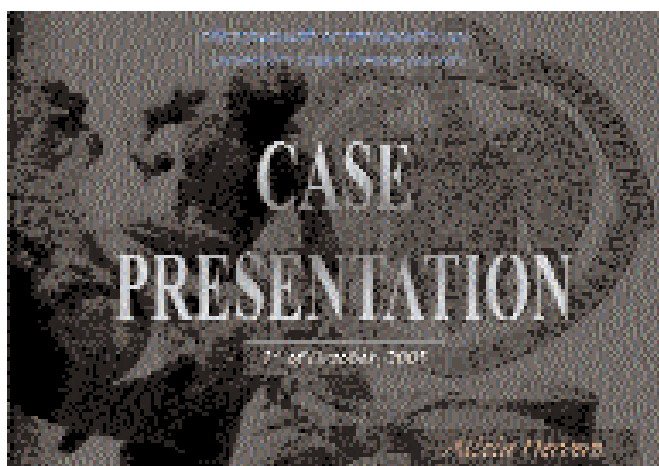


Casos Clínicos

HERRERO A*

Herrero A. *Casos Clínicos. Av Periodon Implantol.* 2005; 17, 3: 119-146.

* Máster en Periodoncia. Universidad Complutense de Madrid.



MEDICAL HISTORY

- **A.S.A Classification:** Type I.
- **Harmful habits:** Former smoker (20 cigarettes a day).
- **Parafunctional habits:** Tongue thrust.
- **Present medical illness:** Asthma.
- **Present drug treatment:** Amoxicillin/Clavulanic acid 875/125 mg + Azopropirone 600 mg (oral infection).
- **Family history:** Type 2 diabetes mellitus.

PERSONAL DATA

- **Name:** Luis I. G.
- **Age:** 47 Years old.
- **Profession:** Accountant.
- **Marital status:** Married.



CHIEF COMPLAINT

"Painful gums and loose teeth".

DENTAL HISTORY

- **Hygienic home care procedures:** Brushing with Manual toothbrush twice a day. No interdental aids.
- **Past dental history:** Full dent (10 years ago).
- **Reason of missing teeth:** Periodontitis.
- **Oral complaints:** Moderate pain (M, 2/5), bleeding and swelling gums and loose teeth. Spaces and food debris impaction. Difficulty to chew and to speak.


ADDITIONAL ANTI-EXPECTATIONS

- Physiological.
- Receptive and cooperative.
- Realistic expectations.
- Motivated.

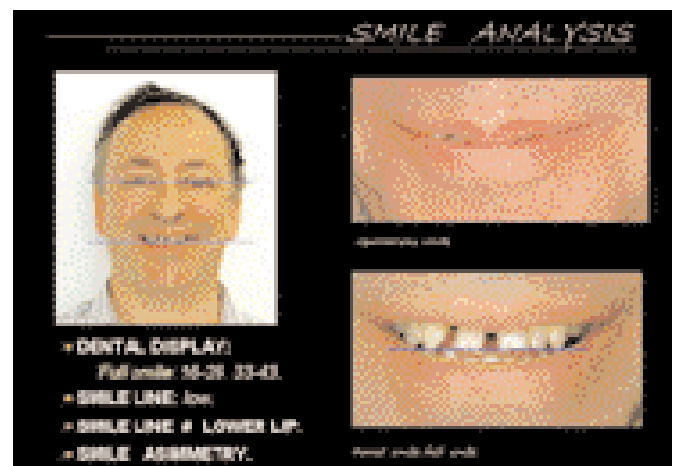
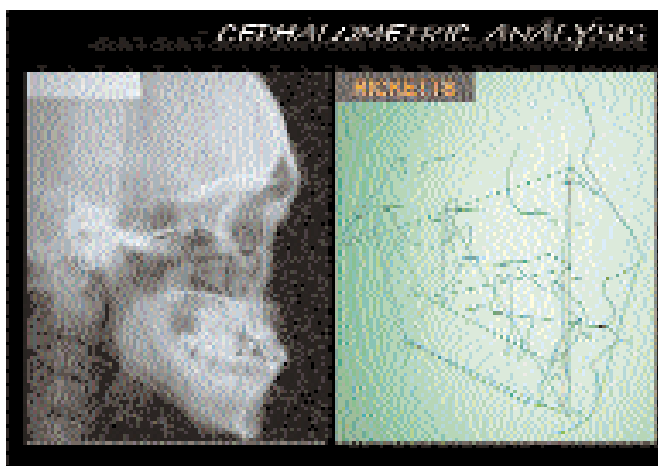
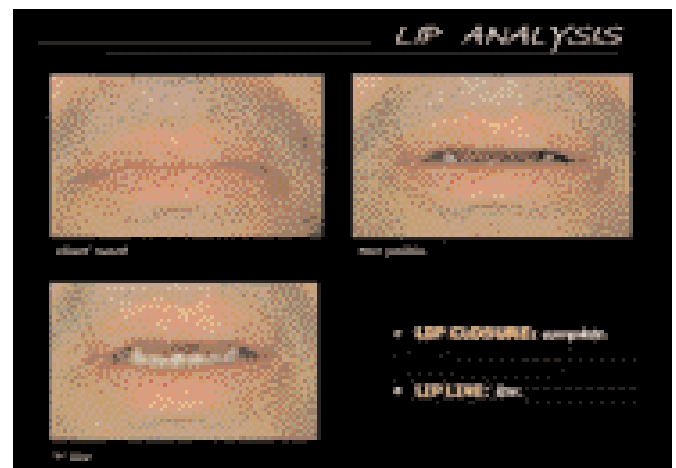


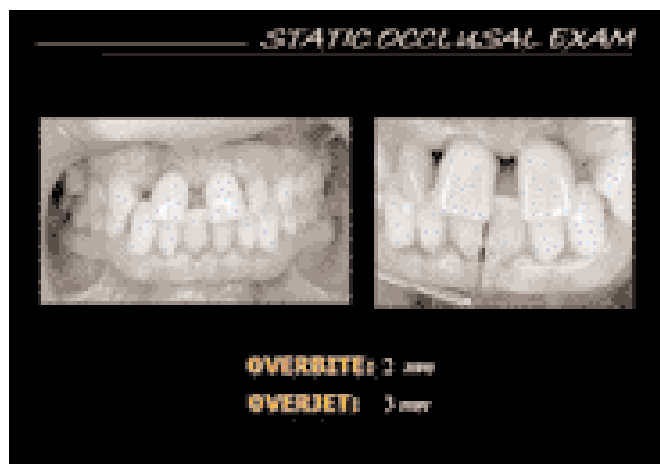
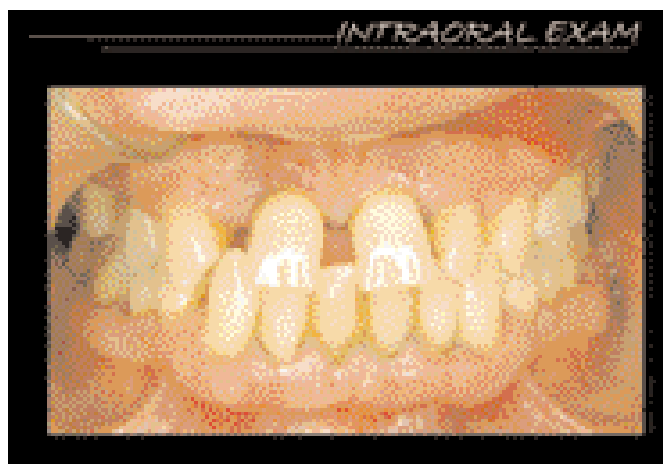
1. Health 2. Function 3. Esthetic

EXTRACRANIAL EXAM



- **FACIAL PATTERN:** brachyfacial. Gonion shape.
- Facial asymmetry.
- Left gonial cellulite.
- **TMJ ADENOPATHIES:** not relevant.





- **ABSCESSES:** 12, 26
- **CARIOUS LESIONS:** not related
- **PERIAPICAL:** 11 (B)
- **PERIODONTAL ABSCESSES:** 24, 26
- **SENSITIVITY TO PERCUSSION:** 14, 16, 17, 24, 25, 31
- **SENSITIVITY TO PALPATION:** 24, 26
- **VITALITY PULP TESTS:** positive in all teeth.
- **BILATERAL LINGUAL TORSION**
- **ADDITION:** normal edge 11, 21, 22, 23, 27, 41, 42
- **ABRASION - EROSION:** not related

MALPOSITIONS:

- **Tilted:** 12, 11, 21, 22, 24
- **Rotated:** 13, 23, 26
- **Extruded:** 11, 21, 31, 32, 34, 41, 42, 43

DIASTEMAS:

14-13, 13-11, 17-21, 21-22, 22-23, 23-24, 24-32, 43-41

STATIC OCCLUSAL EXAM

Angle Classification

- Class II molar
- Class I canine

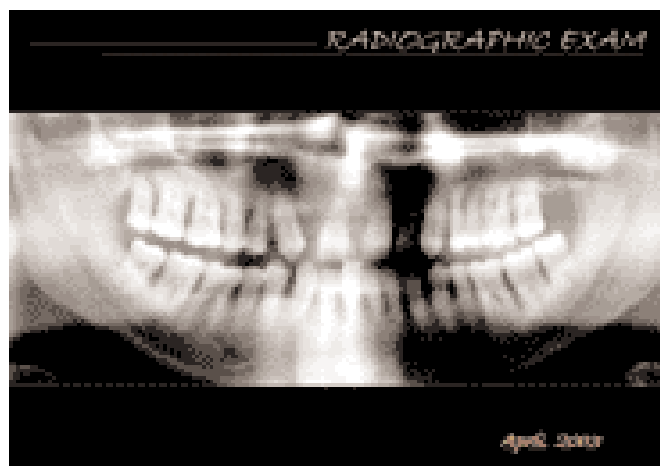
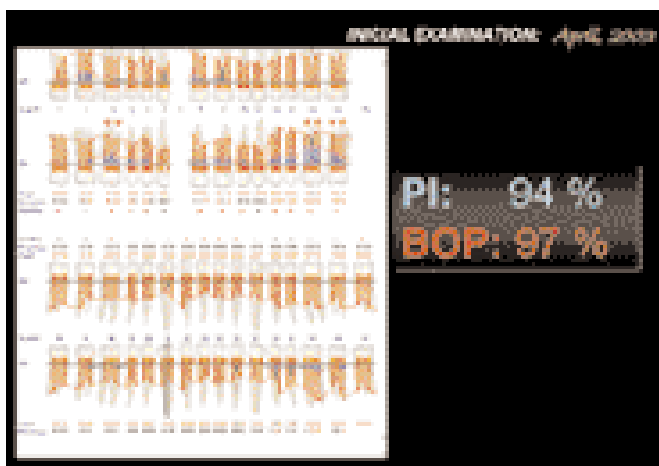
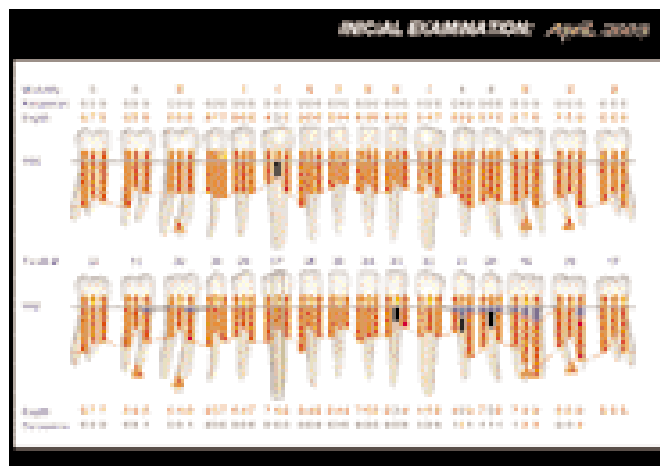

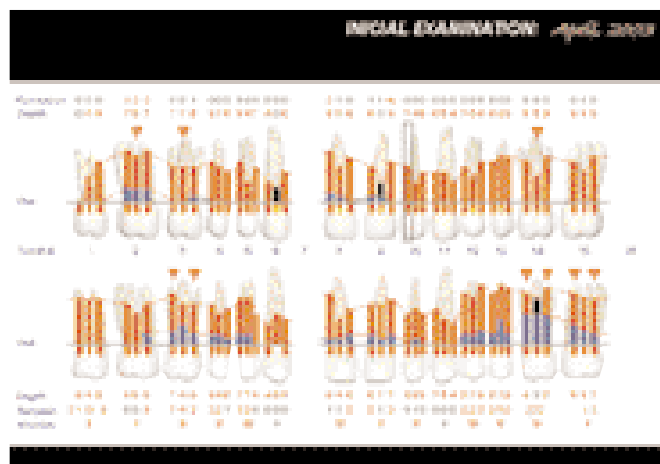
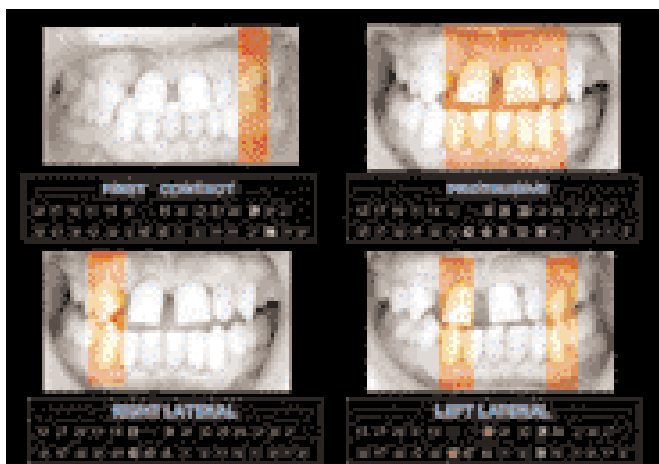
• Class III molar
• Class I canine

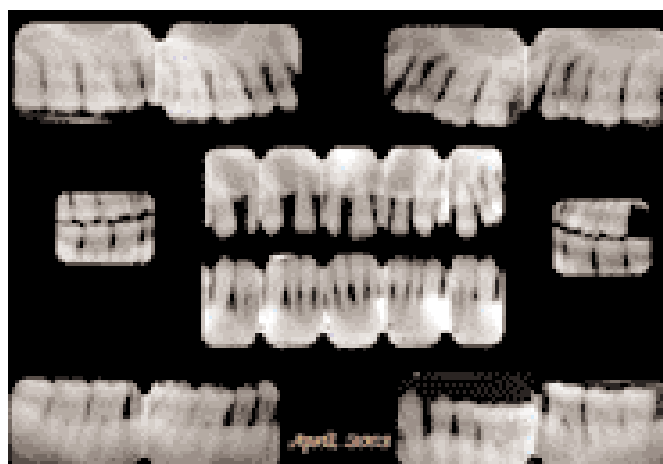
Bilateral posterior crossbite: 15, 25

DYNAMIC OCCLUSAL EXAM

- **Premolars:** 14, 13, 11, 21, 22, 24, 25
- **Mandible deviation in open-close cycle:** not related
- **Slide in centric relation:** > 1mm

Range movements:





GENERAL DIAGNOSIS

- Orthodontic problems:
 - ✓ Flaring of the maxillary anterior teeth.
 - ✓ Posterior bite collapse.
 - ✓ Tongue – thrusting habit
- Esthetic and restorative problems:
 - ✓ Flare anterior teeth.
 - ✓ Missing teeth and diastemas.
 - ✓ Tipped abutment teeth

MICROBIOLOGICAL EXAM



ETHIOLOGY

- Main factor: dental plaque.
- Secondary factors: tobacco, teeth malpositions, occlusal trauma.

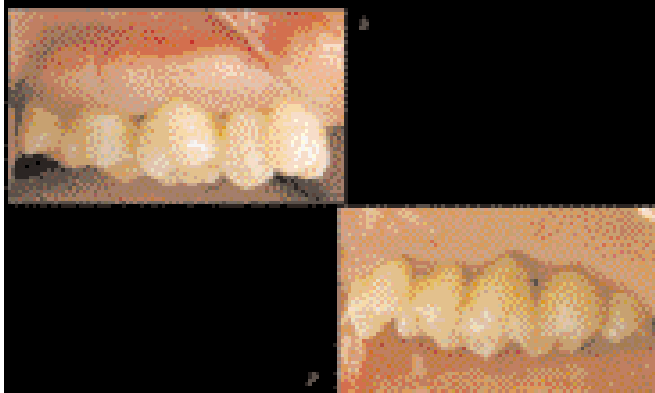
PROGNOSIS

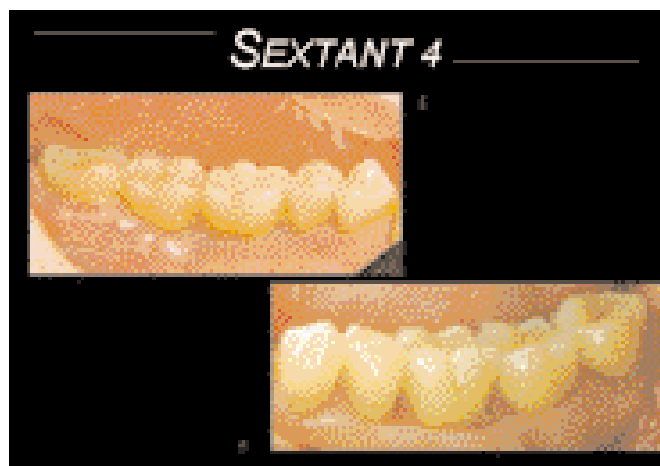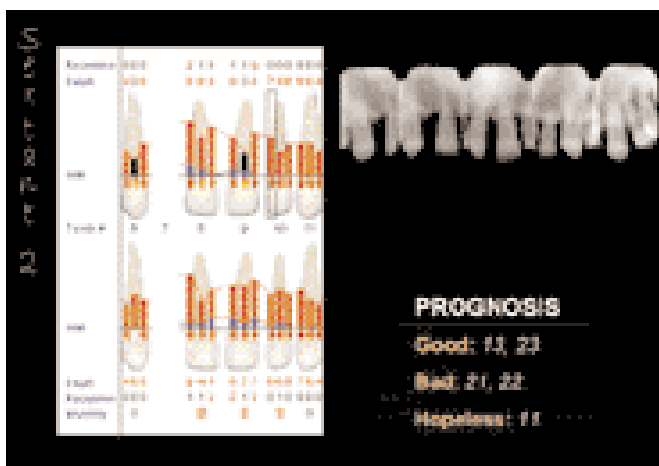
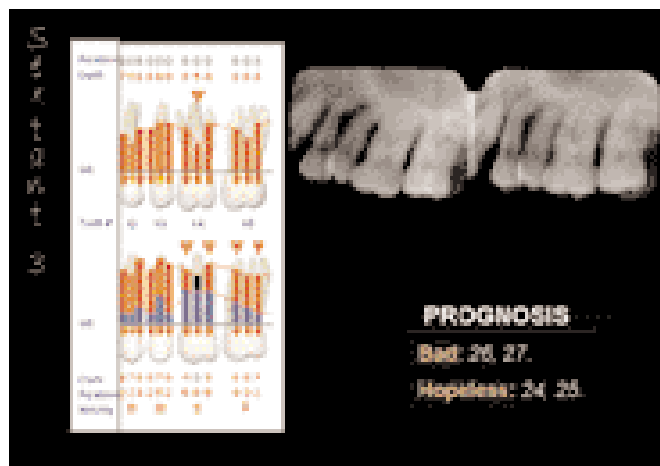
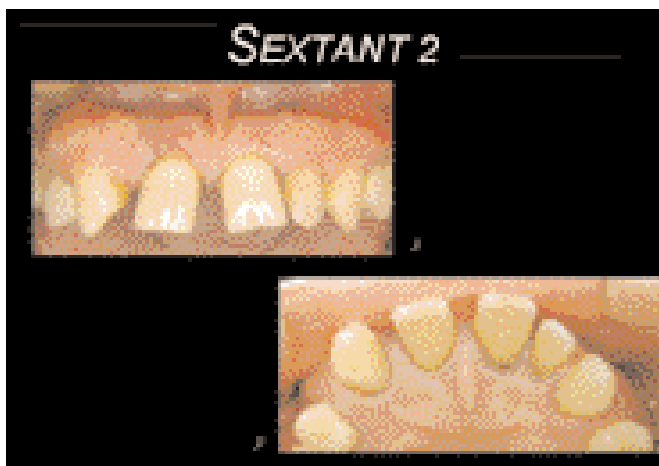
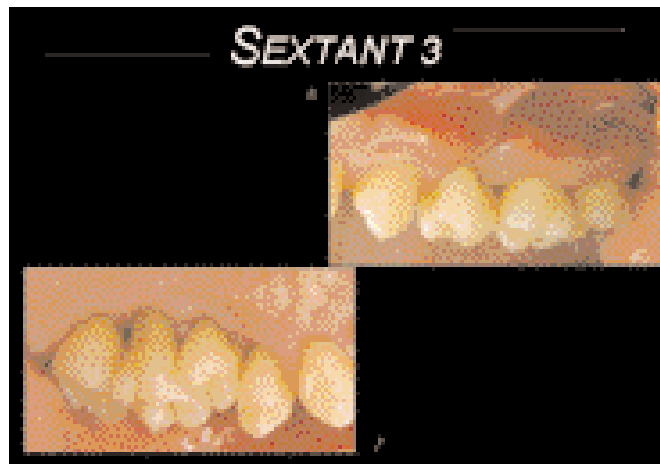
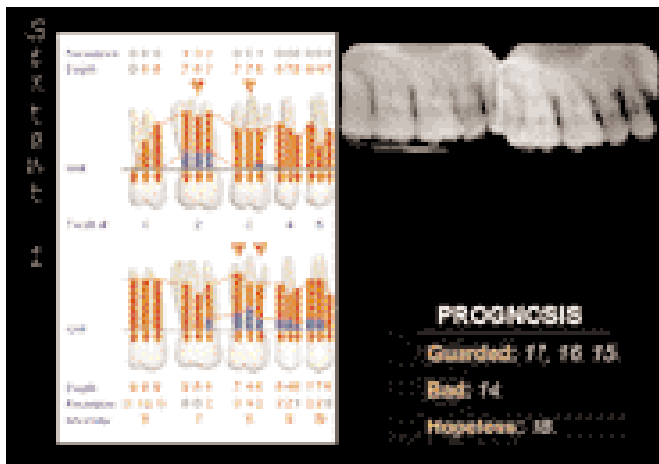
- General: bad.
- Localized: by sextants.

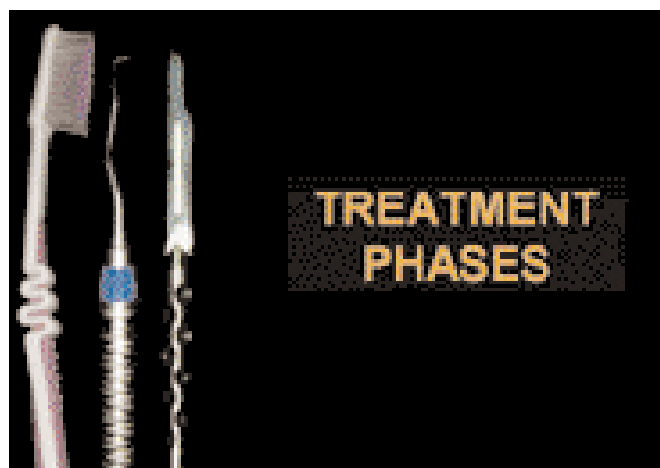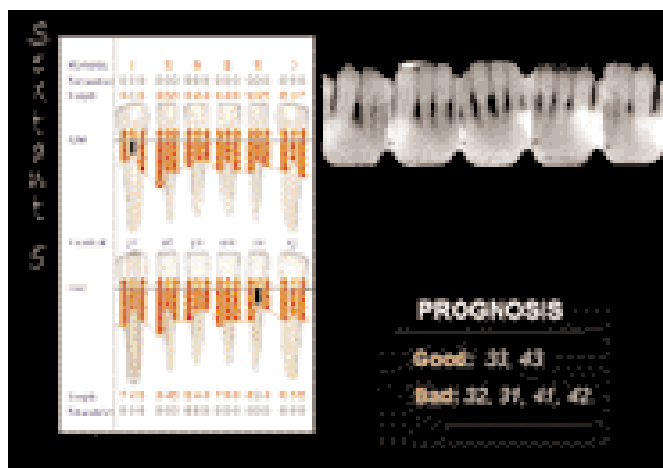
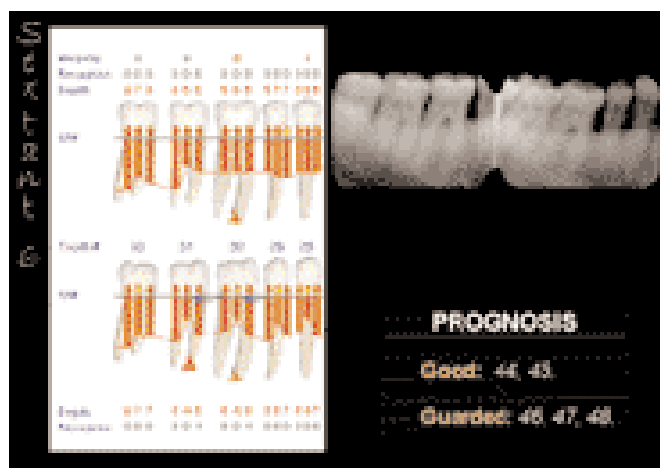
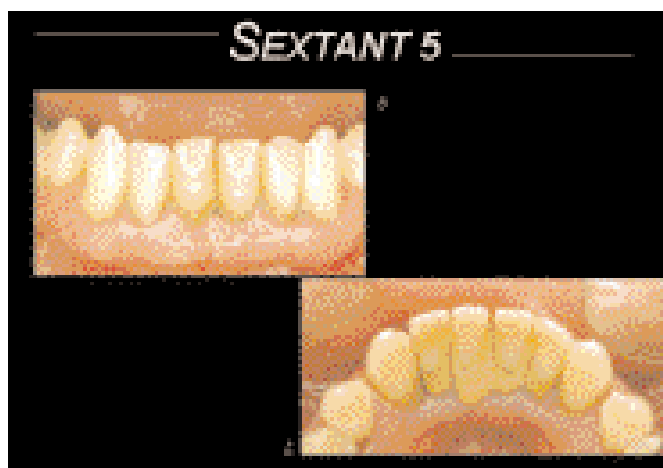
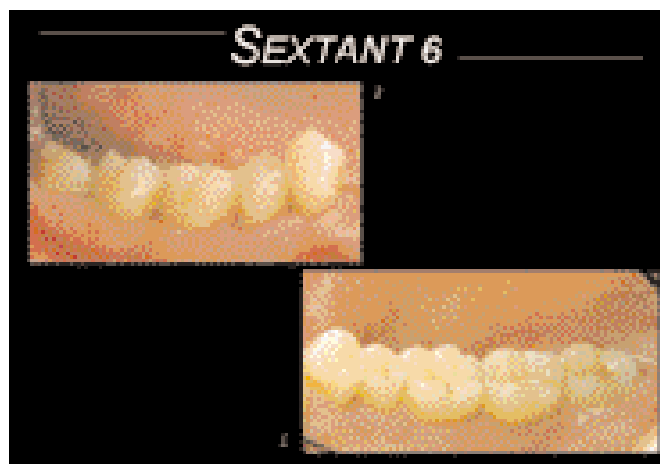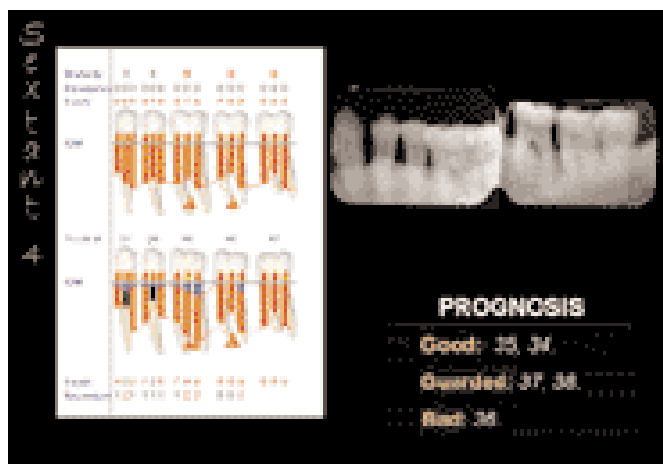
GENERAL DIAGNOSIS

- A.S.A. Classification: Type I.
- International Workshop for a Classification of Periodontal Disease and Conditions 1999:
 - Generalized severe chronic periodontitis
- Orthodontic problems:
 - ✓ Class III skeletal relationship. Good facial balance
 - ✓ Bilateral posterior crossbite.
 - ✓ Teeth malpositions. Diastemas.
 - ✓ Irregular plane of occlusion.

SEXTANT 1







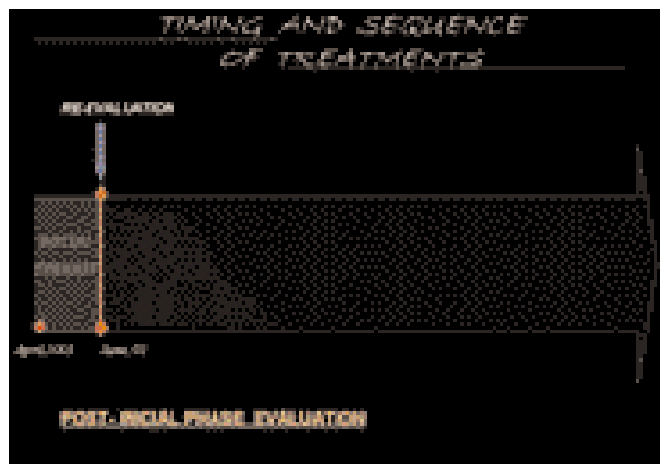
I. INITIAL THERAPY

- Case presentation.

Good prognosis:	11, 21, 34, 35, 31, 41, 44, 45.
Guarded prognosis:	17, 16, 15, 17, 38, 46, 47, 48.
Bad prognosis:	14, 21, 22, 26, 27, 36, 32, 31, 41, 42.
Hopeless prognosis:	13, 12, 24, 25.

Alternative 1

Alternative 2

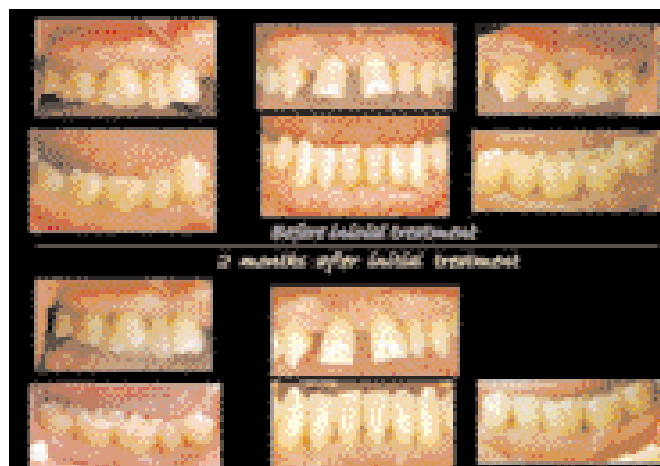


Alternative 1

Alternative 2

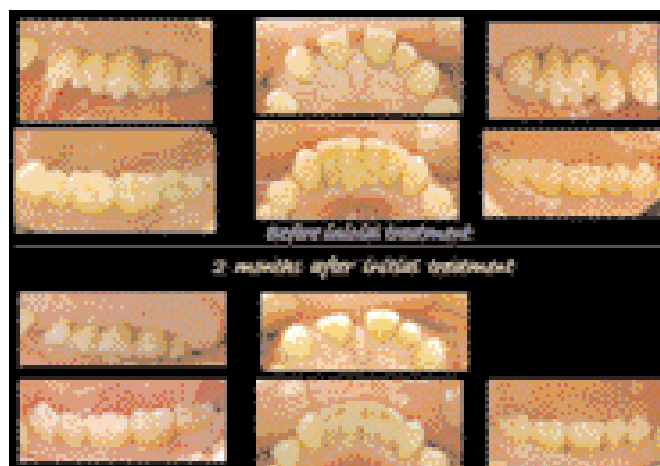
Positive and realistic


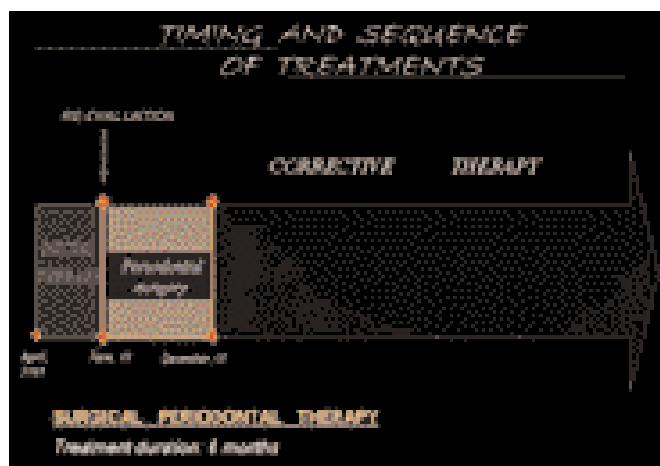


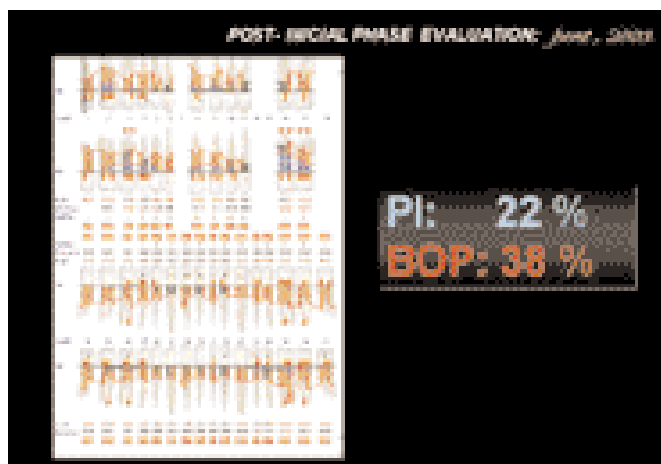
INITIAL THERAPY



I. INITIAL THERAPY

- Case presentation.
- Extraction of 24, 25.
- Instruction in oral hygiene measures.
- Scaling and root planing by quadrants.
- Splinting of sextant 5.
- Occlusal adjustment: *forcus eliminatio*.





2. CORRECTIVE THERAPY
- Periodontal surgery:**
- Sextant 1: Apically repositioned flap.
 - Sextant 3: Apically repositioned flap.
 - Sextant 5: Apically repositioned flap.
 - Sextant 4: Regenerative surgery.

