

0.035 in hydrophilic guidewire while mounted on a Judkins right or mammary artery specific curve coronary catheter. Once the catheter has been advanced through the left atrium, the hydrophilic guidewire is exchanged for a high-support 260 cm 0.035 in guidewire on which a release system of a proper caliber with respect to the device selected is advanced.

The procedure can be performed without general anesthesia and with sedation only since transesophageal ultrasound is not required. However, it is important to have a good previous radiographic study where the CCTA plays an important role.

Selective angiographies of the VV even with the possibility of temporarily occluding the LUPV with an Amplatzer type of balloon to prevent rapid contrast washout allow us to choose the right device for proper anchoring purposes (with certain compression) avoiding embolization. For its special design and multiple sizes available the Amplatzer Vascular Plug-II device (Abbott, United States) would be my first option. An alternative to it would be the Amplatzer Duct Occluder (ADO)-I device whose design also makes it suitable for different anatomies.

Follow-up after the procedure should include an echocardiogram at 3-6 months to assess the reverse remodeling of right cavities and pulmonary systolic pressure. Performing a thoracic CCTA at 6 months is advised to confirm the complete occlusion of the shunt, and the correct position of the device into the VV.

FUNDING

None whatsoever.

CONFLICTS OF INTEREST

None reported.

REFERENCES

1. Alsoufi B, Cai S, Van Arsdell GS, Williams WG, Caldarone CA, Coles JG. Outcomes after surgical treatment of children with partial anomalous pulmonary venous connection. *Ann Thorac Surg.* 2007;84:2020-2026.
2. Baumgartner H, De Backer J, Babu-Narayan SV, Budts W, Chessa M, Diller GP, et al. ESC Scientific Document Group. 2020 ESC Guidelines for the management of adult congenital heart disease. *Eur Heart J.* 2021;42:563-645.
3. Al-Muhaya MA, Alkodami AA, Khoshhal S, Najjar AHA, Al-Mutairi M, Abdelrehim AR. Transcatheter occlusion of the vertical vein in a partial anomalous pulmonary venous connection with dual drainage, case series with literature review. *Int J Cardiol Heart Vasc.* 2021;37:100889.

<https://doi.org/10.24875/RECICE.M22000299>

Percutaneous treatment of partial anomalous pulmonary venous connection with dual drainage. Case resolution



Tratamiento percutáneo de un drenaje venoso pulmonar anómalo parcial con drenaje dual. Resolución

Rafael González-Manzanares,^{a,*} Soledad Ojeda,^a Guisela Flores-Vergara,^a Javier Suárez De Lezo,^a Simona Espejo,^b and Manuel Pan^a

^a Unidad de Cardiología, Hospital Universitario Reina Sofía, Instituto Maimónides de Investigación Biomédica de Córdoba (IMIBIC), Universidad de Córdoba, Córdoba, Spain

^b Unidad de Radiología, Hospital Universitario Reina Sofía, Instituto Maimónides de Investigación Biomédica de Córdoba (IMIBIC), Universidad de Córdoba, Córdoba, Spain

SEE RELATED CONTENT:

<https://doi.org/10.24875/RECICE.M22000297>

<https://doi.org/10.24875/RECICE.M22000298>

* **Corresponding author:** Servicio de Cardiología, Hospital Universitario Reina Sofía, Avda. Menéndez Pidal s/n, 14004 Córdoba, Spain.
E-mail address: rafaelglezm@gmail.com (R. González-Manzanares).

Online 2 September 2022.

2604-7322 / © 2022 Sociedad Española de Cardiología. Published by Permanyer Publications. This is an open access journal under the CC BY-NC-ND 4.0 license.

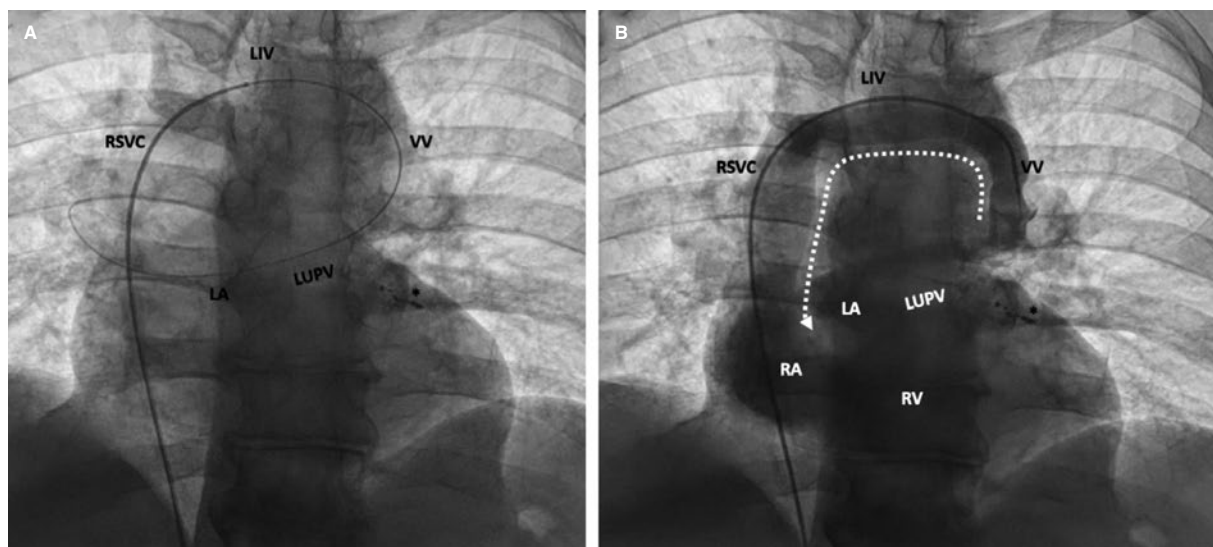


Figure 1. Fluoroscopic image showing the wire pathway from the femoral vein into the left atrium through the right atrium, right superior vena cava (RSVC), left innominate vein (LIV), vertical vein (VV), and left upper pulmonary vein (LUPV) (A); angiogram shows the caudocranial contrast flow from the VV into the LIV, and contrast filling of both the RSVC and the right chambers (B). LA, left atrium; RA, right atrium, RV, right ventricle. Coils used in the previous coronary procedure to treat diagonal branch perforation (*).

CASE RESOLUTION

The heart team decision was to percutaneously treat both the coronary artery disease and the partial anomalous pulmonary venous connection (PAPVC). Percutaneous coronary intervention was successfully performed in the first place. Treatment of the PAPVC was performed 3 months later. Since it is recommended that the diameter of the device should be 30% to 50% larger than the vessel diameter, a 22 mm Amplatzer Vascular Plug II device (AVP-II) (Abbott, United States) was selected based on the VV computed tomography measurements.

The procedure was performed under local anesthesia and with fluoroscopic control. A 7-Fr introducer sheath was inserted into the right femoral vein. A 6-Fr multipurpose diagnostic catheter was advanced using a 0.035 in exchange guidewire to reach the VV through the left innominate vein (figure 1A). Angiography confirmed the presence of a left upper pulmonary vein (LUPV) with dual drainage and significant contrast flow from the LUPV to the innominate vein that filled the right chambers (left-to-right shunt) (figure 1, video 1 of the supplementary data). Using a femoral 7-Fr 90 cm Destination Guiding Sheath (Terumo, United States) the AVP-II device was placed and delivered into the VV (figure 2A, video 2 of the supplementary data). The correct position, absence of residual shunt, patency of innominate vein, and LUPV flow were confirmed by angiography in both the innominate vein (figure 2B,C) and pulmonary artery (figure 2D).

Two days later a control computed tomography (figure 3) and a transthoracic echocardiography with microbubble contrast agent were performed. They confirmed the correct position of the AVP-II device, and the lack of pulmonary infarction. At 7-month follow-up the patient remained asymptomatic and cardiac catheterization showed similar successful fluoroscopic findings (videos 3 and 4 of the supplementary data), and significantly improved pulmonary pressures (figure 4).

The differential diagnosis of a LUPV with dual drainage should include other left-side vascular structures such as persistent left superior vena cava, which is the most common thoracic venous anomaly and, in most cases, drains into the right atrium. However, it may be connected to the left atrium (LA) through a pulmonary vein. In this scenario the expected direction of blood flow is craniocaudal.¹

The treatment of PAPVC is indicated with symptoms attributed to significant left-to-right shunt. Shunting is mainly determined by the number and size of anomalous pulmonary veins. In our case, we hypothesize that the dual LUPV connection and the coexistence of an increased LA pressure due to left ventricular dysfunction contributed to a disproportionate shunt for a single anomalous pulmonary vein. This eventually led to right chambers dilatation and symptomatic combined post- and pre-capillary pulmonary hypertension.

Although surgery is the treatment of choice, percutaneous treatment may be a feasible alternative in patients with a pulmonary vein dually draining into a left innominate vein and the LA² since the sealing of the VV with a vascular device redirects all pulmonary vein blood flow into the LA. Before sealing, transient balloon occlusion should be considered to assess LA and pulmonary pressure changes. If pressure increases, sealing should be reconsidered and if performed, LA decompression with an atrial flow regulator should follow.³

FUNDING

None whatsoever.

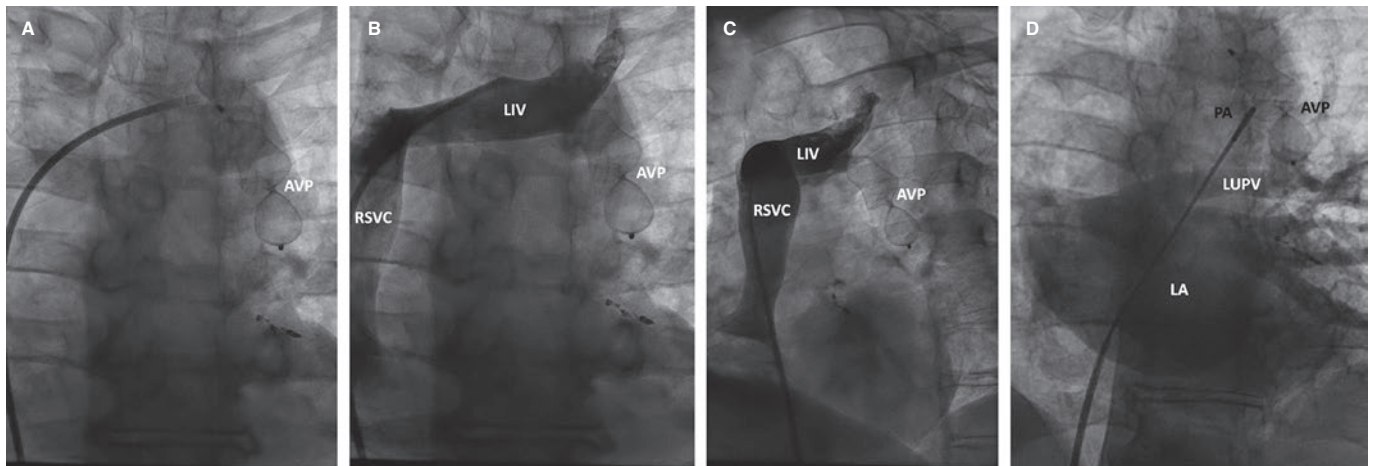


Figure 2. Fluoroscopic image showing the Amplatzer Vascular Plug II device (AVP II) delivery using the Guiding Sheath (A). The angiograms reveal the correct position of the AVP II device, and the patency of the left innominate vein (LIV) flow: posterior-anterior (B) and left anterior oblique (C) views. Contrast injection into the pulmonary artery using a pigtail catheter with left atrium (LA) filling revealing the proper inferior position of the AVP II device, proper flow through the left upper pulmonary vein (LUPV), and lack of caudocranial flow through the occluded vertical vein (D). PA, pulmonary artery; RSVC, right superior vena cava.

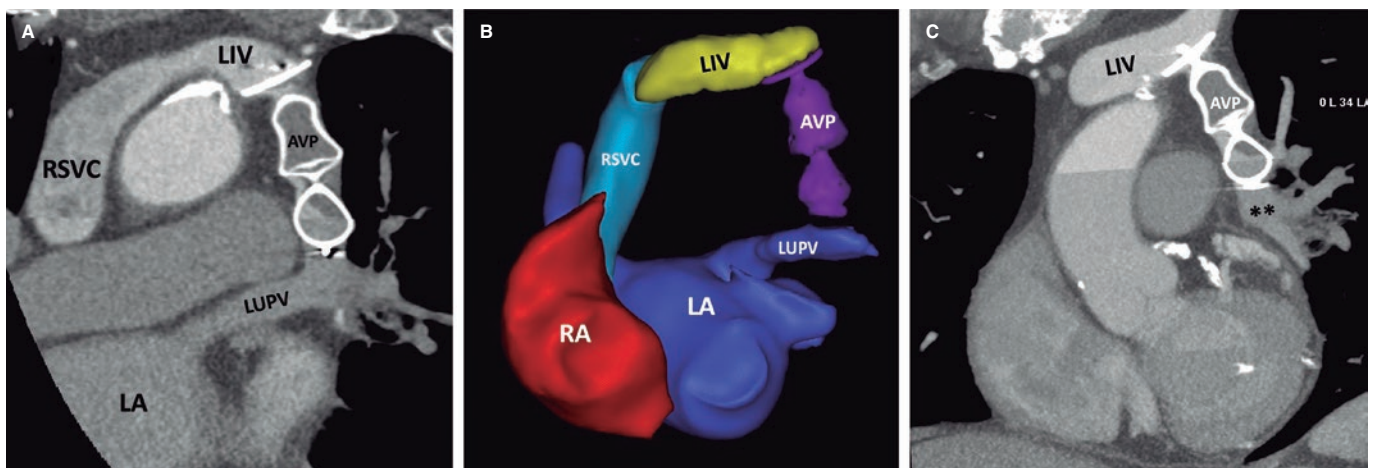


Figure 3. Postoperative thoracic computed tomography. Multiplanar reformatted (A,C), and 3D reconstructed (B) images show the proper position of the Amplatzer Vascular Plug II device (AVP II) occluding the vertical vein that previously connected the left innominate vein (LIV) and the left upper pulmonary vein (LUPV). LA, left atrium; RA, right atrium; RSVC, right superior vena cava.

AUTHORS' CONTRIBUTIONS

R. González-Manzanares and G. Flores-Vergara drafted the manuscript and completed its critical revisions. S. Ojeda, J. Suárez de Lezo, S. Espejo, and M. Pan reviewed and revised the manuscript and approved its final version before submission. All authors gave their final approval to the version that would eventually be published.

CONFLICTS OF INTEREST

S. Ojeda is an associate editor of *REC: Interventional Cardiology*. The journal's editorial procedure to ensure impartial handling of the manuscript has been followed. The remaining authors declared no conflicts of interest associated with this article.

SUPPLEMENTARY DATA



Supplementary data associated with this article can be found in the online version available at <https://doi.org/10.24875/RECICE.M22000299>.

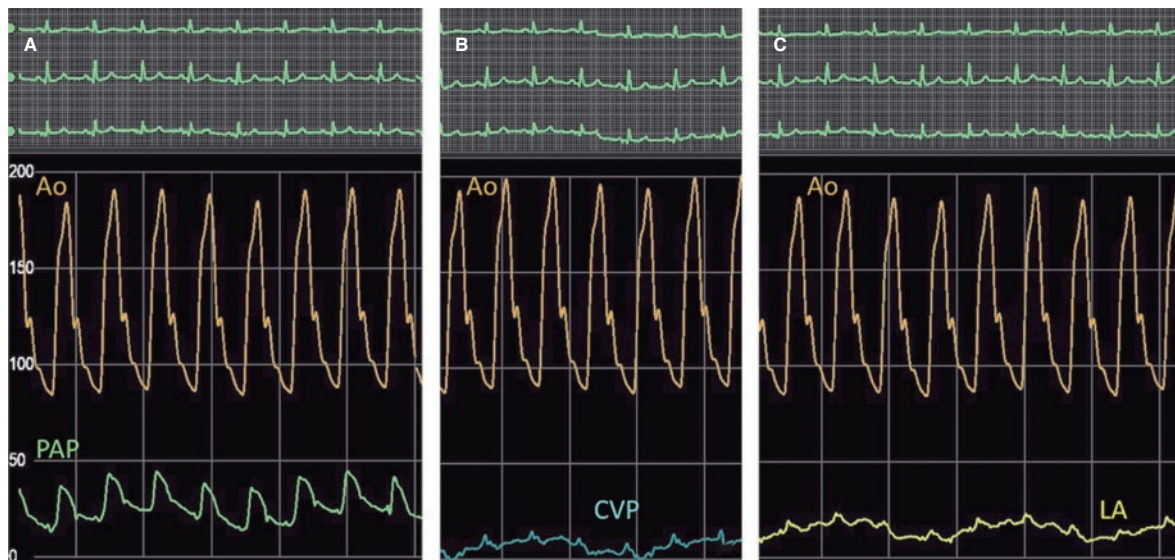


Figure 4. Follow-up hemodynamic measurements showing decreased pulmonary artery pressure (PAP) (**A**) and left atrial (LA) pressure (**C**). Central venous pressure (CVP) is similar to the baseline procedure (**B**). Ao, aorta.

REFERENCES

1. Azizova A, Onder O, Arslan S, et al. Persistent left superior vena cava: clinical importance and differential diagnoses. *Insights Imaging*. 2020;11:110.
2. Mamas MA, Clarke B, Mahadevan VS. Percutaneous treatment of dual pulmonary venous drainage and coarctation of the aorta in a single patient. *Exp Clin Cardiol*. 2010;15:11-13.
3. Pascual-Tejerina V, Sánchez-Recalde Á, Gutiérrez-Larraya F, Ruiz-Cantador J, Rodríguez-Padial L, Zamorano JL. Transcatheter closure of a vertical vein in a patient with total anomalous pulmonary venous drainage decompressing the left atrium with an AFR device. *Rev Esp Cardiol*. 2021;74:990-991.