

Early experience with the FlowTriever thrombectomy system to treat pulmonary embolism



Experiencia inicial de trombectomía con FlowTriever en embolia aguda de pulmón

Pablo Salinas,^{a,*} María-Eugenia Vázquez-Álvarez,^{b,c} Alfonso Jurado-Román,^d Sílvio Leal,^e and Mike Huanca^{b,c}

^a Servicio de Cardiología, Hospital Clínico San Carlos, Instituto de Investigación Sanitaria del Hospital Clínico San Carlos (IdISSC), Madrid, Spain

^b Servicio de Cardiología, Hospital General Universitario Gregorio Marañón, Instituto de Investigación Sanitaria Gregorio Marañón, Madrid, Spain

^c Centro de Investigación Biomédica en Red de Enfermedades Cardiovasculares (CIBERCV), Spain

^d Servicio de Cardiología, Hospital Universitario La Paz, Madrid, Spain

^e Serviço de Cardiologia, Hospital de Santa Cruz/Centro Hospitalar de Lisboa Ocidental, Lisboa, Portugal

To the Editor,

Catheter-directed therapy is indicated in high-risk patients (PE-HR) to treat pulmonary embolism (PE) when systemic thrombolysis is contraindicated or has failed (indication IIA, C). Also, as a bailout therapy in intermediate/high-risk patients (PE-IHR) with hemodynamic impairment as an alternative to systemic thrombolysis (indication IIA, C).¹ However, clinical practice guidelines do not specify which is the optimal catheter-directed therapy that should be used. It can be local thrombolysis that consists of the direct infusion of variable doses (around 20% of systemic dose) of thrombolytic drugs (alteplase or tenecteplase) into the pulmonary artery (intra-thrombus) or else mechanical thrombectomy with direct aspiration catheter that consists of thrombus extraction (with or without previous fragmentation). Finally, a mechanical-pharmacological strategy with both techniques combined can be used sequentially.²

This is the early experience of mechanical thrombectomy with direct aspiration using the FlowTriever retrieval/aspiration system (Inari, United States) of 4 Spanish and Portuguese centers. The Hospital Clínico San Carlos ethics committee approved the registry and obtained the participants' written informed consent. The FlowTriever is a 24-Fr thrombus aspiration system with an oversized tube and accessories to optimize thrombus extraction.^{3,4} These are 3 cases of PE-HR with contraindication for systemic thrombolysis and 7 cases of PE-IHR treated at centers experienced in catheter-directed therapy, but not with this specific device, whose distribution in these countries started back in 2022. Clinical and procedural characteristics are shown on [table 1](#). Procedure was performed on a mean of 25.7 ± 23 hours since diagnosis. Procedures were successful in 100% of the cases (defined as catheter navigation towards the pulmonary artery with extraction of thrombotic material and no procedural deaths or complications reported) with obtention of abundant thrombus as shown on [figure 1](#). Drug therapy consisted of low molecular weight heparin in 4/10 cases, sodium heparin in 4/10 cases, and no anticoagulation in 2. Fibrinolytic agents were not used in any patients. Access route was femoral in all the cases (24-Fr) with vascular closure in 4/10 (1 Perclose Proglide Abbott Vascular device, United States), figure-of-eight suture in 4/10, and manual compression in 2/10. No vascular access

Table 1. Clinical and procedural data

Preoperative clinical data (N = 10)		
Age	57.3 ± 16.1	
Woman	60%	
Past medical history of VTED	30%	
Elevated troponin levels	100%	
Venous lactate at admission (mmol/L)	3.01 ± 1.9	
Inotropic support	60%	
Ultrasound and hemodynamic parameters		
	Pre-CDT	Post-CDT
RV/LV ratio > 0.9	100%	20%
TAPSE	12.6 ± 3.5	19 ± 34
Systemic systolic pressure	107 ± 24	138 ± 23
Heart rate (bpm)	114 ± 16	95 ± 11
Pulmonary systolic pressure (mmHg)	51 ± 8	37 ± 12
Other procedural data		
Contrast (mL)	156 ± 77	
Aspirated volume (mL)	396 ± 167	
Procedural time (min)	126 ± 52	

CDT, catheter-directed therapy; LV, left ventricle; RV, right ventricle; TAPSE, tricuspid annular plane systolic excursion; VTED, venous thromboembolic disease.

complications were reported. Hemodynamic parameters improved after the procedure as shown on [table 1](#). The volume of blood drawn is significant, and 2/3 of the patients from the PE-HR group required transfusion during admission. Probably after the learning curve the volume should be smaller (in the FLASH cohort, the mean volume was 255 mL.⁴) Additionally, the FlowTriever system has a

* Corresponding author.

E-mail address: salinas.pablo@gmail.com (P. Salinas).

Online 13 January 2023.

2604-7322 / © 2022 Sociedad Española de Cardiología. Published by Permanyer Publications. This is an open access journal under the CC BY-NC-ND 4.0 license.

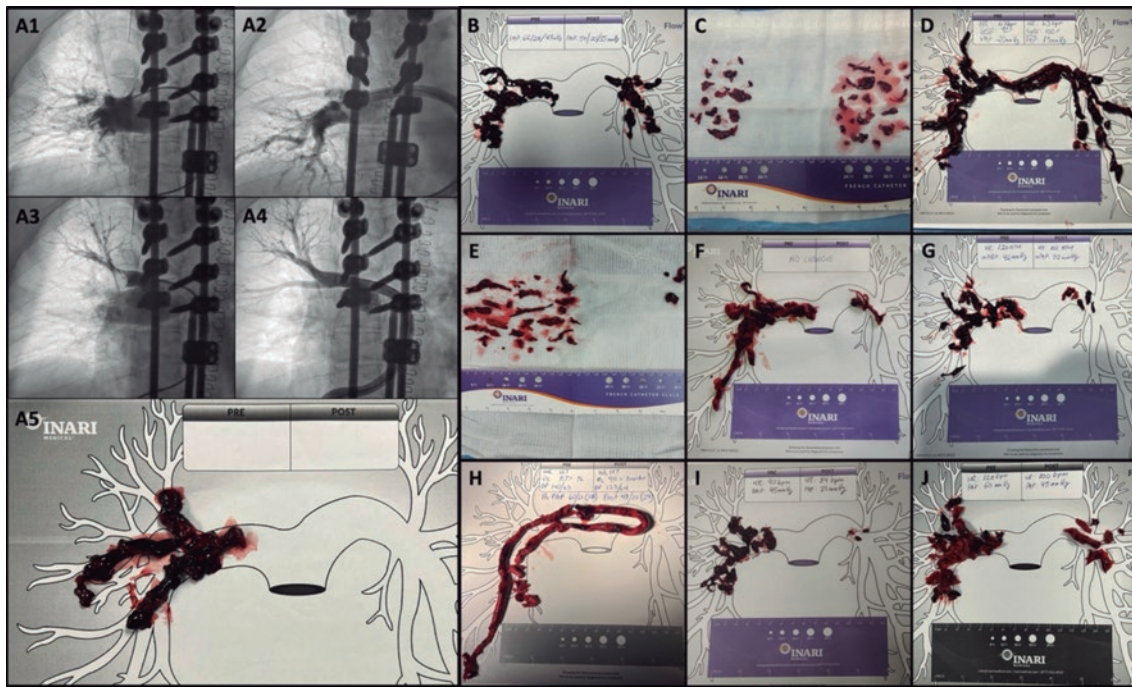


Figure 1. A: case #1 from Hospital General Universitario Gregorio Marañón. Sub-selective angiographies before (A1/A3) and after (A2/A3) the catheter-directed therapy, and material obtained (A5). B to D: material obtained in the cases from Hospital General Universitario Gregorio Marañón. E and F: cases from Hospital Clínico San Carlos. G and H: cases from Hospital La Paz. I and J: cases from Centro Hospitalar de Lisboa Ocidental.

filter capable of returning most of the aspirated blood— thrombus-free—back to the patient. However, this version is still not available in Europe.

The composite endpoint of major adverse events used in large registries consists of device-related death, major bleeding (Bleeding Academic Research Consortium type ≥ 3 b) or procedure or device-related adverse events.⁴ In our case series 1 major adverse event in 1 procedure was reported: a stroke within the first 24 hours after the procedure due to paradoxical embolism. The presence of patent foramen ovale was confirmed during the procedure due to the crossing of the guidewire towards the left atrium. It is not possible to determine whether the embolism could have been triggered by the manipulation with the guidewire inside the atrium or whether it could have happened spontaneously. The patient recovered and was discharged 9 days after the procedure. Among the cases of PE-HR, 1 patient improved rapidly, and a second one remained in shock with distributive component in the immediate postoperative setting (< 24 h) and improved late with hospital discharge. The third one was admitted after an out-of-hospital cardiac arrest and died due to post-anoxic encephalopathy (the only case of in-hospital death considered unrelated to the procedure). Therefore, mortality 1/3 in the PE-HR and PE-IHR groups was 1/3 and 0/7, respectively. No additional adverse events or readmissions have been reported at 30-day follow-up in any of the patients.

Early diagnosis, risk stratification, and knowledge of these invasive therapies performed by interventional radiologists or cardiologists can contribute to improving the patients' prognoses. Coordination from response teams to PE to optimize workflow and the decision-making process is of paramount importance.¹ Reproducibility, efficacy and, safety are always sought at the dawn of interventional techniques. In a meta-analysis of ultrasound-facilitated local thrombolysis of 2135 patients, efficacy was described as reduced radiographic thrombus loads and ventricular diameters

with rates of major bleeding > 5.4%.⁵ In contemporary studies on mechanical thrombectomy with aspiration with specific devices, a similar efficacy has been described. However, the rates of major bleeding are lower: 1.7% with the Indigo system (Penumbra, United States) in 119 patients,⁶ and 1.2% with the FlowTrieve system (Inari, Estados United States) in 250 patients.⁴ Therefore, since comparative studies like the PEERLESS trial (NCT05111613) are lacking, mechanical thrombectomy with aspiration seems to offer similar results with a lower bleeding risk. Our early experience with the device confirms that the proper description of the technique and proctoring training during the case can shorten the learning curve significantly. In this early experience, we managed to replicate the results of efficacy and safety previously reported with this promising device for the interventional management of PE.

FUNDING

None whatsoever.

AUTHORS' CONTRIBUTIONS

P. Salinas: study idea, supervision, investigation, formal analysis, and drafting of the original manuscript. M.E. Vázquez-Álvarez: investigation, data management, review, and edition of the manuscript. A. Jurado-Román: investigation, data management, review, and edition of the manuscript. S. Leal: investigation, data management, review, and edition of the manuscript. M. Huanca: investigation, data management, review, and edition of the manuscript.

CONFLICTS OF INTEREST

None reported.

REFERENCES

1. Konstantinides SV, Meyer G, Becattini C, et al. 2019 ESC Guidelines for the diagnosis and management of acute pulmonary embolism developed in collaboration with the European Respiratory Society (ERS): The Task Force for the diagnosis and management of acute pulmonary embolism of the European Society of Cardiology (ESC). *Eur Heart J*. 2020;41:543-603.
2. Salinas P. A debate: Terapia farmacológica o invasiva en la tromboembolia pulmonar aguda. Perspectiva del intervencionista. *REC Interv Cardiol*. 2022; 4:240-242.
3. Salinas P, Real C, Fernández-Ortiz A. Tromboaspiración con sistema FlowTriever en embolia pulmonar aguda. *Med Clin*. 2022;159:154.
4. Toma C, Bunte MC, Cho KH, et al. Percutaneous mechanical thrombectomy in a real-world pulmonary embolism population: Interim results of the FLASH registry. *Catheter Cardiovasc Interv*. 2022;99:1345-1355.
5. Pei DT, Liu J, Yaqoob M, et al. Meta-Analysis of Catheter Directed Ultrasound-Assisted Thrombolysis in Pulmonary Embolism. *Am J Cardiol*. 2019; 124:1470-1477.
6. Sista AK, Horowitz JM, Tapson VF, et al. Indigo Aspiration System for Treatment of Pulmonary Embolism: Results of the EXTRACT-PE Trial. *JACC Cardiovasc Interv*. 2021;14:319-329.

<https://doi.org/10.24875/RECICE.M22000355>

First experience in Spain with PiCSO therapy in patients with acute myocardial infarction



Primera experiencia en España con el sistema PiCSO en pacientes con infarto agudo de miocardio

Pablo Vidal-Calés,^a Omar Abdul-Jawad Altisent,^a Francesco Spione,^{a,b} Víctor Arévalos,^a Manel Sabaté,^a and Salvatore Brugaletta^{a,*}

^a Departamento de Cardiología Intervencionista, Hospital Clínic de Barcelona, Instituto Clínico Cardiovascular, Institut d'Investigacions Biomèdiques August Pi i Sunyer, Barcelona, Spain

^b Department of Advanced Biomedical Sciences, University of Naples Federico II, Naples, Italy

To the Editor,

Myocardial infarction is the leading cause of morbidity and mortality in our setting. Percutaneous coronary intervention has improved the prognosis of patients with ST-segment elevation myocardial infarction (STEMI).¹ However, there is a subgroup of patients who suffer from suboptimal myocardial reperfusion with appearance of myocardial fibrosis, ventricular dysfunction, and development of heart failure.²

Recently, several pharmaceutical and procedural strategies have been developed to improve these results.³ The PiCSO system (Pressure-controlled intermittent coronary sinus occlusion) developed by Miracor Medical SA, Belgium consists of a balloon catheter to occlude the coronary sinus periodically:

- 1) During the occlusion stage (5 to 15 s), venous flow is redistributed from well perfused areas towards ischemic regions through the formation of collateral circulation. Also, through an increased venous systolic pressure, the plasma skimming phenomenon allows better perfusion of venules with oxygen-and-metabolite-rich plasma.
- 2) During the release stage (3 to 4 s) the dramatic drop of venous pressure creates a gradient that ends up clearing all thrombotic debris, toxic metabolites, and myocardial edema.

- 3) These pressure variations can induce mechanotransduction by activating vascular cells and releasing growth factors, vasodilator substances, and microRNA into microcirculation (figure 1).

The PiCSO system has proven capable of improving microvascular function and reducing the infarction size in non-randomized clinical trials of patients with high-risk anterior STEMI.⁴ As a matter of fact, it was granted the CE marking in 2020 with a clinical indication for the management of anterior STEMI with < 12-hour evolution and early TIMI grade 0-1 flow (Thrombolysis in Myocardial Infarction) and culprit lesion in the proximal or middle segments of the left anterior descending coronary artery. We wish to use this scientific letter to share our experience with this novel device in 2 case reports. The patients' informed consent was obtained, and the study was approved by the ethics committee according to the principles set forth in the Declaration of Helsinki.

The first case is a 83-year-old man without a past medical history of interest with thoracic pain and anterior ST-segment elevation of 3 mm in V1-V4 on the electrocardiogram. The coronary angiography revealed the presence of an acute thrombotic occlusion in the proximal segment of the left anterior descending coronary artery with early TIMI grade-0 flow (figure 2A). Thrombus aspiration and drug-eluting stent implantation led to TIMI grade-3 flow after 115 min of total ischemia (figure 2B). Since this was a large anterior STEMI

* Corresponding author.

E-mail address: sbrugaletta@gmail.com (S. Brugaletta).

[@sbrugaletta](https://twitter.com/sbrugaletta)

Online 13 January 2023.

2604-7322 / © 2022 Sociedad Española de Cardiología. Published by Permanyer Publications. This is an open access journal under the CC BY-NC-ND 4.0 license.