



# Transcatheter aortic valve implantation using FEops HEARTguide co-registration

## Implante percutáneo de válvula aórtica mediante corregristo FEops HEARTguide

Pablo J. Antúnez-Muiños,<sup>a,b,\*</sup> Sergio López-Tejero,<sup>a,b</sup> Jesús Herrero Garibi,<sup>a,b</sup> Elena Díaz Peláez,<sup>a,b,c</sup> Pedro Luis Sánchez Fernández,<sup>a,b,c</sup> and Ignacio Cruz-González,<sup>a,b,c</sup>

<sup>a</sup> Servicio de Cardiología, Hospital Universitario de Salamanca, Salamanca, Spain

<sup>b</sup> Instituto de Investigación Biomédica de Salamanca (IBSAL), Salamanca, Spain

<sup>c</sup> Centro de Investigación Biomédica en Red de Enfermedades Cardiovasculares (CIBERCV), Spain

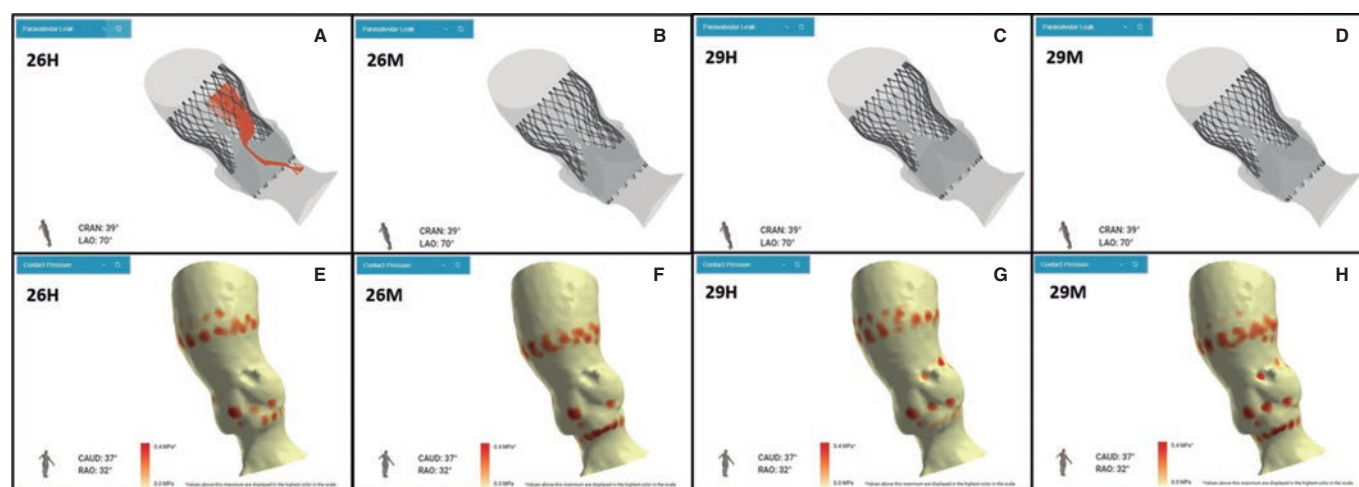


Figure 1.

Transcatheter aortic valve implantation (TAVI) success rate is very high and has a low rate of complications. Therefore, the number of TAVIs has been increasing worldwide. However, complications such as paravalvular leak (PVL) or permanent pacemaker implantation (PPMI) need still to be resolved, particularly in younger patients.

At this point, new technologies may help solve these problems. The FEops HEARTguide is a software that simulates the interaction between the device and patient's anatomy (figure 1A,B). FEops provides the operator with different options and device sizes in a higher or deeper position (EVOLUT no. 26 and no. 29, Medtronic, United States), predicts the theoretical membranous septum, and the device contact pressure by analyzing the tissue characteristics of patient's anatomy in the computed tomography (CT) images or risk of residual PVL or PPMI (figure 1C-H). Therefore, preoperative planning with FEops can be used to choose the most suitable size and device position for each patient.

On the other hand, synchronized co-registration CT-fluoro has proven useful during TAVI. This is the first case ever performed worldwide using FEops image co-registration with live fluoroscopy in a TAVI procedure (figure 2, video 1 of the supplementary data; red circle: marks the membranous septum). However, no live correlation with heart and lung movements is its main limitation.

In conclusion, FEops is potentially useful in TAVI not only for preoperative planning but also co-registration with fluoroscopy imaging during the procedure may reduce the complications associated with TAVI, especially in complex anatomies. Also, it can reduce the contrast used and the learning curve regarding difficult anatomies.

Written and oral informed consent were obtained before performing the procedure and for publication purposes.

\* Corresponding author.

E-mail address: [pjantunez@gmail.com](mailto:pjantunez@gmail.com) (P.J. Antúnez-Muiños).

[@pjantunez](https://twitter.com/pjantunez)

Received 18 August 2022. Accepted 10 October 2022. Online 7 December 2022.

2604-7322 / © 2022 Sociedad Española de Cardiología. Published by Permanyer Publications. This is an open access journal under the CC BY-NC-ND 4.0 license.

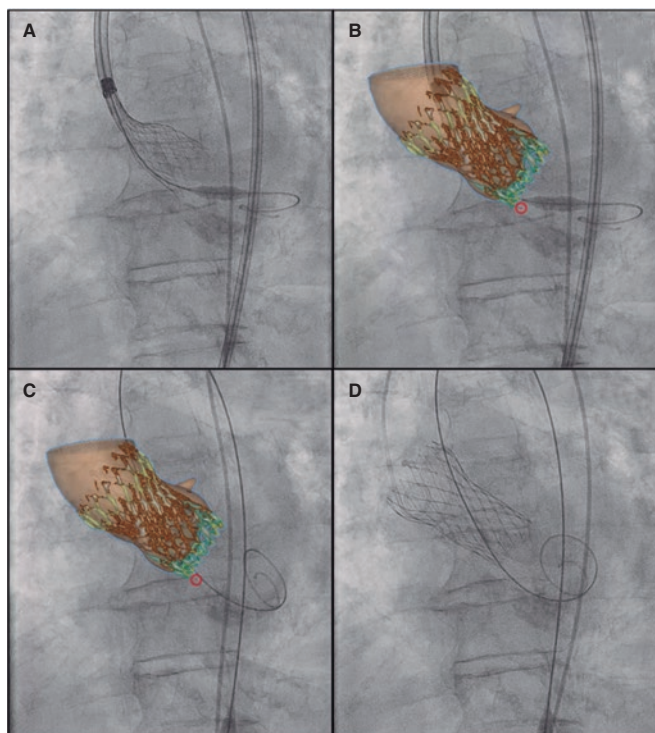


Figure 2.

#### FUNDING

None whatsoever.

#### AUTHORS' CONTRIBUTIONS

All the authors participated in this manuscript, reviewed, and fully agreed on its content.

#### CONFLICTS OF INTEREST

I. Cruz Gonzalez is a proctor and consultant for Medtronic.

#### SUPPLEMENTARY DATA



Supplementary data associated with this article can be found in the online version available at <https://doi.org/10.24875/RECICE.M22000349>.