

Torregrosa Suau O¹, Guilló Quiles E², Mora Rufete A³

1 Unidad de Metabolismo Óseo, Servicio de Medicina Interna

2 Medicina Familiar y Comunitaria, Departamento de Salud Elche

3 Servicio de Medicina Interna

Hospital General Universitario de Elche, Elche, Alicante (España)

Mesenteric panniculitis associated with the use of bisphosphonates: are these more proinflammatory than we know?

DOI: <http://dx.doi.org/10.4321/S1889-836X2017000100006>

Correspondence: Óscar Torregrosa Suau - Hospital General Universitario de Elche - Camino de la Almazara, s/n - 03203 Elche - Alicante (Spain)

e-mail: oscartorregrosa@msn.com

Date of receipt: 07/11/2016

Date of acceptance: 13/12/2016

Summary

Mesenteric panniculitis is characterized by chronic inflammation of the adipose tissue of the intestinal mesentery, and its etiology is unknown. It has been associated with malignancy, vasculitis, rheumatic diseases and the use of certain drugs. We present a case of panniculitis associated with bisphosphonate use, not previously described in the literature, thus suggesting its potential secondary proinflammatory effects.

Key words: *mesenteric panniculitis, bisphosphonates, proinflammatory.*

Introduction

Mesenteric panniculitis is a rare disorder characterized by chronic nonspecific inflammation of adipose tissue of the intestinal mesentery of unknown origin¹. It may develop independently or in association with other alterations, which has been the subject of much discussion. It has been linked to various conditions, such as vasculitis, granulomatous diseases, rheumatic diseases, malignant diseases, pancreatitis², smoking and the use of certain drugs (beta blockers, methyl dopa, sulfonamides, salicylates and oral contraceptives).

This entity has been found to present several stages of development. It is classified into different types depending on the radiological characteristics: type I (42%), diffuse thickening of the mesentery from root to the edges of the small intestine; Type II (32%), isolated nodular mass in mesenteric root; Type III (20%), the mesentery contains multiple nodules which vary in size³. Diagnostic anatomopathological criteria include: presence of large quantities of foamy macrophages in the initial phase of mesenteric lipodystrophy; Infiltrated plasma cells, giant foreign body cells, and foamy macrophages in mesenteric panniculitis. In the final stage, the deposition of collagen and the fibrosis in the tissues are noteworthy⁴.

Although different factors have been recognized that may trigger the disease, its origin in certain cases remains uncertain. Once diagnosed, there is no specific treatment. Corticosteroids are recommended, although cases of spontaneous remission have been reported. Surgical resection is considered for cases in which there is intestinal obstruction due to inflammation and secondary scarring. Antibiotics, radiation therapy and cyclophosphamide have also been reported as possible responses.

Clinical Case Report

We present the case of a 67-year-old woman, without toxic habits, with no medical history of interest except cervico-artrosis and spondylolisthesis in rehabilitation and postmenopausal osteoporosis for 3 years following bisphosphonate treatment (BF). Mesenteric panniculitis was not justified by other causes.

Our patient, after 3 years of treatment with risedronate, began to present diffuse abdominal pain on a global basis, not related to meals and with episodes of frequent exacerbations over a period of about 2-3 months.

In one of the exacerbations, the patient was admitted and an abdominal computed tomography (CT) carried out, among other tests. In the CT, mesenteric panniculitis was revealed (Figure 1).

After reasonably ruling out other clinical etiologies of mesenteric panniculitis (Table 1)⁵, the BFs that were taken and reevaluated at 6 months with a new abdominal control CT was taken, showing a complete resolution of the abdominal inflammatory lesions which presented in the previous CT scan (Figure 2).

Discussion

There are no similar cases described in the literature, nor have we found clinical trials of bisphosphonates, FIT, VERT, BONE, HORIZON⁶⁻⁹, in cases of mesenteric panniculitis, although its use has been associated with other inflammatory processes. Cases of ocular side effects have been reported in this group of mostly inflammatory drugs such as uveitis, scleritis and conjunctivitis¹⁰. Conjunctivitis is the most frequent adverse ocular condition, although its actual incidence is very low. In general, it responds quickly to topical treatment, even if we maintain the drug, although it is more prudent to suspend it, at least temporarily. Another complication, less frequent but potentially more serious, is uveitis. Its incidence is very low, between 2 and 5 cases per 10,000 patients treated. In general, its location is anterior, although some isolated cases of posterior uveitis have been described. Its occurrence is quite variable, with a median number of days after the start of the 70-day drug (between 1 and 146) and its incidence is higher in patients treated with intravenous BF.

An increase in the susceptibility to uveitis in patients with associated diseases such as spondyloarthropathies, Behçet's syndrome, Wegener's granulomatosis or sarcoidosis and/or treatment with certain drugs has also been observed in which BP will act as a precipitating factor¹¹.

Bisphosphonates are potent inhibitors of osteoclasts by exerting a strong interaction with these cells, resulting in a marked decrease in bone resorption¹².

A number of adverse effects have been reported with bisphosphonate administration, which appear to correspond to "class effects." These effects may vary from bisphosphonates to others depending, among other factors, on the route of administration. Upper gastrointestinal tract such as esophagitis, gastric ulcers and even hemorrhages, musculoskeletal pain, influenza-like manifestations, atrial fibrillation, renal failure, hypocalcemia, maxillary osteonecrosis, atypical femoral fractures and ocular adverse effects such as conjunctivitis, uveitis, iritis, Episcleritis, scleritis or keratitis¹³. There has been no association with alterations of mesenteric panniculitis type adipose tissue in the literature.

Conclusions

Mesenteric panniculitis continues to be a nosological entity which is, in many cases, incidental and controversial. The retrospective analysis of many series has identified possible risk factors and a multitude of etiologic agents. Further studies and more described cases like ours are required to associate the use of BF more strongly with areas of inflammation of mesenteric adipose tissue. Although they have demonstrated their "proinflammatory" effect in other organs, especially at the ocular level, as we have developed previously.

Declaration of interest: The authors declare no conflicts of interest.

Figure 1. Abdominal CT scan showing area of panniculitis at the root of the mesentery

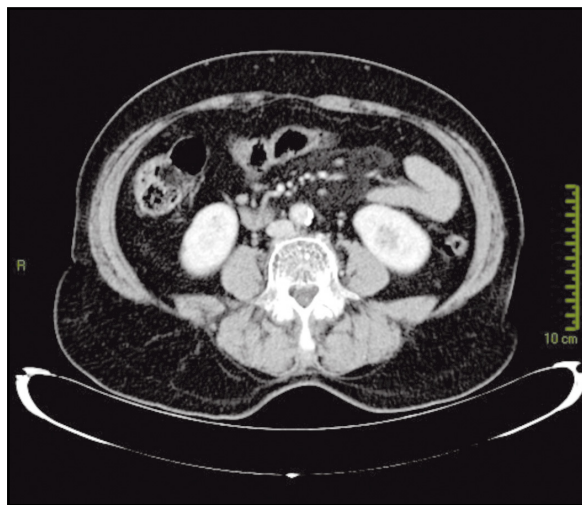

Figure 2. Abdominal CT scan 6 months later. There are no areas of mesenteric panniculitis

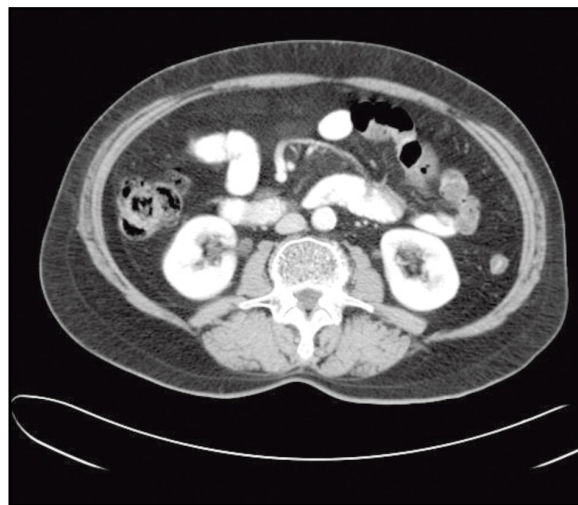


Table 1. Differential diagnosis of mesenteric panniculitis

Carcinoid tumors	Lymphomas
Reaction to adjacent cancer or chronic abscess	Lymphomas
Amyloidosis	Liposarcoma
Desmoid tumors	Peritoneal carcinomatosis
Infectious diseases (tuberculosis and histoplasmosis)	Peritoneal fibrosis
Peritoneal mesothelioma	Histoplasmosis
Lymphosarcomas	Retroperitoneal sarcoma
Chronic foreign body inflammation	Lymphangioma
Whipple's disease	

Bibliography

- Ruiz Tovar J, Alonso Hernández N, Sanjuanbenito A, Martínez E. Panniculitis mesentérica: presentación de 10 casos. *Rev Esp Enferm Dig.* 2007;99:240-7.
- Daskalogiannaki M, Voloudaki A, Prassopoulos P, Magkanas M, Stefanaki K, Apostolaki E, et al. Evaluation of mesenteric panniculitis: prevalence and associated diseases. *Am J Roentgenol.* 2000;174:427-31.
- Colomer E, Blanes A, Carbonell C, Biot A, Villar H, Tomas A. Panniculitis Mesentérica con afectación retroperitoneal resuelta tras tratamiento con pulsos de ciclofosfamida endovenosa. *An Med Intern.* 2003; 20:31-3.
- Delgado Plasencia L, Rodríguez Ballester L, López-Tomassetti Fernández EM, Hernández Morales A, Carillo Pallares A, Hernández Siverio N. Mesenteric panniculitis: experience in our center. *Rev Esp Enferm Dig.* 2007;99:291-7.
- Viscido G, Napolitano D, Rivoira G, Parodi M, Barotto M, Picón H, et al. Panniculitis mesentérica asociada con absceso intraabdominal. *Rev Chilena de Cirugía.* 2008(3):452-6.
- Harris S, Watts N, Genant H. Effects of risedronate treatment on vertebral and nonvertebral fractures in women with postmenopausal osteoporosis: a randomized controlled trial. *JAMA.* 1999;282:1344-52.
- Black D, Thompson D, Bauer D, Ensrud K, Musliner MC, Hochberg MC, et al. Fracture risk reduction with alendronate in women with osteoporosis: the Fracture Intervention Trial. FIT Research Group. *J Clin Endocrinol Metab.* 2000;85:4118-24.
- Chesnut III CH, Skag A, Christiansen C, Recker R, Stakkestad JA, Hioseth A, et al. Effects of oral ibandronate administered daily or intermittently on fracture risk in postmenopausal osteoporosis. *J Bone Miner Res.* 2004;19:1241-9.
- Black DM, Delmas PD, Eastell R, Reid IR, Boonen S, Cauley JA, et al. Once-yearly zoledronic acid for treatment of postmenopausal osteoporosis. *N Engl J Med.* 2007;356:1809-22.
- Cano Parra J, Díaz-Llopis M. Uveitis Inducida por fármacos. *Arch Soc Esp Oftalmol.* 2005;80:1-12.
- Arbolea L, Alperi M, Alonso A. Efectos adversos de bifosfonatos. *Reumatol Clin.* 2011;07:189-97.
- Jaimes M, Chaves Netto HD, Olate S, Chaves MMGA, Barbosa AJR. Bifosfonatos y osteonecrosis de los maxilares. Consideraciones sobre su tratamiento. *Int J Morphol.* 2008;26(3):681-8.
- González-Macías J, del Pino-Montes J, Olmos JM, Nogués X. Guías de práctica clínica en la osteoporosis posmenopáusica, glucocorticoidea y del varón. Sociedad Española de Investigación Ósea y del Metabolismo Mineral. (3ª versión actualizada 2014). *Rev Clin Esp.* 2015;215:515-26.