

**BILATERAL OBSTRUCTIVE UROPATHY AS  
CLINICAL PRESENTATION OF PRIMARY  
BLADDER LYMPHOMA**

David Hernandez Alcaraz, Jose A Gomez Pascual,  
Jorge Soler Martinez, Raul Vozmediano Chicharro,  
Pedro Morales Jimenez, Eloy Vivas Vargas and Victor  
Baena Gonzalez.

Urology Department. University Regional Carlos Haya  
Hospital. Malaga. Spain.

**Summary.-** *OBJECTIVE:* We report the event of an atypical presentation of primary bladder lymphoma, treated in our hospital, and review the literature of such tumors, representing 0,2% of bladder tumors, being macroscopic hematuria with clots the most frequent reason for patient consultation

*METHODS:* We report the case of an 83 years old man who went to the emergency room because of oligoanuria of 48 hours of evolution. He was diagnosed of bladder tumor.



## CORRESPONDENCE

David Hernández Alcaraz.  
Servicio de Urología  
Hospital Civil.  
Plaza de Hospital Civil s/n.  
29009 Málaga. (Spain).

davidhauro@hotmail.com

Accepted for publication: February, 27<sup>th</sup> 2009.

**RESULTS:** The pathology turned out to be a primary bladder lymphoma cell B.

**CONCLUSIONS:** Primary bladder lymphoma is a rare entity that presents a similar behaviour to other bladder tumors, having a good response to treatment with chemotherapy.

**Keywords:** Bladder tumor. Obstructive uropathy. Bladder lymphoma.

**Resumen.- OBJETIVO:** Dar a conocer un caso de presentación atípica de linfoma vesical primario tratado en nuestro hospital, así como revisar la bibliografía de este tipo de tumores, que representan el 0.2% de los tumores vesicales, siendo su forma de presentación más frecuente la hematuria macroscópica con coágulos.

**MÉTODOS:** Presentamos el caso de un varón de 83 años, que acudió a Urgencias por oligoanuria de 48h de evolución, en el que se diagnosticó un tumor vesical.

**RESULTADO:** La anatomía patológica resulto ser un linfoma vesical primario de células B.

**CONCLUSIONES:** El linfoma vesical primario es una entidad poco frecuente, que cursa de forma indistinguible a otros tumores vesicales, presentando una buena respuesta al tratamiento con quimioterapia.

**Palabras clave:** Tumor vesical. Uropatía obstructiva. Linfoma vesical.

## INTRODUCCIÓN

Lymphomas are tumors that originate in the lymph tissue located in lymph nodes and various organs of the body. Lymphomas can be primary, when first affect an organ, or secondary, if that is affected by extension of the primary.

Bladder primary lymphomas, originate from the mucosa associated lymphoid tissue.

## CASE REPORT

We report the case of a man, 83 years old, with hypertension, attending in the emergency department of our hospital because of oligoanuria and dysphoria 48 h of evolution. Previously he did not refer any urological symptom. We put him a urinary catheter without significant diuresis. He was done a blood test, where we objected creatinine of 10mg/dl and potassium around 6.9.

Abdominal ultrasound was performed by determining wall thickness at the trigone, and obstructive uropathy

bilateral dilated renal grade III / IV bilateral; after that, we realized a cystoscopy and attempted placement of a double J. In the examination of the bladder shows a large bladder mass, which rejects the side ureteral orifices, ureteral catheterization is impossible, so it is bilateral percutaneous nephrostomy.

Once we had the diagnosis and stabilized the patient, we did a transurethral resection of the bladder mass with a smooth postoperative.

The histopathology was reported as non-Hodgkin's B cell lymphoma diffuse large cell, with the markers CD45 +, CD20 +, CD79a +, CD10 +, CD3-, CD45RO-, BCL2, CD30, ALK-, + Vicentina, AE1-AE3 (Figure 1).

After the results obtained, extension study was performed with CT chest, abdominal and pelvic, determining only diffuse thickening of the bladder wall (Figure 2). This absence of disease in another location was what led to the diagnosis of primary bladder lymphoma.

After confirming the diagnosis of type, the patient began chemotherapy CHOP (cyclophosphamide, doxorubicin, vincristine and prednisone), obstructive uropathy disappearing as most relevant finding. The patient is currently disease-free after 14 months of follow-up.

## COMMENTS

The first description of these tumors was in 1985, and was conducted by Chaffey and Eve (1). Bladder lymphomas are responsible for 0,2% of primary bladder tumors and 1,8% of secondary (2).

They fall, from a clinical point of view, in primary (originating in the bladder) and secondary (lymphoma affecting the bladder in the process of spreading multiple organs).

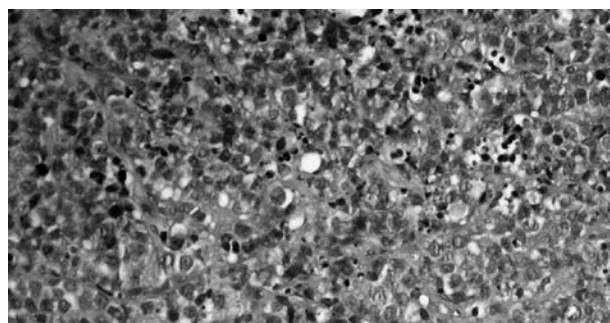


FIGURE 1. Lymphocytic infiltrate (pathological results).

Primarily affect Caucasian women over 60 years old with a 3:1 ratio over men. May be associated in 50% of cases to chronic cystitis (3).

The presentation form and radiological features are indistinguishable from urothelial bladder tumors, and for diagnosis are necessary histopathological samples, immunohistochemical techniques and molecular biology (4). In 77% of cases, usually take the form of macroscopic hematuria of varying intensity, associated with frequency and dysuria. Primary bladder lymphoma in the form of obstructive uropathy is rare, it usually does not affect the ureteral orifices (5). In secondary bladder lymphoma, this presentation is more common (17.2%); it happens in advanced stages of the disease and may occur by extrinsic compression of the urinary tract when they are located at the trigone, or localized adenopathy at the lower pelvis (6).

The macroscopic appearance of this entity shows solid submucosal masses, multinodulares rarely ulcerated. The histology is most commonly described as diffuse large cell and small lymphocytic, consistent with immunohistochemistry with lineage B.

Surgical treatment is justified only for greater security in the histologic diagnosis. Because the tumor is very sensitive to chemotherapy and radiotherapy, external radiotherapy would be indicated in the organ confined and localized tumors, alone or adjuvant to not aggressive surgery, although clinical remission is achieved only with poly-chemotherapy treatment (6,7). It is currently used type of CHOP chemotherapy (cyclophosphamide, doxorubicin, vincristine and prednisone), with antibodies antiCD20 (4).

The prognosis of primary bladder lymphoma is better than that of the secondary in general, as are organ confined. Survival was 50% at 5 years (4,6).

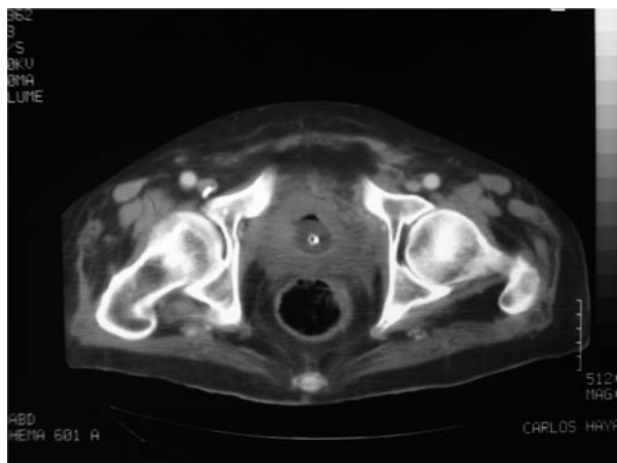


FIGURE 2. Bladder wall thickening.

## CONCLUSIONS

Primary bladder lymphoma is a rare entity that presents a way indistinguishable from other bladder tumors. It tends to have a very good response to chemotherapy. The prognosis is generally good, compared to disseminated forms of the disease.

## BIBLIOGRAFÍA y LECTURAS RECOMENDADAS (\*lectura de interés y \*\*lectura fundamental)

- \*\*1. Khaitan A, Gupta NP, Goel A, et al. Primary non-Hodgkin's lymphoma of urinary bladder. Report of a case and review of the literature. *Urol Int*, 2004; 72:82-84.
2. Antunes AA, Nesrallah LJ, Srougi M. Non-Hodgkin lymphoma of the bladder. *Int Braz J Urol*, 2004; 30: 6.
- \*\*3. Jaudah Al-Maghrabi, MD, Suzanne Kamel-Reid PhD, Michael Jewett MD, et al. Primary low-grade B-Cell lymphoma of mucosa-associated lymphoid tissue type arising in the urinary bladder. *Archives of Pathology and Laboratory Medicine*, 2001; 125: 332-336.
- \*4. Álvarez Álvarez C, Vieites Pérez-Quintela B, Pesqueira Santiago D, et al. Linfoma no Hodgkin B de célula grande primario de vejiga. *Actas Urol Esp*, 2005; 29 (9): 902-904.
5. Sharma A, Singh AB. Primary lymphoma of urinary bladder: report of an unusual case and literature review. *The Internet Journal of Urology*, 2002; 1: 1.
- \*6. García Ligeró J, Navas Pastor J, García García A, et al. Tumor transicional intraureteroceles sincrónico a tumor ureteral contralateral: uropatía obstructiva en enfermedad panurotelial. *Arch. Esp. Urol.*, 2002; 55, 4 :443-446.
- \*7. Martín Laborda y Bergasa F, Lozano Lozano D, Gil Fernández JJ, et al. Linfoma no Hodgkin y aparato urinario. A propósito de un caso. *Actas Urol Esp*, 2005; 29 (4): 427-432.
- \*\*8. Manoj Monga MD, Lamia L, Gabal-Shehab MD, et al. Primary lymphoma of the bladder. *Infect Urol*, 2000; 13(3):82-84.