

SPERMATIC CORD SARCOMAS: CURRENT STATUS AND REPORT OF FOUR CASES

Pedro Carrión Lopez, Hector Pastor Navarro, Jesus Martinez Ruiz, Jose Miguel Gimenez Bachs, Maria Jose Donate Moreno, Lorenzo Polo Ruiz, Jose Maria Pastor Guzman, Carlos Martinez Sanchiz, Rafael Ruiz Mondejar and Julio Antonio Virseda Rodriguez.

Department of Urology. Complejo Hospitalario Universitario de Albacete. Albacete. Spain.

Summary.- *OBJECTIVE: To study and review spermatic cord sarcomas, including symptoms, diagnosis, and treatment.*

METHODS/RESULTS: We review the Spanish and international literature and report 4 new cases: 2 patients with well-differentiated spermatic cord liposarcomas (1 treated by simple tumorectomy), 1 patient with liposarcomatous degeneration of a previously excised atypical lipoma, and 1 patient operated for a malignant retroperitoneal fibrous histiocytoma with subsequent local recurrence in the paratesticular region.



CORRESPONDENCE

Pedro Carrión López
Apartado de Correos 993
02080 Albacete. (Spain).

pedrocarrion1980@hotmail.com

Accepted for publication: February 29th, 2009.

CONCLUSIONS: Spermatic cord sarcomas are rare entities that usually appear as painless paratesticular mass. They are diagnosed by imaging studies (ultrasound, computed tomography, magnetic resonance) and confirmed by histological examination. Spermatic cord sarcomas are treated surgically; the efficacy of adjuvant treatments such as chemotherapy or radiation therapy is still under debate.

Keywords: Sarcoma. Paratesticular. Spermatic cord.

Resumen.- **OBJETIVO:** Estudio y revisión de los sarcomas de cordón espermático, de la clínica, diagnóstico y tratamiento de dicha patología.

MÉTODOS/ RESULTADOS: Se revisa la literatura nacional e internacional, aportando cuatro nuevos casos: dos liposarcomas de cordón espermático bien diferenciados, uno de ellos tratado mediante tumorectomía simple; un paciente con degeneración liposarcomatoide de un lipoma atípico previo resecado; y otro paciente intervenido de un fibrohistiocitoma maligno retroperitoneal con posterior recidiva local a nivel de la región paratesticular.

CONCLUSIONES: Los sarcomas de cordón espermático son una entidad poco frecuente que habitualmente se manifiestan como una masa paratesticular indolente. Su diagnóstico se efectúa mediante métodos de imagen (ecografía, TAC, RNM) y se confirma mediante el estudio histológico. El tratamiento es quirúrgico, existiendo cierta controversia acerca de la eficacia de tratamientos adyuvantes como la quimioterapia o la radioterapia.

Palabras clave: Sarcoma. Paratesticular. Cordón espermático.

INTRODUCTION

The paratesticular region is a complex anatomical area that includes the seminiferous tubules, efferent ducts, epididymis, deferens ducts, testicular tunica, and spermatic cord. However, the scrotal skin is not considered an anatomical structure of the paratesticular region.

Primary tumors that develop in this region, classified under the umbrella of paratesticular tumors, are a rare condition. Around 70% of these cases are benign and 30% are malignant (1). Lipoma is the most common benign paratesticular tumor whereas rhabdomyosarcoma (mainly in its juvenile form) is the most common malignant tumor, followed by leiomyosarcoma, liposarcoma, malignant fibrous histiocytoma, and fibrosarcoma.

MATERIALS AND METHODS

We reviewed the Spanish and international literature and present 4 new cases of spermatic cord sarcomas diagnosed and treated at our hospital, describing the clinical symptoms and diagnosis and discussing the treatment of choice.

PATIENT 1

A 38 year-old man with no urological history of interest came to the outpatient clinic for a slow-growing, progressive, painless left scrotal mass that had developed over 7 months (Figure 1). The physical examination revealed a soft 3-cm mass that was painless on palpation and not adherent to adjacent structures. Transillumination was negative, the testes were normal, and testicular tumor markers were negative. Sonography showed a homogeneous paratesticular lesion with regular borders that measured about 2 cm; lipoma was suspected.

Because the diagnosis was unclear, a surgical examination was undertaken, revealing a lipoma in the spermatic cord of approximately 2 x 1.5 cm, soft, yellow and easily excised. Because paratesticular lipoma was suspected, a left inguinal excision of the mass was performed, separating it from the spermatic cord. The pathology report indicated a well-differentiated liposarcoma (LPS) of the lipoma-like subtype.

Orchiectomy was ruled out because the tumor was small and its low-grade staging was associated with a good prognosis.

At the time of writing, the patient is asymptomatic and has no evidence of tumor recurrence 26 months after surgery.

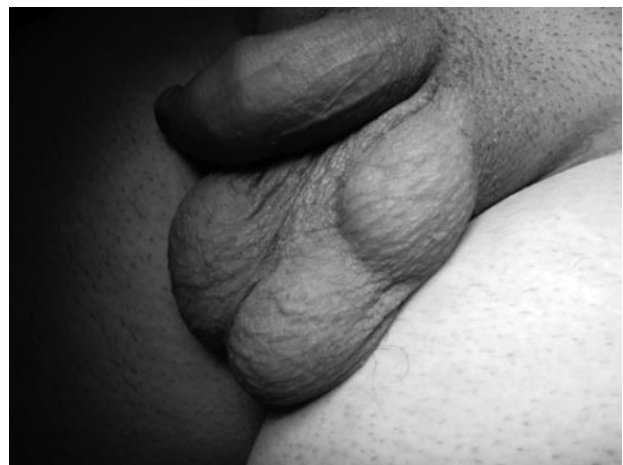

FIGURE 1.

PATIENT 2

In 2000, a 66-year-old man underwent surgery to excise a right paratesticular mass of 6 cm with a pathological diagnosis of atypical lipoma. The patient came to our outpatient clinic 6 years later for a palpable inguinoscrotal mass. The testicular ultrasound showed a solid, homogeneous, vascularized paratesticular mass of 5 cm with well-defined borders (Figure 2). The testicular tumor markers, extended computed tomography (CT) scan, and bone scintigraphy were negative.

Surgical examination through an inguinal incision revealed a heterogeneous mass firmly adhered to the spermatic cord and, therefore, the lesion was excised by right inguinal orchiectomy with high ligation of the spermatic cord.

The histological study showed a pleomorphic LPS of spermatic cord with no involvement of the surgical borders or testis.

Chemotherapy was not prescribed because there was no postsurgical residual disease.

Adjuvant radiation therapy was applied to the tumor bed due to the recurrent nature of the lesion and the high histological grade of the LPS subtype.

One year after surgery, the patient was asymptomatic and no evidence of tumor recurrence had been observed.

PATIENT 3

An 18 year-old man with no urological history of interest came to the outpatient clinic for a large, asymptomatic right inguinoscrotal mass that had developed over

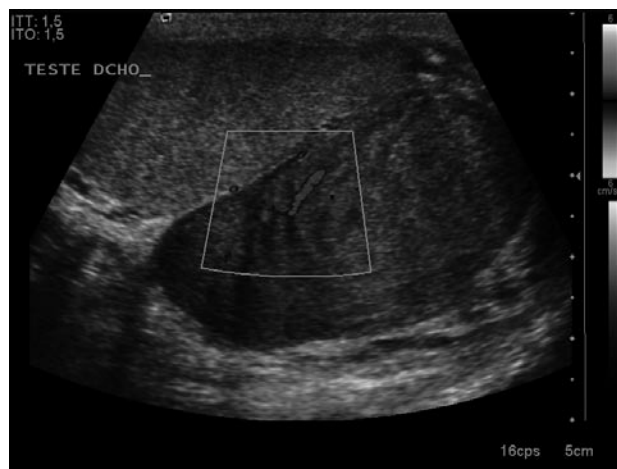

FIGURE 2.

1 year. The physical examination revealed a firm mass of about 15 cm that was painless on palpation; transillumination was negative and the mass moved medially toward the right testicle. The testicular tumor markers (alpha fetoprotein, beta-human chorionic gonadotropin, and lactate dehydrogenase) were negative.

The ultrasound study showed a solid, heterogenous lesion of 19 x 17 cm in the spermatic cord region that did not appear to infiltrate the testis. The pelvic magnetic resonance imaging (MRI) showed a right scrotal lipomatosis that displaced the testes; the testes were otherwise normal. The thoracic, abdominal, and pelvic CT did not reveal any pulmonary metastases or enlarged lymph nodes in the retroperitoneum or elsewhere.

An extensive right inguinal incision was made, excising a large, yellowish mass attached to the spermatic cord that displaced the testis, but without infiltration (Figure 3). The surgery was completed with right inguinal orchiectomy with high ligation of the spermatic cord. The histological study showed a well-differentiated LPS of the spermatic cord.

The need for chemotherapy or adjuvant radiation therapy was ruled out after assessment by the Oncology and Radiotherapy Department because the tumor was low-grade and the area to be treated was large, in view of the patient's age.

At the time of writing, 10 months after surgery, there was no indication of tumor recurrence.

PATIENT 4

A 59-year-old man was diagnosed with a retroperitoneal mass following a constitutional syndrome study in 2004.

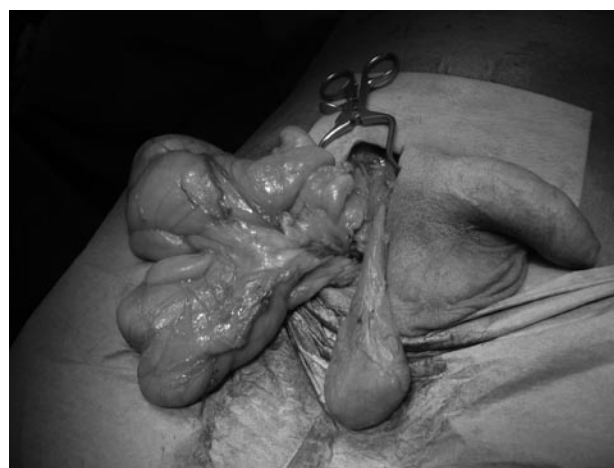


FIGURE 3.

A mass measuring 16 x 13 cm at the right iliac fossa was excised; the mass had displaced the bladder and was extensively adherent to the parietal peritoneum. The pathology study diagnosed the tumor as a high-grade sarcoma consisting of pleomorphic malignant fibrous histiocytoma (stage III-B). Adjuvant radiation therapy was administered.

Two years after surgery, the patient presented progressive worsening of his overall health and an extremely painful right inguinoscrotal mass. A testicular ultrasound showed a 7-cm oval hypoechoic structure on the cranial side of the right testis that ascended up through the inguinal canal and showed some septae. The structure shows some septae and appeared to be a cyst. The CT scan showed a lesion with similar characteristics to those reported in the ultrasound (Figure 4).

Because tumor recurrence in the spermatic cord was suspected, right inguinal orchiectomy was performed and the cystic mass was excised; necrotic areas and infiltration of the adjacent fat were also observed (Figure 5).

The histological examination revealed a mass measuring 12 x 8 cm and consisting of fusiform cells and abundant pleomorphic cells with no testicular or epididymis involvement. The diagnosis was pleomorphic malignant fibrous histiocytoma that extended up to the immediate vicinity of the surgical margin at some points; therefore, postoperative radiation therapy was administered.

Six months following excision of paratesticular mass and with recent completion of radiation therapy, the patient presented intra-abdominal recurrence. At the time of writing, he was receiving chemotherapy consisting of epirubicin and ifosfamide.

DISCUSSION

The first case of spermatic cord sarcoma was reported by Lesauvage in 1845.(2) Primary paratesticular tumors

can be grouped according to location in the testicular tunica, epididymis, or spermatic cord.

Spermatic cord tumors are the most common, comprising approximately 75% of tumors; 90% of these are of mesodermal origin.(2) The most common neoplasms are benign (70%) and most of these are lipomas (3). Because the spermatic cord originates in the mesoderm layer of the embryo (Wolffian duct), however, most malignant tumors are sarcomas and include rhabdomyosarcomas, leiomyosarcomas, liposarcomas, malignant fibrous histiocytoma, and fibrosarcomas.

Juvenile rhabdomyosarcoma accounts for approximately 40% of all malignant paratesticular tumors. Leiomyosarcoma and well-differentiated liposarcoma are the most frequent types in adults; malignant fibrous histiocytoma and fibrosarcomas are rare, between 10% and 5%, respectively (4).

The preoperative diagnosis between paratesticular and testicular masses is complex; however, it may sometimes be clinically clarified when a small mass in the cord is found independent of the testis. Nevertheless, larger paratesticular tumors are more difficult to diagnose by simple examination and should be verified by imaging studies such as ultrasound, CT scan, or MRI. These diagnostic methods will help to differentiate tumors that are attached to the testis from those that are not, particularly with regard to the tumor's histological type. Whereas benign tumors show a well-delimited, homogeneous, hypoechoic image in the ultrasound, malignant neoplasms in this region tend to appear as a solid, vascularized, hyperechoic, heterogeneous mass with necrotic areas and of variable size that tends to displace the testis. Because these tumors do not show a specific ultrasound pattern, the definitive diagnosis should be made after the histopathological results have been obtained, as occurred in our first and second case.

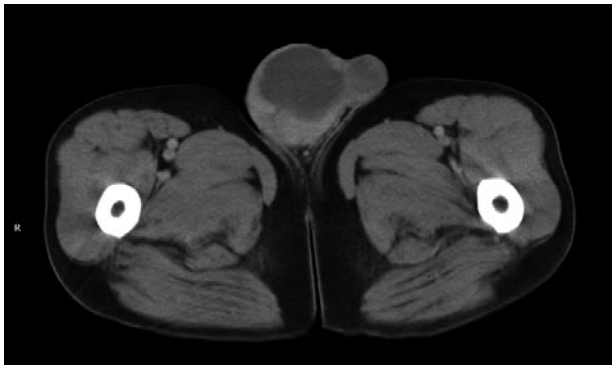


FIGURE 4.

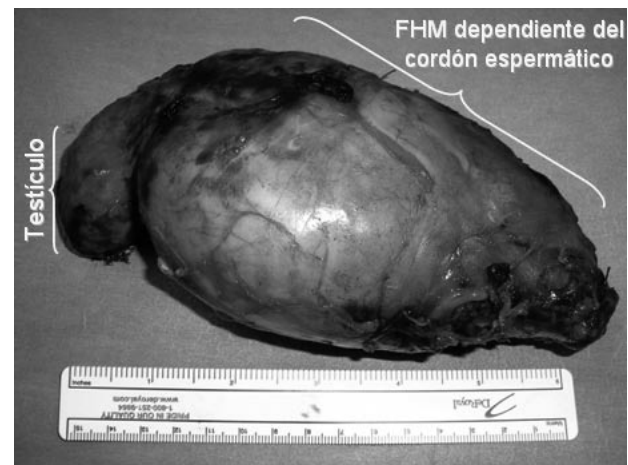


FIGURE 5.

Liposarcomas (LPS) are usually diagnosed between the fifth and sixth decade of life. Few publications report LPS development in the paratesticular region at age 18 as in our second case (9). LPS are slow-growing tumors and are classified into 4 groups: well-differentiated, myxoid, round-cell, or pleomorphic; the first 2 are low-grade and the most common in most published series (5,6). There is no agreement about LPS association with the degeneration of a previous lipoma, in fact, some publications agree with this association whereas others oppose it (7,8). In our second patient, it was unclear whether the previous lipoma had become malignant or if the "atypical lipoma" removed 6 years earlier was already a low-grade liposarcoma. A review of the specimen from the first lipoma showed some areas of well-differentiated LPS which indicated that the tumor was not degeneration, but rather clinical progression from a low-grade to a high-grade LPS.

Malignant fibrous histiocytoma (MFH) was initially described in 1964 by O'Brien and Stout (9) and from that time, has been considered the most common sarcoma in adults. MFH usually occurs in the legs and retroperitoneum; only 10% are malignant paratesticular tumors. In fact, this is the most unusual location. MFH tumors are characteristically grayish-white (Figure 5) and tend to be rather large and to infiltrate adjacent structures. Unlike other painless spermatic cord sarcomas, however, they manifest clinically as a very painful mass. Our fourth patient complained of severe pain in the right inguinoscrotal area that eased somewhat after surgery. The microscopic study was very typical, showing fusiform cells with a large nucleus, accompanied by histiocytic cells.

Surgery is widely considered to be the only possible curative treatment for all paratesticular tumors and consists of tumorectomy, along with radical orchiectomy using an inguinal approach on the affected side. Ligation of the spermatic cord should be as high as possible. Nevertheless, many publications report long, disease-free periods after simple tumor excision without orchiectomy, as occurred in our first case (10).

There are few therapeutic adjuvants to surgery. Chemotherapy for LPS has only proved to be beneficial in high-grade subtypes or metastatic disease (1). Single-agent and combination chemotherapy regimens have been used to treat MFH, but the results have not been satisfactory (11). In contrast, rhabdomyosarcomas are the only paratesticular sarcomas that have shown improvement in all stages with systemic polychemotherapy based on vincristine, dactinomycin, and cyclophosphamide. According to the Intergroup Rhabdomyosarcoma Study, rhabdomyosarcomas are also the only sarcomas in which unilateral retroperitoneal lymphadenectomy in stages II, III, and IV is recommended (12). Finally, neither leiomyosarcomas nor fibrosarcomas have shown significant improvement after chemotherapy.

Only adjuvant locoregional radiation therapy has shown

some efficacy in treating high-grade rhabdomyosarcoma tumors with surgical margin involvement in histological examination or in cases of local recurrence.

CONCLUSIONS

Spermatic cord sarcoma is a rare entity that usually develops as a slow-growing paratesticular mass. Imaging studies (eg, ultrasound, CT scan, or MRI) are required for diagnosis, and the curative treatment of choice is surgery. Adjuvant treatments, such as chemotherapy or radiation therapy, have shown little efficacy, except in the specific situations described above.

REFERENCES AND RECOMENDED READINGS

(*of special interest, **of outstanding interest)

- **1. Müller Arteaga C, Egea Camacho J, Álvarez Gago T, et al. Liposarcoma de cordón espermático. Asociación con carcinoma de próstata. *Actas Urol Esp* 2005; 29 (7): 700-703.
2. Hinman F, Gibson TE. Tumors of the epididymis, spermatic cord and testicular tunics: a review of literature and report of three cases. *Arch Surg*, 1924; 8: 100.
3. Rodríguez LA, Estébanez J, Camacho J, Alonso D, Del Río F, De Castro C, Martínez Sagarra JM. Lipoma paratesticular. *Actas Urol Esp*. 1997; 21: 620-622.
- *4. Soosay GN, Parkinson MC, Paradinas J. Paratesticular sarcomas revisited. A review of cases in the British Testicular Tumour Panel and Registry. *Br J Urol* 1996; 77: 143-6.
5. Ozkara H, Ozkan B, Alici B, et al. Recurrent paratesticular mixoid liposarcoma in a young man. *J Urol*. 2004; 171: 343.
- *6. Gimeno Aránguez M, Escribano Patiño G, Hernández Fernández C, Álvarez Fernández E. Liposarcomas Paratesticulares. Estudio clínico patológico de tres casos y revisión de la literatura. *Arch. Esp. Urol*. 2006; 59:875-881.
- *7. Peyrí Rey E, Urban Ramón A, Martínez Fernández M, Samarti Da Silva B. Liposarcoma dediferenciado del cordón espermático: degeneración de un lipoma previo resecado. *Actas Urol esp*, 2003; 27:383-386.
- *8. Domínguez F, Riera JR, Junco P, et al. Liposarcoma bien diferenciado de cordón espermático con desdiferenciación. *Arch Esp Urol* 1994; 47: 717-720.
- *9. O'Brien JE, Stout AP. Malignant fibrous xanthomas. *Cancer* 1964; 17: 1.445.
- **10. Roberto I. Lopes, Katia R. Leite y Roberto N. Lopes. Paratesticular leiomyosarcoma treated by enucleation. *Int. Braz J Urol*. 2006; 32: 66-67.
11. Gimeno Argente V, Bosquet Sanz M, Gómez Pérez L, et al. Histiocitoma fibroso maligno retroperitoneal con infiltración de órganos vecinos. *Actas Urol Esp*. 2007; 31:562-566.
12. Mora Nadal JI, Ponce Campuzano A, Llopis Manzanera J, et al. Rbdomiosarcoma paratesticular. *Actas Urol Esp*. 2004; 28: 245-248.