

**IMAGES IN UROLOGY**

Arch. Esp. Urol. 2009; 62 (4): 325-326

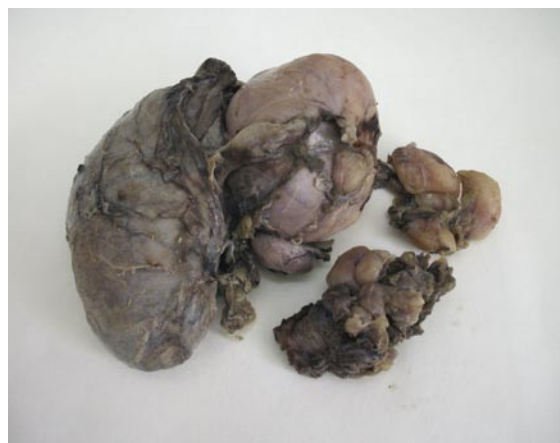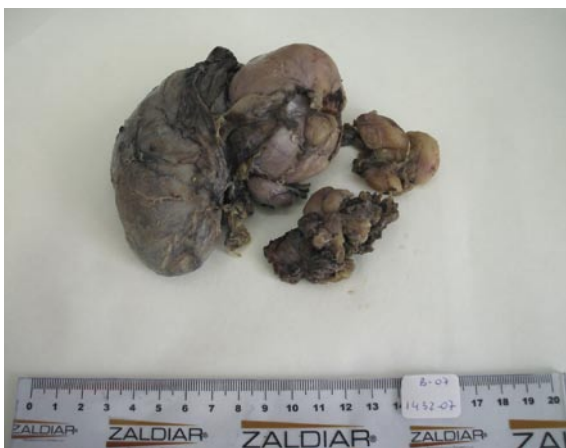**"ATYPICAL LIPOMATOUS TUMOR OF THE PARATESTICULAR STRUCTURES."***Francisco Javier Torres Gómez, Pilar Fernández Machín and Juan Manuel Poyato Galán.**Pathologic Anatomy and Urology Unit<sup>1</sup>. Hospital de Alta Resolución de Utrera. Sevilla. Spain.*

**S**oft tissue tumors are relatively uncommon in the testis and paratestis. Lipomas and leiomyomas are the most frequently reported tumors but cases of most of the soft tissue tumors have been described in this localization.

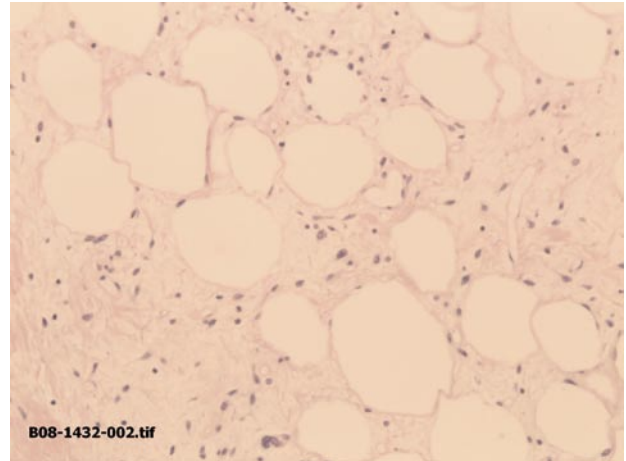
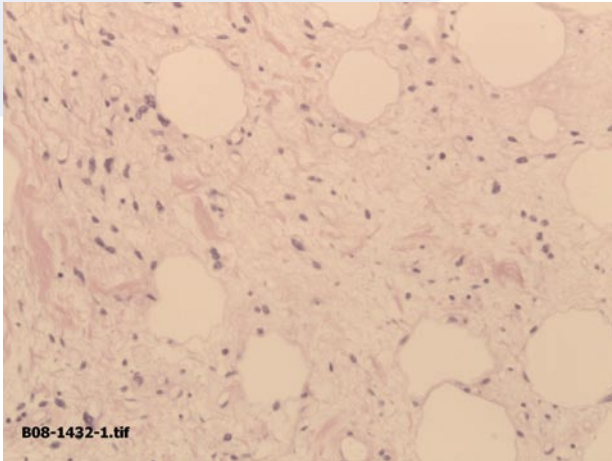
Diagnosis of atypical lipomatous tumor / well differentiated liposarcoma is infrequent and shows the neoplastic nature of the lesion against theories that consider them regional adipose tissue

hyperplasias. Diagnosis of atypical lipomatous tumors is simple from an histological point of view using the same criteria that are used in other locations.

Clinical, surgical and radiological diagnoses are inespecific. We consider showing images of atypical lipomatous tumor of paratestis is of interest. Terms like atypical lipomatous tumor and well differentiated liposarcoma are used indistin-



FIGURES 1 and 2. Atypical lipomatous tumor. Macroscopic images.



FIGURES 3 and 4. Atypical lipomatous tumor. Histologic view HE. 20x.

cly but both of them are sometimes associated to specific locations. Well differentiated liposarcoma is the term used in the literature for this localization.

It is a lipomatous tumor with atypical cells and/or lipoblasts. According the morphology atypical lipomatous tumors are divided in: lipoma-like, sclerosing and inflammatory.

The case we report has a mixed morphology between the lipoma-like and sclerosing types. There were no lipoblasts (a common feature in paratesticular structures).

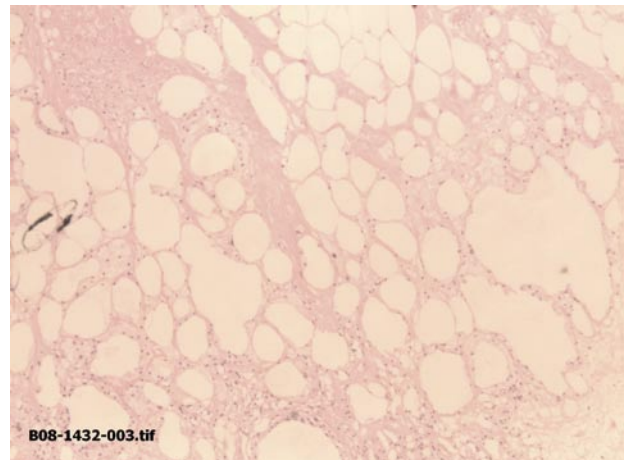


FIGURA 5. Atypical lipomatous tumor. Histologic view HE. 10x

#### CORRESPONDENCE



Francisco Javier Torres Gómez  
Unidad de Anatomía Patológica  
Hospital de Alta Resolución de Utrera  
Sevilla. (Spain).

javiertorresgomez@yahoo.es