

Letters to the Editor

Foreign body-induced acute pancreatitis: Ultrasonographic diagnosis

Key words: Acute pancreatitis. Foreign body. Abdominal ultrasound.

Dear Editor,

In the Western world, acute pancreatitis is estimated to be associated with gallstones or alcohol consumption in around 85 % of the cases. Among the remaining possible causes, foreign bodies are believed to be one of the rarest, with around twenty cases reported in the medical literature (1-5).

Case report

A 76-year-old woman, with no history of alcohol consumption, presented to the emergency department with nausea, alimentary vomits, and intense abdominal pain, located in the epigastrium and radiating to the back, with around 12 h of evolution. The physical examination revealed abdominal tenderness in the epigastric region. Blood tests showed leucocytosis and elevated amylase (1,193 U/L) and lipase (16,900 U/L). Triglycerides and calcium were within normal values. A CT scan demonstrated enlargement of the pancreatic head, and no evidence of gallstones, also confirmed by abdominal ultrasound. The patient was diagnosed with alithiasic acute pancreatitis and admitted to our department. Within 48 h there was substantial clinical improvement. Before the hospital discharge, a follow-up abdominal ultra-

sound was performed. It detected an hyperechogenic thin linear foreign body, measuring 3 cm in length, lodged between the posterior wall of the gastric antrum and the head of the pancreas (Fig. 1A). The finding was confirmed by endoscopic ultrasound (Fig. 1B). An upper GI endoscopy was performed and revealed an edematous area in the posterior wall of the gastric antrum, with a central depression, which was assumed to be the entry

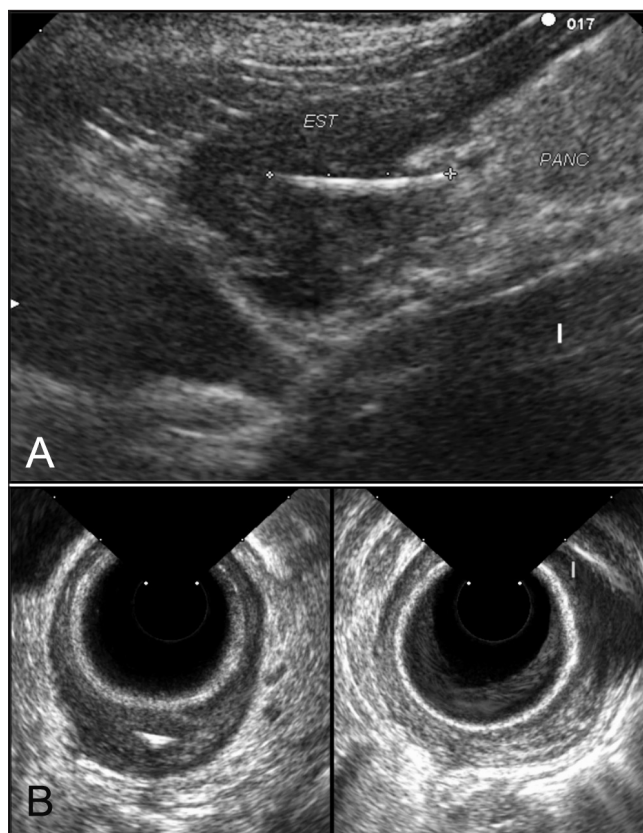


Fig. 1. A. Abdominal ultrasound: Linear foreign body extending between the gastric antrum wall and the pancreatic head. B. Endoscopic ultrasound: Transversal and longitudinal view of the foreign body.

point of the detected foreign body into the gastric wall. The case was discussed with a surgeon, but taking into account the quick clinical improvement and the patient's refusal to undergo an eventual surgery, an expectant attitude was adopted. An abdominal ultrasound was repeated 6 months later. The foreign body had receded and was located inside the gastric wall, with no contact with nearby structures. There was no symptomatic recurrence.

Discussion

Foreign body-induced acute pancreatitis is a rare entity. Most reported cases are due to foreign body impaction of the ampulla of Vater, causing secondary obstruction (1,2). The transgastric route is particularly uncommon. In the presented case the foreign body is probably a fishbone, considering a history of frequent fish consumption. The ingestion is frequently unperceived. If possible, extraction of the foreign body should be pursued in order to minimize the risk of recurrent pancreatitis or migration causing eventual damage to other structures. In this particular case the patient refused surgery.

Bruno Pereira, Antonieta Santos, Eduardo Pereira and
António Bahudo

*Department of Gastroenterology. Hospital Amato Lusitano.
Castelo Branco, Portugal*

References

1. Meltzer SJ, Goldberg MD. Recurrent pancreatitis caused by vegetable matter obstruction. *Am J Gastroenterol* 1986;81:1091-2.
2. Perney P, David XR, Gislon J, Abitbol N, Larrey D, Michel H. Acute pancreatitis caused by foreign bodies: 2 cases. *Presse Med* 1993;22:1397-404.
3. Chiu YH, How CK, Chen JD. Fish bone-induced pancreatitis. *Clin Gastroenterol Hepatol* 2010;8:e27.
4. Kim K, Woo E, Rosato E, Kochman M. Pancreatic foreign body: Ingested toothpick as a cause of pancreatitis and hemorrhage. *Gastrointestinal Endoscopy* 2004;59:147-50.
5. Rezgui-Marhouf L, Said W, Askri A, Douira W, Dali N, Dridi L, et al. Acute pancreatitis due to a metallic foreign body. *Gastroenterol Clin Biol* 2004;28:299-300.