

## PICTURES IN DIGESTIVE PATHOLOGY

# Isolated pediatric duodenal rupture after horse hoof kick

Roberto Méndez-Gallart, Elina Estévez-Martínez, Pablo Rodríguez-Barca, María García-Palacios and Adolfo Bautista-Casasnovas

*Department of Pediatric Surgery. Hospital Clínico Universitario de Santiago. Santiago de Compostela, A Coruña, Spain*

### CASE REPORT

An 8 year-old-boy was referred because of abdominal pain 24 hours after being hoof-kicked by a horse in the abdominal wall. On arrival the boy appeared ill, with nausea and vomiting and right abdominal pain. Physical examination revealed epigastric tenderness with muscle guarding in the upper abdominal wall. Because of persistent pain CT was performed and further revealed a very small amount of free subhepatic air just attached to the duodenum (Fig. 1). A hollow viscus injury was suspected. At surgery there was bile staining and dirty fluid in the paraduodenal area. A duodenal perforation (1 cm) located in the retroperitoneal segment was noticed (Fig. 2). A primary surgical repair of the duodenal rupture was made. The patient's postoperative course was uneventful and was discharged at home seven days later.

### DISCUSSION

Isolated perforation of the duodenum is an extremely infrequent lesion as a result of horse-related blunt abdominal trauma in children (1). Less than ten pediatric cases could be accounted. Vast majority of patients with duodenal injuries have other concomitant intra-abdominal lesions (2,3). This entity is very difficult to diagnose and may be delayed especially when the retroperitoneal part is affected due to its subtle clinical characteristics resulting in significant morbidity and mortality.

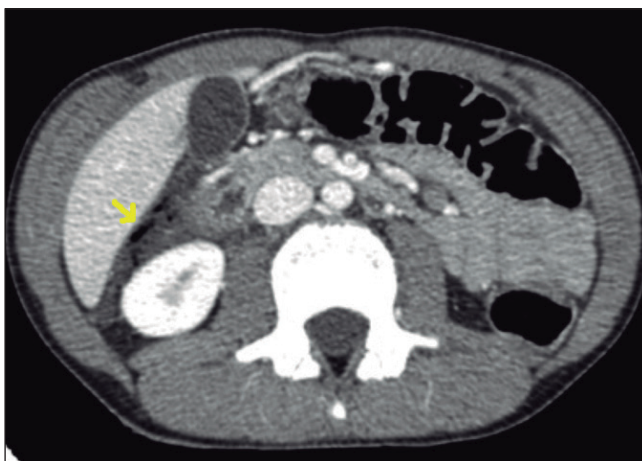

Fig. 1. Axial computed enhanced tomography scan of abdomen showing a small amount of free air bubbles (arrow) on the perihepatic and right anterior pararenal space adjacent to the retroperitoneal portion of the duodenum.

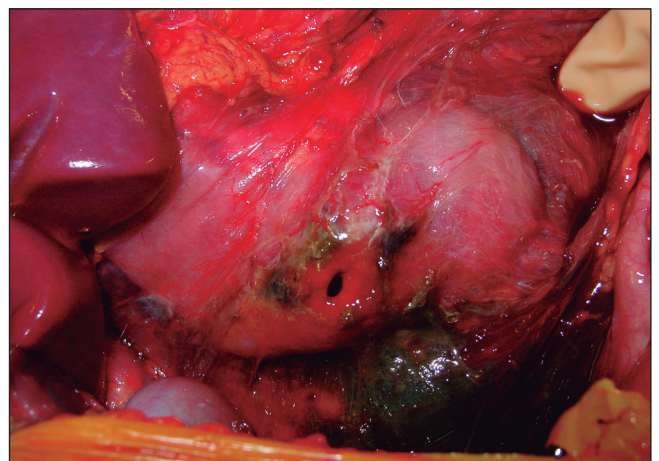


Fig. 2. Intraoperative picture showing the traumatic perforation on first part of duodenum after extensive Kocher maneuver. An extensive bilious staining and pus flakes all around in the paraduodenal area could be seen.

Conservative management of blunt abdominal pediatric trauma may jeopardize the early recognition of duodenal injuries (2-4). Clinical findings may be notoriously subtle before the life-threatening, peritonitis appears (3). Abdominal CT scan is very sensitive to the presence of small bubbles of retroperitoneal air from the injured duodenum. Most of the isolated duodenal perforations are adequately managed with primary closure (5). The most important factor for successful outcome of primary repair seems to be the time to surgery. A delay in diagnosis for longer than 24 hours results in a thickened, friable and inflamed duodenal wall that may lead to catastrophic consequences (3,5).

## REFERENCES

1. Cuenca AG, Wiggins A, Chen MK, Kays DW, Islam S, Beierle EA. Equestrian injuries in children. *J Pediatr Surg* 2009;44:148-50.
2. Clendenon JN, Meyers RL, Nance ML, Scaife ER. Management of duodenal injuries in children. *J Pediatr Surg* 2004;39:964-8.
3. Fang JF, Chen RJ, Lin BC. Surgical treatment and outcome after delayed diagnosis of blunt duodenal injury. *Eur J Surg* 1999;165:133-9.
4. Furukawa A, Sakoda M, Yamasaki M, Kono N, Tanaka T, Nitta N, et al. Gastrointestinal tract perforation: CT diagnosis of presence, site, and cause. *Abdom Imaging* 2005;30:524-34.
5. Bozkurt B, Ozdemir BA, Kocer B, Unal B, Dolapci M, Cengiz O. Operative approach in traumatic injuries of the duodenum. *Acta Chir Belg* 2006;106:405-8.